

DROPPED NUCLEUS DURING PHACOEMULSIFICATION; OUTCOMES

ORIGINAL
PROF-1737

DR. FAHEEM AHMAD

MBBS, MCPS, FCPS
Assistant Professor
Independent Medical College
Faisalabad.

DR. SYED ALI HAIDER

MBBS, FRCS
Professor of Ophthalmology
LGH/PGMI, Lahore

ABSTRACT: Introduction: The increasing popularity of phacoemulsification in restoring good visual acuity has also led to an increase in the incidence of its complications like nucleus drop during the procedure. Proper management of such patients not only reduces intravitreal lens fragments related complications but also significantly improves the visual acuity. **Objectives:** To evaluate the clinical features of the eye with retained Intravitreal lens fragments after the phacoemulsification surgery. We also aimed to investigate the incidence of cystoid macular edema, retinal detachment, suprachoroidal hemorrhage and any other complication in patients after pars plana vitrectomy for retained intravitreal lens fragments. **Setting:** This study was carried out at the department of ophthalmology, Lahore General Hospital, Lahore. **Period:** The duration of study was one year 17-05-2004 to 28-04-2005. **Study Design:** Descriptive prospective. **Material & Methods:** The reported frequency of dislocated lens material at 0.3% is quite low. Despite LGH being a referral center for retinal diseases, dropped nuclei and nuclear fragments constitute a very small fraction of the referred cases. Therefore the study was limited to 15 cases only so that it could be completed within specified period. **Results:** 15 eyes having retained lens matter after phacoemulsification surgery were included. Aphakia was present in 10(66.75%) patients. 5 (33.4%) patients were pseudophakic. Raised intraocular pressure was found in 11 (73.4%) patients, corneal edema in 7 (46.7%), uveitis in 6 (40%) patients. Two (13.4%) patients had retinal detachment at presentation. The range of visual acuity was perception and projection of light to counting fingers in 9 eyes (60%), 2/60-6/60 in 5 eyes (33.4%). 6/24 in 1 (6.64%) eye preoperatively. After vitrectomy, range of visual acuity was 6/9 to 6/18 in 9 patients (60%) and 6/24-6/60 in 6 patients (40%). The comparison of pre-operative visual acuity and that of last follow-up showed $p < 0.01$ (statistically highly significant). Intraocular pressure was raised in only 2 patients (13.3%). No patient developed retinal detachment. Cystoid macular edema was found in only 2 patients (13.4%). No patient developed significant intraocular inflammation after vitrectomy. **Conclusions:** Patients having retained intravitreal lens fragments presented with raised intraocular pressure, reduced visual acuity, uveitis and retinal detachment. In such patients combined pars plana vitrectomy and secondary intraocular lens implantation reduced the risk of postoperative complications including secondary glaucoma, uveitis and helped in restoration of useful visual acuity.

Key words: Phacoemulsification, Retained Intravitreal Lens Fragments, Vitrectomy

INTRODUCTION

There is no significant medical treatment for cataract. Surgery is the treatment of choice for cataract. Various forms of extracapsular surgery (ECCE) with lens implantation are the methods in vogue at the moment.

Phacoemulsification (phaco), a modification of ECCE, has found wide spread popularity in last decade. Phacoemulsification is generally carried out on immature cataract. After phacoemulsification intraocular lens (IOL) is implanted. Its advantage over ECCE is the relatively smaller incision that is required which leads to lower post-operative astigmatism and quicker rehabilitation time¹.

One of serious intraoperative complication of cataract extraction especially with phaco is dropped nuclei fragments or nucleus into vitreous after posterior capsule rupture. The causes may be inadequate experience in phaco surgery, sudden shallowing of anterior chamber, extension of anterior capsulorhexis, performing forceful

hydro-dissection or due to some mechanical problem with phacoemulsification machine. (The overall incidence of dropped nucleus or nuclear fragments is 0.3%. The incidence of dropped nucleus by experienced surgeons is 0.2% while that in the hands of inexperienced surgeons it is 0.6%²).

The clinical findings in these patients were decreased visual acuity to 6/60 or worse, severe to moderate corneal edema, raised intraocular pressure, pain, prolonged intraocular inflammation, retinal detachment (RD) and suprachoroidal hemorrhage³. Reported series with long-term follow-up have found that retinal detachment occurs in about 15% of eye with retained lens fragments. If the lens fragments are in the posterior vitreous aggressive attempts to retrieve them from limbal approach are sometimes complicated by giant retinal tear⁴.

Indirect ophthalmoscopy is very helpful in proper

detection of these nucleus fragments and detection of retinal detachment provided the media is clear. While in case of hazy media B-scan ultrasonography is of help to know the status of retina as well as to detect nuclear fragments or any kind of hemorrhage. The treatment of such patients is pars plana vitrectomy with removal of nuclear fragments or the nucleus with insertion of secondary IOL⁵.

Poor visual acuity, raised IOP, intraocular inflammation, retinal detachment and CME are major complications in non-vitrectomised eyes. However retinal detachment may occur in vitrectomised eyes in very low percentage of patients. The Pars plana vitrectomy (PPV) for retained intravitreal lens fragments yield faster visual rehabilitation and better quality of vision^{6,7}.

Early vitrectomy (fewer than three weeks) is associated with better visual results while late vitrectomy results in limited visual acuity in high percentage of patients as well as increased risk for glaucoma & retinal detachment⁸.

The major intra-operative complications may be retinal detachment, cystoid macular edema (CME), suprachoroidal hemorrhage, retinal breaks formation etc⁹.

Retinal detachment is a well recognized complication in eyes undergoing PPV for removal of retained lens fragments. Despite of favorable retinal reattachment results visual acuity is often poor in such patients. These cases also have high incidence of corneal edema, CME and poor visual acuity. Similarly presence of retinal tear at time of pars plana vitrectomy (PPV) was associated with higher rate of retinal detachment after PPV¹⁰.

Most of patients of early vitrectomy have good visual outcome (6/12 or better). The causes of poor visual acuity in such patients were cystoid macular edema, retinal detachment, age related maculopathy and myopic maculopathy¹¹.

PURPOSE OF STUDY

The aims of this study are:

1. To evaluate the clinical features of eye with

retained intravitreal lens fragments after phacoemulsification.

2. To investigate the incidence of cystoid macular edema, retinal detachment, suprachoroidal hemorrhage and any other complications in patients of Vitrectomy for retained intravitreal fragments.

MATERIAL AND METHODS

This study was carried out at the department of ophthalmology, Lahore General Hospital, Lahore. The reported frequency of dislocated lens material at 0.3% is quite low. Despite LGH being a referral center for retinal diseases, dropped nuclei and nuclear fragments constitute a very small fraction of the referred cases. Therefore the study was limited to 15 cases only so that it could be completed within specified period. Ocular examination included recording of visual acuity, applanation tonometry, assessment of corneal clarity and degree of uveitis, fundal examination, and an estimation of the amount and nature of the retained lens fragments. Intraocular pressure was considered raised when above 21 mm Hg and then regular anti-glaucoma medication was required. Corneal edema was considered significant when both stromal and epithelial edema were present and anterior uveitis was graded by the number of cells in the anterior chamber (1+ = minimum cells and 4+ = marked cells with hypopyon).

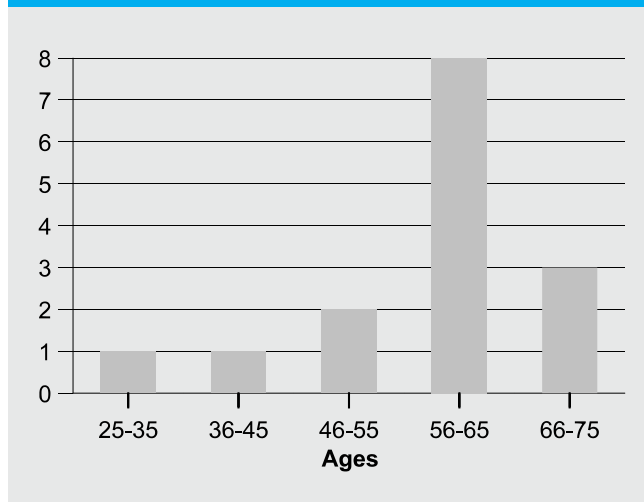
Vitrectomy was performed when there was persistent uveitis and/or raised intraocular pressure (IOP) or when the amount of intravitreal lens material was considered to be great enough to produce chronic inflammation. Removal of lens material was accomplished using a standard three port pars plana vitrectomy technique with either ultrasonic fragmentation or mechanical crushing of lens fragments by the using the illuminated probe against the vitreous cutter port.

The duration of study was one year from 17-05-2004 to 28-04-2005. Data was analyzed by SPSS, Version 10, qualitative data analysis with chi square & quantitative data analysis with student's T test.

RESULTS

Fifteen eyes having retained intravitreal lens fragments

Fig-1. Age wise distribution of patients



after phacoemulsification were entered in this study. The age range of patients was 28-75 years with mean 59.57 ± 2.95 years (Fig-1) Out of fifteen patients 7 (46.7%) were male and 8 (53.7%) were female (Fig-2).

The range of days between occurrence of complication and operative procedure was 1-60 days with mean 17.3 ± 5.9 days. 10 patients (66.67%) came and were operated in first week, 1 (6.7%) patient in second week, 1 (6.7%) patient in third week and 3 patients (20.01%) after the third week (Table I).

At initial examination pre-operative visual acuity was PL PR in 5 patients (3 hand movement in 1 patient (6.7%), CF in 3 patients (20%). 6/60-2/60 in 5 patients (33.4%) and 6/24 in 1 (6.7%) patient. The visual acuity at end of third month (last follow-up) was 6/9 in 3 patients (20%), 6/12 in 4 patients (26.7%), 6/18 in 2 patients (13.4%), 6/24 in 1 patient (6.7%), 6/36 in 4 patients (26.7%) and 6/60 in 1 (6.7%) patient. [$p=0.0006$, $p<0.01$ (statistically significant)] (Table II).

Eleven patients (73.4%) out of 15 had increased intraocular pressure before vitrectomy. The pre-operative Mean IOP was $27 \text{ mmHg} \pm 3.58$. After vitrectomy only 2 eyes (13.4%) had raised IOP that was controlled medically in one week. [$p=0.0004$, $p<0.01$ (statistically significant)] (Table III).

The pre-operative clinical features noted at time of

Fig-2. Sex wise distribution of patients

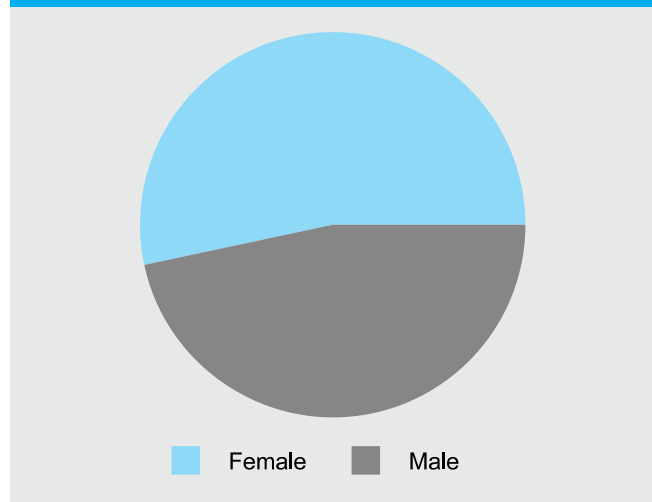


Table-I. Duration of patients having retained intravitreal lens fragments

Duration (Days)	No. of patients	%age
1-7	10	66.67
8-14	01	6.7
15-21	01	6.7
>21	03	20.0

referral are listed in table no 4. Regarding the posterior segment pre-operative findings nuclear fragments or whole nucleus was present in all cases while retinal detachment and CME was present in 2 (13.4%) patients each (Table-V).

In patients having retained intravitreal lens fragments, referring surgeons left 10 (66.75%) patients aphakic while 5(33.4%) were pseudophakic. Only PPV was done in 3 patients (20%), PPV & Heavy Liquid in 3 patients (20%), PPV, Silicon oil & secondary IOL in 2 patients (13.3%) and PPV, Heavy Liquids & secondary IOL in 7 patients (46.7%) (Fig,3).

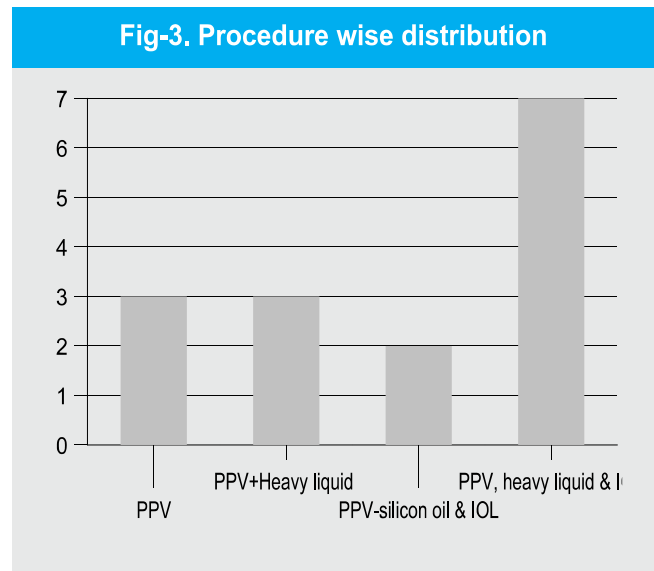
Regarding post-operative complications after vitrectomy the IOP was raised in 2 (13.3%) patients that were controlled medically in two weeks. Retinal detachment was not noted in any patient and CME was present in 2 (13.4%) patients. However it was not clear that whether it

Table-II. Visual acuity (operative eyes)					
VA	Pre-Op	1 st Day	1 st week	1 st month	3 rd month
6/9	-	2	2	3	3
6/12	-	-	-	1	4
6/18	-	2	2	2	2
6/24	1	1	3	3	1
6/36	-	7	5	4	4
6/60	1	2	3	2	1
5/60	1	-	-	-	-
4/60	1	-	-	-	-
2/60	2	-	-	-	-
CF	3	1	-	-	-
HM	1	-	-	-	-
PLPR	5	-	-	-	-

Table-III. Intra-ocular pressure (AT) in operative eyes					
IOP(AT) mmHG	Pre-OP	1 st day	1 st week	1 st month	3 rd month
1-10	3	3	2	3	5
11-20	2	10	14	12	10
21-30	5	1	-	-	-
31-40	3	1	-	-	-
>40	2	2	-	-	-

Table-IV. Clinical features before virectomy		
Clinical features	No. of cases	Comments
Poor visual acuity	14 (93.4%)	6/60 or more
Raised IOP	11 (73.4%)	21mmHg or more
Retinal detachment	2 (13.4%)	Retinal detachment or tear
Corneal edema	7 (46.7%)	Moderate to severe
Uveitis	6 (40%)	AC cells + 2 or more

Table-V. Pre & post operative complications (Operative eyes)					
Clinical findings	Pre-Op	1 st day	1 st week	1 st month	3 rd month
CME	-	2	2	1	-
Fragments & RD	13	-	-	-	-
NAD	-	12	13	14	15



was present pre-operatively or developed after PPV.

DISCUSSION

One of the basic human rights is the right to see. Cataract is responsible for blindness in more people than any other single ocular disease. Cataract is not preventable but is surgically curable. Quick rehabilitation following surgery is the aim of all surgeons. Day care surgery in ophthalmology was started in early 80's of last century. Small incision phaco is now a widely accepted and practiced all around the world because it has the potential for faster rehabilitation of the patient's visual acuity¹².

Dislocation of lens fragments into vitreous during phaco is an uncommon event. However, with wider use of technique this complication has been increasing in frequency¹³. The incidence of dislocation of lens fragments into vitreous during phaco is 0.3% in

accordance with previous reports. The major indications for PPV in this study were removal of the intravitreal lens material to prevent complications and treatment of secondary glaucoma. In our study 11 (73%) out of 15 patients had increased IOP before vitrectomy. After vitrectomy 9 (60%) cases show normal IOP while 2 (13.4%) cases had still raised IOP that was controlled medically in one week. Furthermore when comparison done statistically of pre-operative IOP and IOP of last follow-up it showed $p < 0.01$ [statistically highly significant] (table No IV). Some previous studies had found a low incidence of chronic glaucoma in cases of early vitrectomy¹⁴ whereas other authors did not found statistically any significant relation between the two¹⁵. A marked inflammatory response is commonly found in a complicated phacoemulsification procedure. Irvine et al reported 4 cases who developed endophthalmitis with hypopyon 1-12 months after phacoemulsification complicated by posteriorly dislocated lens fragments¹⁶. Similarly Kim et al published a report of five cases of coagulase negative staphylococcal endophthalmitis starting 5 days to 6 days after complicated phacoemulsification¹⁷. It can be a diagnostic dilemma to differentiate between infective endophthalmitis and lens related uveitis, however vitrectomy has been reported to produce good results.

In present study 6 (40%) cases had significant uveitis and 7 (46.36%) had corneal edema but all had good results after vitrectomy. Retinal detachment is an important factor for determining the outcome of these cases. Wevy et al attributed 26% incidence of post-vitrectomy retinal detachment in their series due to use of fragmatome before vitreous removal as well as the use of heavy liquids¹⁸. They also reported two retinal tears formed while pushing the nucleus against retina by fragmatome.

In our present study although 2 (13.4%) cases had pre-vitrectomy retinal detachment that needed a second procedure, no patient developed retinal detachment after PPV for lens fragments removal. Lewis et al found perfluorocarbons especially helpful in removing intravitreal lens material along with prevention of retinal detachment. In the present study, in 10 (66.7%) cases where perfluorocarbons liquids were used, no patient

developed retinal detachment¹⁹. An attempt was made to remove all vitreous with special attention to peripheral parts by employing scleral indentation. It was this technique, which explains the absence of new retinal detachment. Furthermore all cases were operated by a single vitreoretinal surgeon having fifteen years experience in vitreo-retinal surgery. A previous study has shown 1.4% incidence of retinal detachment after ECCE without any significant relation between retinal detachment and phaco. However this risk increases to 18% where there is associated vitreous loss²⁰.

Some authors have proposed that chasing lens material in vitreous by an irrigating fluid stream or non-cutting instruments are major risk factors for development of retinal detachment by inducing traction at vitreous base²¹. The over all incidence of retinal detachment in present study was 2 patients (13.4%) pre-operatively and no retinal detachment occurred post-operatively. Silicon oil was used in both cases to repair the retinal detachment. The incidence of CME is reported to be 1% after ECCE and it increased to 20% if complicated by vitreous loss and/or anterior vitrectomy. Kapsata et al found CME in 11.5% cases while Kim et al has found (his complication in 11% cases after PPV for complicated phaco²². In the present study only 2 (13.4%) cases developed CME that resolved with time.

The ideal timing of vitreous surgery for lens fragments removal is controversial. Present study has suggested that prognoses appear better if PPV is done within one week although a number of studies have found no correlation between visual outcome and timing of PPV. Previous studies however were retrospective and may be well biased by a tendency to operate early on eyes with greater volume of retained lens fragments, a more marked early inflammatory response or raised IOP at an early stage. It is notable that only one study found an increased incidence of retinal complications with early vitrectomy²³. In the present study it was observed that PPV done within one week showed better visual prognosis and decreased lens matter related complications as compared to cases that were operated after one week. In the present study 10 (66.75%) cases were operated within first week showed better postoperative visual acuity results as compared to 3

(20%) cases that came after third week.

The IOL implantation at the time of primary surgery is a relative contraindication. Fostenberg recommended leaving aphakia if there is intraoperative corneal edema or posterior dislocation of large and/or hard lens fragments posteriorly²⁴. Similarly, Wong et al strongly recommended against implantation if lens material dropped into vitreous as it may necessitate the use of fragmentation²⁵.

In the present study, IOL implantation was done by the referring surgeons in 5 (33.4%) cases in posterior chamber while remaining 10 (66.37%) cases were aphakic and posterior chamber IOL implantation was done at time of surgery. So we suggest that primary surgeon should insert PC IOL if certain about posterior capsular support and if there is only small amount of retained lens material.

Good visual acuity have been reported after PPV for retained intravitreal lens fragments²⁶. In this study patients had pre-operative visual acuity PLPR-6/60 in 13 patients (86.7%), 6/36 in 2 patients (13.4%) and 6/24 in 1 (6.67%) case. However visual acuity improved to 6/9-6/18 in 9 patients (60%), 6/24-6/36 in 5 patients (33.4%) and 6/60 in 1 (6.67%) case respectively. This last case had late presentation in addition to retinal detachment. The above mentioned post-operative visual acuity was of last follow-up as well as it was corrected with glasses where needed. When comparison was done between pre-operative visual acuity and visual acuity of last follow-up it showed $p < 0.001$ that is statistically highly significant (Table-II).

CONCLUSIONS

We have concluded from our study that combined vitrectomy and intraocular lens implantation in patients having retained lens matter presenting with raised intraocular pressure, reduced visual acuity, uveitis, cystoid macular edema and retinal detachment is an option to be considered to reduce the risk of post operative complications including secondary glaucoma, uveitis and restoration of good visual acuity. If management of such cases is done by vitreoretinal surgeons then there is also very low rate of retinal detachment which is one of

the sight threatening complications in such cases. So all anterior segment surgeons should preferably refer such cases to vitreoretinal surgeons for proper management.

Copyright 01 Aug, 2011.

REFERENCES

1. Kanski JJ. **Clinical ophthalmology**. 5C ed. London: Butterworth & Heinmann 2003; 165-73.
2. Aasuri MK, Kompella VB, Majji AB. **Risk factors for and management of dropped nucleus during phacoemulsification**. J Cataract Refract Surg 2001; 27: 1428-32.
3. Ross WH. **Management of dislocated lens fragments after phacoemulsification surgery**. Can J Ophthalmol 1996; 3: 234-40.
4. Aaberg TM, Rubsamen PE, Flynn HW Jr, Chang S, Mieler WF, Smiddy WE. **Giant retinal tear as complication of attempted removal of intravitreal lens fragments during cataract surgery**. Am J Ophthalmol 1997; 124: 222-5.
5. Lu H, Jiang YR, Grabow HB. **Managing a dropped nucleus during the phacoemulsification learning curve**. J Cataract Refract Surg. 1999; 25:1311-2.
6. Rossetti A, Doro D. **Retained intravitreal lens fragments after phacoemulsification; complications and visual outcome in vitrectomized and nonvitrectomized eyes**. J Cataract Refract Surg 2002; 28:10-5.
7. Meredith TA. **Atlas of retina and vitreous surgery**. 1st Ed. St. Louis Missouri: Mosby 1999; 77-80.
8. Stefanidou M, Aspiotis M, Pappa C, Eftaxias V, Psilas K. **Timing of dislocated nuclear fragments management after cataract surgery**. J Cataract Refract Surg 2003; 29: 985-8.
9. Greven CM, Picoone K. **Delayed visual loss after pars plana vitrectomy for retained lens fragments**. Retina 2004; 24: 363-7.
10. Scott IU, Flynn HW Jr, Smiddy WE, Murray TG, Moore JK, Lemus DR. et al. **Clinical features and outcomes of pars plana vitrectomy in patients with retained lens fragments**. Ophthalmology 2003; 110: 1567-72.
11. Kamal Z. **Vitreotomy for retained lens material after phacoemulsification surgery**. J Coll Physicians Surg

- Pak 2000; 10: 447-50.
12. Snell RS, Lemp MA. **Clinical anatomy of eye**. 3rd Ed. Boston: Black Scientific Publication, 1989; 180.
 13. Blodi BA, Flynn HW Jr, Diodi CF, Folk JC, Daily MJ. **Retained nuclei after cataract surgery**. *Ophthalmology* 1992; 99: 1263-9.
 14. Kageyama T, Ayaki M, Ogasawara M, Asahiro C, Yaguchi S. **Results of vitrectomy performed at time of phacoemulsification complicated by intravitreal lens fragments**. *Br J Ophthalmol*. 2001; 85: 1038-40.
 15. Borne MJ, Tasman W, Regillo GC, Malecha M, Sarin L. **Outcome of vitrectomy for retained lens fragments**. *Ophthalmology* 1996; 103: 971-6.
 16. Irvine WD, Flynn HW Jr, Murray TG, Rubsaman PE. **Retained lens fragments after phacoemulsification manifesting as marked intraocular inflammation with hypopyon**. *Am J Ophthalmol* 1992; 144: 610-4.
 17. Kim JE, Flynn HW Jr, Rubasama DE, Murray TG, Davis JL, Simiddy WE. **Endophthalmitis in patients with retained lens fragments after phacoemulsification**. *Ophthalmology* 1996; 103: 575-8.
 18. Wallace RT, Mcnamara JA, Brown G, Benson W, Belman J, Goldberg R, Federman J. **The use of pcrfluorophenanthrene in removal of intravitreal lens fragments**. *Am J Ophthalmol* 1993; 116: 196-200.
 19. Lewis H, Blamankran MS, Chang S. **Treatment of dislocated crystalline lens and retinal detachment with perfluorocarbons liquids**. *Retina* 1992; 12: 299-304.
 20. Smith PW, Stone WJ, Maumence AE, Enger CI, Michels RG, Glasser BM, Bonhan RD. **Retinal detachment after extracapsular cataract extraction with posterior chamber intraocular lens**. *Ophthalmology* 1987; 94: 495-504.
 21. Lambarous FIT Stewart MW. **Management of dislocated fragments during Phacoemulsification**. *Ophthalmology* 1992; 99: 1260-2.
 22. Kapusata MA, Chen JC, Lam W. **Outcome of dropped nucleus during phacoemulsification**. *Ophthalmology* 1996; 103: 1184-7.
 23. Murat UO, Kapran Z, Akkan F, Cilsim S, Eltutar K. **Vitrectomy Surgery for retained lens fragments after phacoemulsification**. *Eur J Ophthalmol* 2003; 13: 69-73.
 24. Fastenburg DM, Schwartz PL, Shakin LL, Golub BM. **Management of dislocated nuclear fragments after phacoemulsification**. *Am J Ophthalmol* 1991; 112: 535-9.
 25. Wong D, Briggs MC, Hickery-Dwyer MU, McGalliard JN. **Removal of lens fragments from vitreous cavity**. *Eye* 1997; 11: 37-42.
 26. Fung WE. **Phacoemulsification**. *Ophthalmology* 1978; 85: 46-51.

Article received on: 01/07/2011

Accepted for Publication: 01/08/2011

Received after proof reading: 02/12/2011

Correspondence Address:

Dr. Faheem Ahmad
 Assistant Professor
 Independent Medical College,
 Faisalabad.
 doctorfaheem2000@yahoo.com

Article Citation:

Ahmad F, Haider SA. Dropped nucleus during phacoemulsification; outcomes. *Professional Med J Dec* 2011; 18(4): 715-721.

PREVIOUS RELATED STUDIES

- **Nauman Ayub Shaikh, Farooq Ahmad.** Diabetic retinopathy; effect of phacoemulsification. *Prof Med Jour* 17(2) 257-262 Apr, May, Jun 2010.