



## OUTCOME OF THE CLOSED DIAPHYSEAL HUMERAL FRACTURE TREATED WITH DYNAMIC COMPRESSION PLATE

1. MBBS, MS  
Consultant Orthopaedic Surgeon  
Liaquat University Hospital  
Jamshoro
2. MBBS, FCPS  
Associate Professor of Orthopaedic  
Department of Surgery and  
Traumatology  
Liaquat university Hospital  
Jamshoro
3. MBBS, MS  
Consultant Orthopaedic Surgeon  
Liaquat University Hospital  
Jamshoro
4. MBBS  
Liaquat University Hospital  
Hyderabad

**Correspondence Address:**  
**Dr. Imran Khan Mehar**  
National Medical Centre  
Near National CNG Khurshid Town  
Hala Naka Hyderabad.  
dr.sajidarain@gmail.com  
drikmaher@hotmail.com

**Article received on:**  
30/04/2014

**Accepted for publication:**  
05/07/2014

**Received after proof reading:**  
16/10/2014

### INTRODUCTION

Fractures of the humeral shaft are commonly encountered in orthopedic clinics, and these fractures make up 1.31 to 3% of all fractures<sup>1</sup>. The treatment approaches for these injuries continue to evolve as advances are made in both non operative and operative management<sup>2</sup>. The humeral shaft is covered with muscles and is well vascularized. A slight malunion is functionally tolerated. It is generally agreed that the majority of humeral shaft fractures are best treated nonoperatively, but there are indications for primary or secondary operative treatment in some situations<sup>3</sup>. Non operative or conservative treatment may involve the use of casts or functional braces. In cases associated with severe complications, an operative intervention is preferred<sup>4</sup>. The encouraging outcomes that have been demonstrated with recent advances in internal fixation techniques and instrumentation have led to an expansion of surgical indications

**Dr. Imran Khan Maher<sup>1</sup>, Dr. Muhammad Ayub Laghari<sup>2</sup>, Dr. Shakeel Ahmed Memon<sup>3</sup>,  
Dr. Muhammad Saeed Arain<sup>4</sup>**

**ABSTRACT... Objective:** To determine the treatment outcome of the closed diaphyseal humeral fracture treated with dynamic compression plate at Liaquat university hospital Hyderabad. **Materials and methods:** Total 30 patients having displaced diaphyseal humeral fracture were included in the study. All the patients having fracture of less than 10 days and between the ages 15 – 45 years were selected. All the patients selected after counseling and diagnosed as a case of closed diaphyseal humeral shaft fracture on the basis of clinical examination and X-rays. In this study dynamic compression plates (DCP) were used for stabilization of humeral shaft fracture as assessed by pre operative workup, operative findings and outcomes were recorded with postoperative complications. To avoid the radial nerve palsy it is isolated during operative procedure. **Results:** Present study was comprises of 30 patients with humeral fracture with the mean age of  $30.29 \pm 8.92$  years and male/ female ratio of 7:3. On the radiological findings most common type of fracture was oblique in 54%. From the complications, postoperative pain was found in 6.6% of the cases along with postoperative Infections in 10%. 90% fractures united while 10% fractures found with non union. Excellent result were seen in 60% of the cases, while 30% cases were noted with satisfied results and very poor results were found in 10% of the cases. **Conclusions:** It is concluded that DCP is the good option for the fixation of diaphyseal humerus fracture. Radial nerve palsy is less likely if isolated during operation.

**Key words:** Diaphyseal humeral fracture, dynamic compression plate.

**Article Citation:** Maher IK, Laghari MA, Memon SA, Arain MS. Outcome of the closed diaphyseal humeral fracture treated with dynamic compression plate. Professional Med J 2014;21(5):1021-1025.

for humeral shaft fractures. There are new debates regarding the procedure of choice<sup>4</sup>. Surgical treatment is generally indicated in patients in whom there is a failure to maintain stable alignment and reduction at the fracture site and in the patients with severe segmental fractures, open fractures, or fractures associated with bilateral fractures, forearm fractures on the same side, poly trauma, progressive neurological deficits, vascular injury or floating shoulder or elbow<sup>5,6</sup>. The options for the commonly used surgical treatment of humeral shaft fractures include intramedullary nailing (IMN) and dynamic compression plate (DCP), which offer good clinical outcomes<sup>4</sup>. At present, both of these surgical procedures are used to treat humeral shaft fractures. Both techniques have certain mechanical and anatomical advantages and disadvantages. Plating with stable fixation and direct visualization, which is known to provide an accurate anatomic reduction and protection of the radial nerve, can reduce the risk of malunion

but requires wide intra operative exposure associated with soft tissue stripping<sup>4</sup>. The purpose of this study to determine the efficacy of dynamic compression plate in closed diaphyseal humeral fracture in both gender along with postoperative complications and outcome.

## MATERIAL & METHODS

This descriptive study included 30 patients and was carried out at Orthopaedic Unit-I of Liaquat University Hospital Hyderabad/Jamshoro. Study was conducted in the time duration from January 2011 to January 2012. Both genders were included in the study. All the patients with closed diaphyseal, humeral shaft fracture associated with other minor injuries. Fracture of less than 10 days and between the ages 15 – 45 years were included in the study. All the patients after counseling and taking written consent were included in this study irrespective of sex and admitted in Orthopaedics Unit-I through outpatient department as well as from casualty department and diagnosed as case of type A1-2 , A2-2 and A3-2 closed diaphyseal humeral shaft fracture on the basis of clinical examination and X-rays as FIGURE. All the cases with open fracture, associated with severe chest or abdominal injuries, pathological fractures and malunited fractures with neurological deficit were excluded from the study. In this study dynamic compression plates (DCP) were used for the treatment of closed diaphyseal humeral shaft fracture as assessed by pre operative work up, operative findings and outcomes were recorded with postoperative complications figure:2. Detailed Clinical examination of the patient along with all base line investigations were done and recorded in preforma. Data was entered and analyzed in the SPSS program version 17.0 simple frequencies and percentages of the qualitative data were computed. No statistical test was applied due to descriptive study.

## RESULTS

Present study was done on 30 patients with humeral fracture, out of all patients male were found in the majority 70% as compare to the females 30% with male/female ratio of 7:3 mean age of this study was  $30.29 \pm 8.92$  years. Most

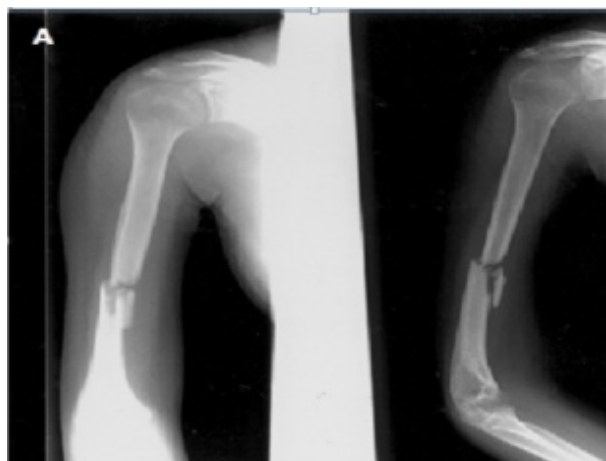
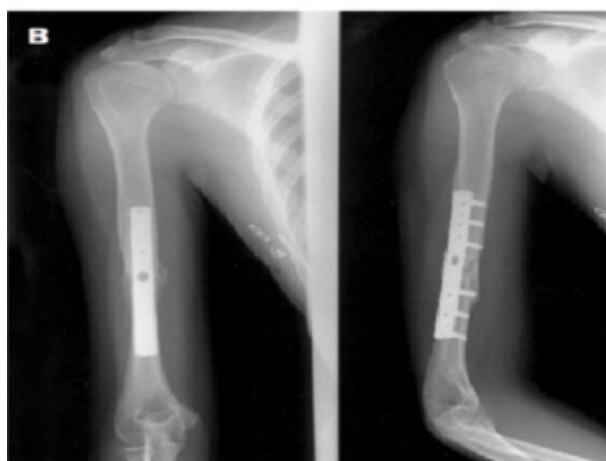

Figure. Right Humeral Shaft Fracture.



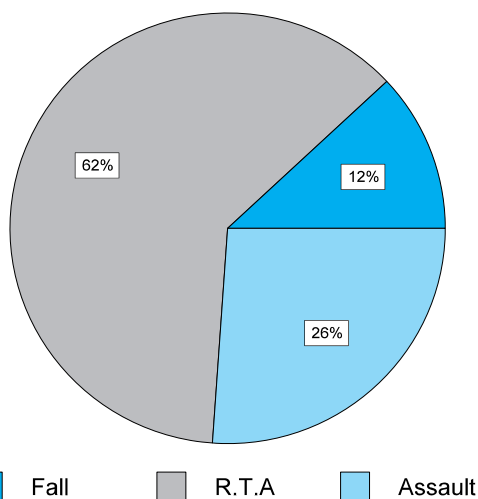
Postoperative Plain Film Showing Dynamic Compression Plate

common age group was noted between 15- 24 years of the age with the percentage of 50%, while 30% cases were documented with the age group of 25-34 and only 20% cases were noted in the age group of 35-45 years. Fracture location was seen on left sides 40% and 40% on right side while bilateral fracture only 20% was found. Table-I

The most common cause of fracture shaft of humerus in our study was road traffic accident (RTA). There were 62% patients who sustained fractures of the humerus following road traffic accidents as well as 12% cases had fractures shaft of humerus after fall from height and 26% cases had fractures shaft after assault. Fig 1.

	Frequency	%age
<b>Gender</b>		
Male	21	70.0%
Female	09	30.0%
<b>Age groups</b>		
15-24	15	50.0%
25-34	09	30.0%
35-45	06	20.0%
<b>Fracture location</b>		
Left	12	40.0%
Right	12	40.0%
Bilateral	06	20%

**Table-I. Basic characteristics of the Patients. (n=30)**

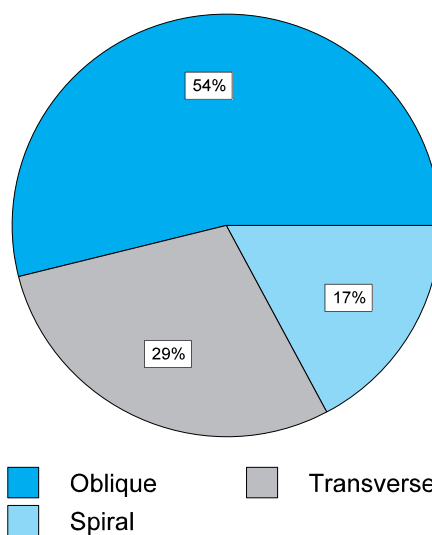


**Fig-1. Mode of injury. N=30**

On the radiological findings fracture pattern was Oblique in 54% of the patients while Transverse were seen in 29% and Spiral fractures were documented in the 17 % of the cases in the present study. FIG: 2.

The complications of this study as (post-operative pain was in found in 6.6% of the cases), Infection was found in 10% while Iatrogenic palsy of radial nerve, non union, adhesive capsulitis and implant failure were seen in the cases 3.3%, 10.0%, 3.3% and 3.3% respectively. Table-II

Excellent results were seen in 60% of the cases, while 30% cases were noted with satisfied results and very poor results were found in only 10% of the cases. Table-III



**Fig-2. Radiographic findings (n=30)**

	Frequency	%age
<b>COMPLICATIONS</b>		
Post operative pain	02	6.6%
Infection	03	10.0%
Iatrogenic Palsy Radial Nerve	03	10.0%
Non Union	03	10.0%
Adhesive Capsulitis (shoulder)	01	3.3%
Implant failure	01	3.3%

**Table-II. Postoperative complications and outcome. N=30**

Outcome	Frequency	%age
Excellent	18	60.0%
Fair	09	30.0%
Poor	03	10.0%

**Table-III. Functional outcome. N=30**

**DISCUSSION**

Present study was done on 30 patients with humeral fracture. Out of all patients male were found in the majority 70% as compare to the females 30%. The higher rate of fracture in male clearly correlates with the life style of male, mostly in our part of world. The males are more involved in outdoor activities and the young male are more enthusiastic about life and are careless drivers. Female usually have sedentary life style and less involved in driving which is a common cause. However the male to female ratio given by Mirdad TM<sup>7</sup> is 9.8:1, Reyes-Saravia GA<sup>8</sup> is 3.4:1. While in this study male/female ratio was of 7:3.

Mean age in this study is 30.29 years  $\pm$  8.92 years most common age group was noted between 15-24 years of the age with the percentage of 50%, while 30% cases were documented with the age group of 25-34 and only 20% cases were noted in the age group of 35-45 years. Fracture location was seen on left sides 50% and 40% on right side while bilateral fracture only 10% were found. Age group of the patients in the study of JPS Walia MS. Et al,<sup>9</sup> were varied between 18-70 years with majority of the patients in fifth to seventh decade of life.

The most common cause of fracture shaft of humerus in our study was road traffic accident (RTA). There were 62% patients who sustained fractures of the humerus following road traffic accidents and 12% cases had fractures shaft of humerus after fall from height and 26% cases had fractures shaft after assault. According to the study of Memon FA,<sup>10</sup> 63.7% patient's had fractures and soft tissue injuries caused by road traffic accident and 36.2% were resulted of domestic fall. In another study by Putti AB,<sup>11</sup> out of 34 patients the cause of the injuries leading to admission was RTA in 82.3%. The findings of present study matches these studies the road traffic accident is the most common cause of fracture shaft of humerus.

On the radiological findings fracture pattern was Oblique in 54% of the patients while Transverse were seen in 29% and Spiral fractures were documented in the 17 % of the cases in the present study. A study on humeral shaft by Olasinde Anthony Ayotunde et al, reported that the transverse fracture was the most common<sup>12</sup>. Ring D et al,<sup>13</sup> found that most common fractures oblique and spiral.

Complications in this study were seen as, postoperative pain, found in 10% of the cases, Infection was create in 10% of patients. However frequency of wound infection given by Bell et al<sup>14</sup> in a series of 33 patients treated with dynamic compression plate, there was 1(3%) case of infection. Wound infection occasionally remains superficial and the bone escapes but more often

the infection extends to the bone and gives rise to osteomyelitis<sup>15</sup>. While iatrogenic palsy of radial nerve, non union, adhesive capsulitis and implant failure were seen in the cases 0%, 10%, 3.3% and 3.3% respectively. In the respective IMN and DCP groups rates reported of iatrogenic radial nerve palsy were 2.6 to 14.3%<sup>16</sup> and 2 to 5%<sup>17,18</sup>. The incidence of nonunion reported in the literature is between 0–8%<sup>19,20</sup>. In the study of Erwin Denies et al,<sup>21</sup> on humeral shaft fracture; he reported that 71.4% excellent results, in 20.9% good results and poor results in 4.4%. In this study excellent result were seen in 60% of the cases, while 30% cases were noted with satisfactory results and very poor results were found only in 10% of the cases.

## CONCLUSIONS

In the conclusion of this study total 30 patients with humeral shaft fractures, that were treated by dynamic compression plate, fractures were found in young male cases and Road traffic accidents were seen in majority. The dynamic compression plate is the very good management method for treatment of fracture shaft of humerus with very low rate of complications.

Copyright© 25 July, 2014.

## REFERENCES

1. Tsai CH, Fong YC, Chen YH, Hsu CJ, Chang CH, et al. **The epidemiology of traumatic humeral shaft fractures in Taiwan.** *Int Orthop* 2009;33:463–467.
2. Sarmiento A, Zagorski JB, Zych GA, Latta LL, Capps CA. **Functional bracing for the treatment of fractures of the humeral diaphysis.** *J Bone Joint Surg Am* 2000;82:478–486.
3. Sarmiento A, Waddell JP, Latta LL. **Diaphyseal humeral fractures: treatment options.** *Instr Course Lect* 2002;51:257–269.
4. JianXiong Ma1,2., Dan Xing2., XinLong Ma2,3\*, et al. **Intramedullary Nail versus Dynamic Compression Plate Fixation in Treating Humeral Shaft Fractures: Grading the Evidence through a Meta-Analysis.** 2013; (8);12:1-12.
5. Mulier T, Seligson D, Sioen W, van den Bergh J, Reynaert P. **Operative treatment of humeral shaft fractures.** *Acta Orthop Belg* 1997;63:170–177.
6. Robinson CM, Bell KM, Court-Brown CM, McQueen MM. **Locked nailing of humeral shaft fractures.**

- Experience in Edinburgh over a two-year period.** J Bone Joint Surg Br 1992;74:558–562.
7. Mirdad TM. **Neuro-vascular injuries associated with limb fractures.** East African Medical Journal 2000; 77(12):663-666.
  8. Reyes-Saravia GA. **Complications of surgical treatment of humeral shaft fractures managed with a UHN pin: comparison of antegrade versus retrograde insertion.** Acta Ortopédica Mexicana 2005; 19( 1):22-27.
  9. JPS Walia MS\*, Avinash Gupta MS\*\*, Girish Sahni MS\*\*\*, Gagandeep Gupta MBBS\*\*\*\*, Sonam Kaur Walia MBBS\*\*\*\*\* **Role of locking compression plate in long bone fractures in adults - a study of 50 cases.** Pb Journal of Orthopaedics Vol-11: 2009:41-43.
  10. Memon FA, Saeed G, Fazal B, Bhutto I, Laghari M, Siddique KA, Shaikh AR. **Complicationsof fracture treatment bytraditional Bone setters at hyderabad.** J Pak Ortho Asso 2009;21(2):58-64.
  11. Putti AB, Uppin RB, Putti BB. **Locked intramedullary nailing versus dynamic compression plating for humeral shaft fractures.** Journal of Orthopaedic Surgery 2009;17(2):139-41.
  12. Olasinde Anthony Ayotunde<sup>1</sup>, Oluwadiya Kehinde Sunday<sup>2</sup>, Adetan Oluwatoyin<sup>1</sup>, Ogunlusi Johnson Dare<sup>3</sup>. **Results of surgical treatment of nonunion of humeral shaft fracture with dynamic compression plate and cancellous bone grafting.** Acta Ortop Bras. 2012;20(4): 223-5
  13. Ring D, Chin K, Taghinia AH, Jupiter JB. **Nonunion after functional brace treatment of diaphyseal humerus fractures.** J Trauma. 2007;62(5):1157-8.
  14. Bell MJ, Beauchamp CG, Kellam JK, McMurtry RY. **The results of plating humeral shaft fractures in patients with multiple injuries. The sunny brook experience.** Br . Edi Society Bone Joint Surgery 1985.
  15. Carl NL , Alex MC , Sandra MG , Jeffrey JW , Mark SS . **Is Aseptic Loosening Truly Aseptic?** Clinical Orthopaedics & Related Research 2005;437: 25-30.
  16. Ruedi T, Moshfegh A, Pfeiffer KM, Allgower M. **Fresh fractures of the shaft of the humerus—conservative or operative treatment?** Reconstr Surg Traumatol 1974;14:65–74.
  17. Bumbasirevic M, Lesic A, Bumbasirevic V, Cobeljic C, Milosevic I , Atkinson HDE. **The management of humeral shaft fractures with associated radial nerve palsy: a review of 117 cases.** Arch of Ortho and Trauma Surg 2009;130(4):519-522.
  18. Fatemi MJ, Habibi H, Pooli AH, Mansoori MJ. **Delayed Radial Nerve Laceration by the Sharp Blade of a Medially Inserted Kirschner-Wire Pin: A Rare Complication of Supracondylar Humerus Fracture.** Am J of Ortho 2009;38-40.
  19. Ingman AM, Waters DA. **Locked intramedullary nailing of humeral shaft fractures.** JBJS 1994; 76:23–24.
  20. Lin J, Shen PW, Hou SM. **Complications of locked nailing in humeral shaft fractures.** J Trauma 2003;54(5):943–949.
  21. Erwin DENIES, Stefaan NijS, An SERMON, Paul BROOS. **Operative treatment of humeral shaft fractures. Comparison of plating and intramedullary nailing.** Acta Orthop. Belg., 2010, 76, 735-742