

# PROPARACAINE; EFFICACY AS A TOPICAL ANESTHETIC IN PTERYGIUM SURGERY

ORIGINAL  
PROF-1990

## DR. MUHAMMAD IMRAN SALEEM

MBBS, FCPS-(I)  
Postgraduate Resident, Department of Ophthalmology, Eye unit-II,  
Bahawal Victoria Hospital, Bahawalpur.

## DR. MUHAMMAD ARSHAD

MBBS, FCPS-(I)  
Postgraduate Resident, Department of Ophthalmology, Eye unit-II,  
Bahawal Victoria Hospital, Bahawalpur.

## DR. MUHAMMAD FARHAN SALEEM

MBBS, FCPS-(I)  
Postgraduate Resident, Department of Ophthalmology, Eye unit-II,  
Bahawal Victoria Hospital, Bahawalpur.

**ABSTRACT... Objective:** To evaluate the efficacy of proparacaine 0.5% as a topical anesthetic in pterygium surgery. **Study Design:** Quasi-Experimental study. **Place and Duration:** Eye Unit-II, Bahawal Victoria Hospital, Bahawalpur, from December 2010 to April 2011. **Methodology:** Thirty patients affected by primary pterygium underwent pterygium excision under topical anesthesia using proparacaine 0.5% eye drops. Pterygium excision was performed along with dissection of the degenerative conjunctival tissue, scraping of the corneal surface with surgical blade No.15, meticulous dissection of the underlying Tenon's capsule, preparation of a free conjunctival graft from the superotemporal sector of healthy conjunctiva, and positioning of this graft to the area of bare sclera using 6/0 vicryl suture. Computer software SPSS (version 10) was used to analyze the data. Results were considered statistically significant at  $p < 0.05$ . **Results:** It was possible to perform all the procedure under topical anesthesia using 0.5% Proparacaine eye drops without a need of supplemental subconjunctival or peribulbar anesthesia. Pain reported by the patients, recorded by a Visual Analog Scale (VAS) with 0-4 grades, and was mild to moderate during the entire surgical procedure. **Conclusions:** Topical proparacaine 0.5% is a safe and effective anesthetic in pterygium surgery. The long lasting anesthesia with this agent permits performing the surgical procedure with low pain felt by the patients with a resultant low surgical invasivity and a short duration of surgery.

**Key words:** Anesthesia; Conjunctival autograft; Pterygium; Pterygium excision.

## INTRODUCTION

Pterygium is a benign fibrovascular growth of degenerative conjunctival tissue that usually arises from the bulbar conjunctiva and extends across the limbus towards the cornea in horizontal meridian of the globe. A symptomatic pterygium leads to visual impairment, cosmetic blemish and ocular motility restriction<sup>1</sup>. The standard treatment of a symptomatic pterygium is the surgical excision of the lesion. The traditional approach used for surgical removal of a pterygium consisted of dissection of the conjunctival tissue, scraping of the corneal surface, excision of the Tenon's capsule and closure of the conjunctiva with the help of sutures<sup>1,2</sup>. More recently, pterygium surgery has undergone modifications to reduce the risk of recurrence. This includes the introduction of conjunctival autograft and the application of amniotic membrane grafts applied with the help of absorbable or non-absorbable sutures, or with fibrin glue<sup>3-6</sup>.

It is a well-known fact that most of the ophthalmic surgical procedures are carried out under local anesthesia in order to achieve an optimum patient comfort. The exact

mechanism by which local anesthetics act is unknown; however, several studies indicate that local anesthetics may limit sodium ion permeability by closing the cell membrane channels through which the ions migrate into the lipid layer of the nerve cell membrane. This limitation prevents the fundamental change necessary for the generation of the action potentials<sup>5,6,7,8</sup>. The injection of local anesthetic solutions is frequently an unpleasant experience for the patient. Infiltration of the skin and subcutaneous tissues with local anesthetic solutions produces pain, burning and discomfort, which is often severe enough to be the most unpleasant part of a minor surgical procedure like pterygium excision. The pain experienced on injection of local anesthetic solutions is in part related to the pH of the solution and this is particularly true for the solutions with added adrenaline. Additionally, the injection of anesthetic with a sharp needle may result in complications such as subconjunctival hemorrhage, chemosis or globe perforation<sup>5-10</sup>.

In the recent times, many new and effective anesthetic

agents have been tested in ocular surgery. Proparacaine is one such anesthetic agent which has been shown to have a great margin of safety with a long lasting anesthetic effect during ocular surgery. Proparacaine hydrochloride solution is a rapid acting local anesthetic suitable for ophthalmic use. With a single drop, the onset of anesthesia occurs in approximately 13 seconds and persists for 15 minutes<sup>10,11,12</sup> the main site of action of this drug is the nerve cell membrane where proparacaine interferes with the large transient increase in the membrane permeability to sodium ions that is normally produced by a slight depolarization of the membrane. As the anesthetic action progressively develops in a nerve, the threshold for electrical stimulation gradually increases and the safety factor for conduction decreases; when this action is sufficiently well developed, block of conduction is produced leading to the anesthetic effect.

Proparacaine 0.5% has already established its role as a topical anesthetic in cataract surgery. All of the published data about this topical anesthetic suggests that proparacaine 0.5% solution provides adequate anesthesia and patient comfort during the phacoemulsification technique of cataract extraction<sup>10-13</sup>. To date, there is a lack of evidence in published literature whether this topical anesthetic is effective in other ophthalmic surgical procedures like pterygium excision or not. In view of this, we decided to evaluate the effectiveness of topical proparacaine as an anesthetic agent in pterygium surgery.

## MATERIALS AND METHODS

This study was conducted from December 2010 to April 2011. The permission for the study was taken from the local ethical committee of our hospital. Patients with primary pterygium, presenting to the outdoor patient department of our hospital, were included in the study. A full informed consent was taken from all the patients regarding the surgical procedure and the use of topical anesthesia with proparacaine 0.5 % (Alcaine) eye drops before and during surgery.

Patients having psychiatric illness, pregnancy, deafness, anxiety and language barriers were excluded from the study. All patients underwent a complete ophthalmic

examination before surgery, including best corrected visual acuity, ocular motility examination, slitlamp biomicroscopy with photographs of the anterior segment of the eye and Slitlamp fundus examination using indirect fundus viewing lens (+90D).

All patients were operated for pterygium using topical proparacaine 0.5% eye drops (Alcaine, Alcon-Couvreur, Fort worth, Texas, and U.S.A). The drug was administered to each patient at a rate of one drop every five minutes for six times before surgery and every five minutes during surgery.

All patients were informed beforehand that if the topical anesthesia was inadequate, a traditional subconjunctival or peribulbar infiltration could be made at their request. All operations were performed by the authors using standardized technique with dissection of the pterygium using Westcott scissors and surgical blade No.15. Pterygial tissue was removed from the corneal surface and a meticulous dissection of the underlying Tenon's capsule was carried out. A gentle cautery was used to control the bleeding.

A free autologous conjunctival graft was then prepared from the superotemporal conjunctiva of the same eye. The graft size was approximately 2mm larger than the area of excised pterygium. Graft thus obtained was then shifted to the area of bare sclera. This was then sutured to the conjunctiva using absorbable 6/0 vicryl suture applied in an interrupted manner.

At the end of surgery, each patient was asked about the intensity of ocular pain and discomfort experienced during the procedure. A grading scale based on pain score called Visual Analog Scale (VAS) was used to evaluate the subjective pain experienced by the patients i.e.: Pain Score 0= No pain; Pain score 1-4 = Mild pain; Pain Score 5-8 =Moderate pain; Pain Score 9-12 = Severe pain. Computer software SPSS (version 10) was used to analyze the data.

## RESULTS

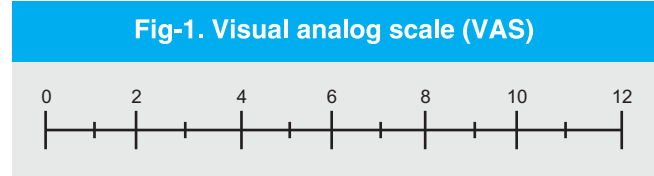
This study included thirty patients of primary pterygium, 21 males (70%) and 9 females (30%). The mean age was 40 years (Table-I). The mean time of the surgical

procedure was 30+11 minutes. Twenty five patients (83.3%) reported mild pain during the surgery (pain score 1-4). Only five patients (16.6%) had moderate pain during the surgery (pain score 5-8) while no patients had severe pain during the entire intervention. There were no patients needing supplemental injections of subconjunctival or peribulbar anesthesia. (See table-II for details)

Table-I. Age and sex distribution of patients			
Age (years)	No. of patients		
	Male	Female	Total
20-30	7 (23.3%)	1 (3.3%)	8 (26.6%)
40-50	8 (26.6%)	6 (20.0%)	14 (46.6%)
50-60	6 (20.0%)	2 (6.6%)	8 (26.6%)
Grand Total	21 (70.0%)	9 (30.0%)	30 (100%)

Table-II. Pain grading based on visual analog scale (VAS)				
Pain Score	Pain Grade	No. of patients		
		Male	Female	Total
-	No pain	-	-	-
1-4	Mild pain	17 (56.6%)	8 (26.6%)	25 (83.3%)
5-8	Moderate pain	4 (13.3%)	1 (3.3%)	5 (16.6%)
9-12	Severe pain	-	-	-
Grand Total		21 (70.0%)	9 (30.0%)	30 (100%)

Pain score according to VAS	Pain grade
-	No pain
1-4	Mild pain
5-8	Moderate pain
9-12	Severe pain



**DISCUSSION**

Pterygium surgery under topical anesthesia has many advantages over traditional paraocular anesthesia: no pain from the anesthetic application, no needle-related complications (hemorrhage, chemosis or globe perforation), no need to discontinue systemic anticoagulants or aspirin and immediate visual recovery<sup>10-13</sup>. Nevertheless, topical anesthesia has also its limitations: the surgeon must be very competent to be comfortable, and not every patient is a good candidate for topical anesthesia. The main disadvantage of topical anesthesia is the absence of akinesia. To achieve akinesia, patients are usually advised to look at the light of the microscope during the surgical procedure. The surgeon's communication with the patient is very important in order to relieve patient's anxiety. Encouraging the patient is very important to obtain optimal patient's cooperation.

Recently, a number of reports compared the patient comfort during pterygium surgery with topical anesthesia alone versus subconjunctival or peribulbar anesthesia. In a randomized prospective trial using a visual analog pain scale, oksuz et al found no significant difference in intraoperative pain scores between patients who received topical anesthesia alone versus patients receiving subconjunctival injection of lidocaine<sup>14,15</sup>.

In another study, topical Ropivacaine was evaluated for its efficacy as an anesthetic agent during pterygium surgery. The authors found that topical Ropivacaine was effective and safe anesthetic in pterygium excision<sup>16</sup>.

To our knowledge, this is the first study in which efficacy of topical proparacaine has been tested for use in pterygium surgery. We applied this form of anesthesia with pterygium excision and conjunctival autograft in an attempt to shorten the time duration needed for the whole surgical procedure and to avoid the complications related to the subconjunctival and peribulbar anesthesia.

Previous studies related to anesthetic injection have documented numerous complications, although the rate of occurrence is very low. Complications due to needle injection can even be vision-threatening. These complications include subconjunctival hemorrhage, chemosis, conjunctival injection holes and globe perforation<sup>16-20</sup>.

Topical anesthesia with proparacane was effective in providing anesthesia in pterygium surgery. The pain perceived by our patients was low with the low surgical invasivity, short duration of surgery, and no apparent toxicity in our cohort. A randomized study will be needed to confirm the results of this prospective non comparative study. Our study demonstrated that topical proparacaine 0.5% solution can be a safe and reliable method of anesthesia for pterygium surgery. This method of anesthesia may be a good choice for minor eye surgeries such as pterygium excision, due to its easy application and sufficient effect.

Furthermore, topical proparacaine 0.5% solution has no particular toxicity on the ocular surface. The ease of application and its adequate effect makes it a more favorable anesthetic choice for patients and surgeons alike in surgeries of this type.<sup>21, 22, 23</sup> We think that the ophthalmologists may be able to prevent the occurrence of any of the probable side-effects associated with needle injection for anesthesia by using topical proparacaine eye drops as an anesthetic agent.

## CONCLUSIONS

We conclude that 0.5% proparacaine solution is an effective and safe anesthetic in pterygium surgery. This method of anesthesia would be particularly useful in patients who have distressing fears of injections and when poor co-operation renders the patient vulnerable to needle-related injuries.

Copyright© 13 Oct, 2012.

## REFERENCES

1. John T. **Pterygium excision and conjunctival mini-autograft: preliminary report.** Eye 2001; 15: 292–296 [PubMed].
2. Wong VW, Rao SK, Lam DS. **Polyglectane sutures versus nylon sutures for suturing of conjunctival autograft in pterygium surgery: a randomized, controlled trial.** Acta Ophthalmol Scand. 2007; 85: 658-661.
3. Farid M, Pirnazar JR. **Pterygium recurrence after excision with conjunctival autograft: a comparison of fibrin tissue adhesive to absorbable sutures.** Cornea. 2009;28:43-45.
4. Koryani G, Seregard S, Kopp ED. **Cut and Paste: a no suture, small incision approach to pterygium surgery.** Br J Ophthalmol. 2004; 89:911-14.
5. Al Fayez MF. **Limbal versus conjunctival autograft transplantation for advanced and recurrent pterygium.** Ophthalmology. 2002; 109: 1752-5[PubMed].
6. Bahar I, Weinberger D, Avisar R, Gaton DD. **Fibrin glue versus vicryl sutures for primary conjunctival closure in pterygium surgery: long term results.** Curr Eye Res. May 2007; 32(5):399-405.
7. Newman D. **Visual experience during phacoemulsification cataract surgery under topical anesthesia.** Br J Ophthalmol. 2000 January; 84(1): 13–15.
8. Németh J, Gombos K. **Comparing Retrobulbar and Topical Anesthesia in Cataract Surgery by Phacoemulsification – How Can Patient Comfort During Surgery by Phacoemulsification Be Improved?** European Ophthalmic Review, 2009; 3(1):42-44.
9. McGee HT, Fraunfelder FW. **Toxicities of topical ophthalmic anesthetics.** Expert Opin Drug Saf. 2007 Nov; 6(6):637-40.
10. Pelosini L, Treffene S, Hollick EJ. **Antibacterial activity of preservative-free topical anesthetic drops in current use in ophthalmology departments.** Cornea. 2009 Jan; 28(1):58-61.
11. Dantas PE, Uesugui E, Nishiwaki-Dantas MC, Mimica LJ. **Antibacterial activity of anesthetic solutions and preservatives: an in vitro comparative study.** Cornea. 2000 May; 19(3):353-4.
12. Kilic A, Gurler B. **Subtenon lidocaine vs. topical proparacaine in adult strabismus surgery.** Ann Ophthalmol (Skokie). 2006-09, 38(3):201-6.
13. Davison M, Padroni S, Bunce C, Rüschen H. **Sub-Tenon's anesthesia versus topical anesthesia for**

- cataract surgery.** Cochrane Database of Systematic Reviews 2007, Issue 3. Art. No: CD006291. DOI: 10.1002/14651858.CD006291.pub2.
14. Frucht-Pery J. **Topical anesthesia with benoxinate 0.4% for pterygium surgery.** Ophthalmic Surg Lasers. 1997 Mar; 28(3):219-22.
  15. Oksuz H, Tamer C. **Efficacy of lidocaine 2% gel in pterygium surgery.** Acta Ophthalmol Scand. 2005 Apr; 83(2):206-9.
  16. Caccavale, Antonio MD, FEBO; Romanazzi, Filippo MD; Imparato, Manuela MD; Negri, Angelo MD; Porta, Alessandro MD; Ferentini, Fabio MD. **Ropivacaine for Topical Anesthesia in Pterygium Surgery With Fibrin Glue for Conjunctival Autograft.** Cornea. 2010 Apr; 29(4):375-6.
  17. Wong AK, Rao SK, Laung AT. **Inferior limbal autograft transplantation for recurrent pterygium.** Indian J Ophthalmol. 2000; 48:21-4.
  18. Frau E, Labetoulle M, Lautier-Fraue M, Hutchinson S, Offret H. **Corneoconjunctival autograft transplantation for pterygium surgery.** Acta Ophthalmol Scand. 2004; 82(1):59-63.
  19. Young AL, Leung GY, Wong AK, Cheng LL, Lam DS. **A randomized trial comparing 0.02% Mitomycin C and limbal conjunctival autograft after excision of primary pterygium.** Br J Ophthalmol. 2004; 88(8):995-7.
  20. Fahim MS, Sayed J, Ali M. **After removal of pterygium role of Mitomycin and conjunctival autograft.** Ann Abbasi Shaheed Hosp Karachi Med Dent Coll. 2005; 10:757-61.
  21. Yao F, Qiu WY, Zhang YM, Tseng SC. **Mitomycin c, Amniotic membrane transplantation and limbal conjunctival autograft for treating multirecurrent pterygia with symblepharon and motility restriction.** Graefes Arch Clin Exp Ophthalmol. 2006; 244(2):232-6[Medline].
  22. Diaz L, Villegas VM, Emanuelli A, Izquierdo NJ. **Efficacy and safety of intraoperative Mitomycin c as adjunct therapy for pterygium surgery.** Cornea. 2008; 27(10):119-21.
  23. Oguz H, Kiliticioglu A, Yasar M. **Limbal conjunctival mini autografting for preventing recurrence after pterygium surgery.** Eur J Ophthalmol. 2006; 16(2):209-13.

Article received on: 24/04/2012

Accepted for Publication: 13/10/2012

Received after proof reading: 05/11/2012

**Correspondence Address:**

Dr. Muhammad Imran Saleem  
House # 15 B.V Hospital Colony Bahawalpur  
imransaleemchanner@yahoo.com

**Article Citation:**

Saleem MI, Saleem MF, Arshad M. Proparacaine; efficacy as a topical anesthetic in pterygium surgery. Professional Med J Dec 2012;19(6): 872-876.