

ACUTE PANCREATITIS IN PREGNANCY

A RARE PRESENTATION

CASE REPORT
PROF-2096

DR. SHAMA CHAUDHRY

MBBS, FCPS

Senior Registrar

Department of Obstetrics & Gynaecology,

Ziauddin University Hospital

PROF. DR. RUBINA HUSSAIN

MBBS, FRCOG, FCPS

President Pakistan Menopause Society

Founder Vice President, South Asian Federation of Menopausal Societies

Chairperson, Royal College of Obstetricians Gynaecologists,

International Representative Committee of Pakistan

Chairperson, Department of Obstetrics Gynaecology, Ziauddin University

ABSTRACT... Acute pancreatitis during pregnancy is rarely encountered and can have a high maternal mortality and fetal loss. We report here a case of a 35-year-old woman para 1+0 previous 1LSCS at 32 weeks of gestation. She had laparotomy at 29 weeks of gestation due to torsion of dermoid cyst in this pregnancy. Now she was presented with, severe epigastric pain, vomiting and pedal edema. Investigation revealed hyperamylasemia and leukocytosis, hypokalemia, hypocalcaemia. The patient was kept on conservative management, antibiotics, analgesics & intravenous fluids. Pancreatitis resolved & she delivered at 38 weeks by caesarean section.

Key words: Hyperamylasemia, leukocytosis, hypokalemia, hypocalcaemia.

INTRODUCTION

Pancreatitis during pregnancy is rare. Schmit in 1818 first reported this condition in a 30-year-old multigravida. Review of literature also reveals that Lawrence described the earliest series of 53 cases in 1838¹. Ramin and al. noted that 19% of acute pancreatitis occurs in the first, 26% in the second, 53% in the third and 2% in the postpartum period, while others reported most of cases, 56%, in the second trimester. In pregnancy gallstones and sludge induce most of the cases of acute pancreatitis, they cause duct obstruction with pancreatic hyperstimulation that increases pancreatic duct pressure, trypsin reflux and activation of trypsin in the pancreatic acinar cells. This leads to enzyme activation within pancreas and causes autodigestion of the gland, followed by local inflammation. Pregnancy does not primarily predispose the pregnant woman to pancreatitis, but it does increase the risk of cholelithiasis and biliary sludge formation. The steroid hormones of pregnancy decrease gallbladder motility. Progesterone is a smooth muscle cell inhibitor that provokes gallbladder volume increase and slows emptying. Estrogens increase cholesterol secretion and minimally alter gallbladder function. Also in the third trimester when the acute pancreatitis is most frequent, the uterus is enlarged and intra abdominal pressure on the biliary ducts is increased².

A 35-year-old para 1+0 woman at 32 weeks of gestation was admitted at 33 weeks of gestation with pain in the

upper abdomen, which was radiating to the back, and with no nausea and vomiting since the last 1 day. Vital monitoring at the time of admission showed a pulse rate of 92/min, a blood pressure of 130/80mmHg and a respiratory rate of 22/min. Physical examination revealed bilateral pedal edema, epigastric tenderness, decreased bowel sounds and a gravid uterus. Fetal heart tones were at 140/min.

Laboratory tests showed a white blood count of 16400/cumm, a haematocrit of 40.75 and a platelet count of 168000. Random blood sugar, arterial blood gas analysis, liver function tests and renal function tests were within normal limits. Serum amylase was 895 IU/l (ref. 20-100 IU/l), lipase 1339 IU/l (ref. 30-60 IU/l), albumin 16g/l (ref. 35-50g/l), calcium 7.9mg/dl (ref. 8.1-10.4mg/dl), potassium 2.4 M Eq/L, bicarbonate 25 M Eq/L, CRP 172.67mg/L (ref. <5mg/L), triglycerides 294mg/dl (ref. <150mg/dl) and uric acid 6.9g/dl (ref. 2.4-6.7mg/dl). Urine analysis was positive for albumin and red blood cells.

Abdominal ultrasonography showed a single live intrauterine fetus with normal cardiac activity and normal liquor. The gallbladder revealed no stone. Common bile duct was 0.4cm. The pancreas could not be visualized due to obscuration by bowel gases. M.R.C.P (Magnetic resonance cholangiopancreatography) showed no evidence of pericholecystic fluid, no mass or definite calculus. Gall bladder was smooth in outline. Common

Bile duct was normal; no filling defect identified. Pancreatic duct was in normal limits. There was subtle high intensity signal seen in pancreatic tail region well outlined in T2W axial image. Findings were most likely pancreatitis. (Fig 1, 2).

Fig-1 M.R.C.P (Magnetic resonance cholangiopancreatography) showing subtle high intensity signal seen in pancreatic tail region in T2W axial image

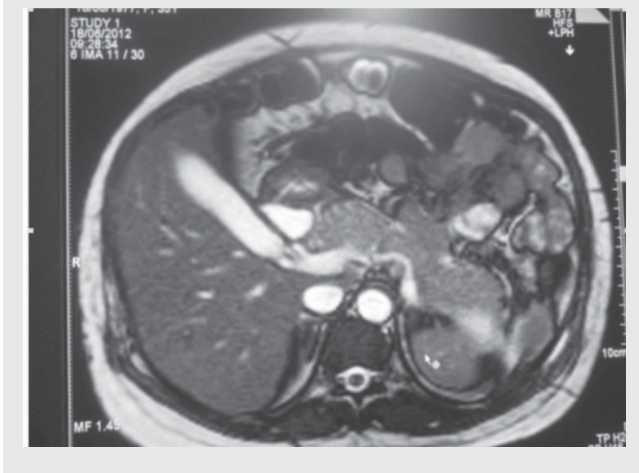
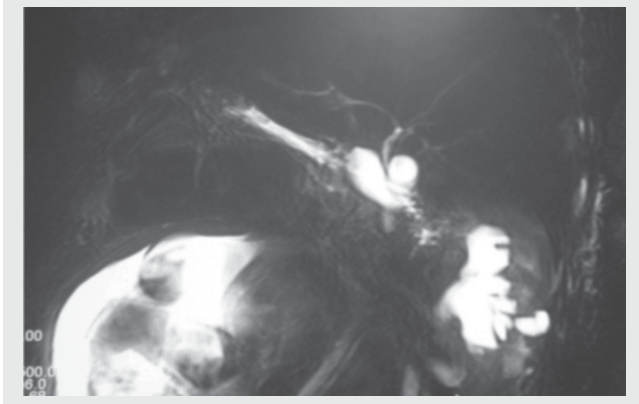


Fig-5 M.R.C.P (Magnetic resonance cholangiopancreatography) showing normal CBD & pregnancy in coronal section



DISCUSSION

The incidence of pancreatitis ranges from 1 in 1066 live births to 1 in 3333 pregnancies. An attack of pancreatitis was previously thought to be common in nulliparous women. Ramin et al. reported pancreatitis during pregnancy in 72% of multiparous women². Pancreatitis can occur during any trimester but around 52% of cases are found in the third trimester; it is rarely seen in the post partum period.² Acute pancreatitis

following medical abortion is also reported³.

Gallstones are the most common etiological factor accounting for about 67-100% of cases. Small stones are more prone to cause pancreatitis. Recently, sludge in the gallbladder has also been reported to cause the disease in pregnancy. Acute pancreatitis develops due to mechanical obstruction at the ampulla of Vater due to passage of stones or sludge^{2,4}.

Hyperlipidaemia is the second most common causative agent. Pregnancy increases the level of serum cholesterol and triglycerides and causes biliary stasis thus inducing the formation of gallstones. Hypertriglyceridaemia may also directly cause acute pancreatitis. The level of serum triglycerides required to induce an attack ranges from 750 to 1000mg/dl.⁵ Alcohol consumption during pregnancy may induce pancreatitis⁶.

Acute necrotizing pancreatitis is also reported in preeclampsia due to pancreatic microvascular alterations⁷.

Clinical presentations include pain in the epigastrium or left hypochondrium with or without radiation to the back, anorexia, nausea, vomiting and jaundice. Signs include abdominal tenderness with decreased bowel sounds. In 10% of cases pulmonary findings may be associated which may lead to full blown adult respiratory distress syndrome⁸. Generalized anasarca may be associated with preeclampsia-associated pancreatitis⁷.

Diagnostic work up includes complete blood count, serum triglycerides, calcium and liver function tests in the form of serum bilirubin, transaminases and alkaline phosphatase. An elevated serum amylase level has a diagnostic sensitivity of 81% and adding serum lipase increases the sensitivity to 94%. The mean amylase in such type of patient is found to be 1400 IU/l. However, amylase levels do not correlate with disease severity^{2,12}.

Imaging of the pancreas can be performed by using ultrasonography and computed tomography. Due to hazards of radiation to the fetus, sonography is preferred which can also detect gallstones with 90% sensitivity. However, the sensitivity for biliary sludge that appears as

low level echoes within the gallbladder which shifts with positioning is lower³.

Magnetic resonance imaging (MRI) and MRCP provide multi-planar large field of view images of the body with excellent soft-tissue contrast and images of biliary-pancreatic duct systems. MRCP does not require any contrast injections and has no risk of renal injury. MRCP is a preferred method of evaluating CBD in many clinical situations^{8,9,10}.

Severity of pancreatitis can be graded using scales such as Ranson's criteria, Imrie's criteria or APACHE II score similar to non-pregnant patients⁴. The most common differential diagnosis of acute pancreatitis in the first trimester of pregnancy is hyperemesis gravidarum. Biliary colic, acute cholecystitis, acute appendicitis and acute fatty liver of pregnancy are other differential diagnoses of this entity^{4,6}.

The treatment of pancreatitis in pregnancy should be conservative as far as possible with delaying the definitive treatment until after delivery. Management includes nil orally, nasogastric aspiration, intravenous fluids, antispasmodics, antibiotics and total parental nutrition. Lipoprotein apheresis and plasmapheresis may be tried to lower serum triglycerides levels. Endoscopic sphincterotomy with fetal shielding with the help of a lead apron may be helpful in treating a gallstone-induced pancreatitis. The second trimester is thought to be the ideal time for endoscopic sphincterotomy to avoid any possible teratogenic effects of radiation. Fetus monitoring should be strictly done during the course of this treatment^{6,12}.

The second trimester is also the optimum time for the patient to undergo any surgical intervention. Cholecystectomy after endoscopic sphincterotomy should be considered in gallstones induced pancreatitis in pregnancy with recurrent attacks. Exploration of the common bile duct may be done where endoscopic sphincterotomy facility is not available. Surgical drainage for acute pancreatitis may help in reducing the load of toxic materials by draining the peritoneal fluid but carries a high morbidity and mortality. Authors have advised to wait with any surgical intervention until delivery, if the

patient develops uncomplicated pancreatitis in the third trimester of pregnancy. Complications such as pseudocysts should be surgically managed in the post partum period^{4,11}.

In the past, pancreatitis during pregnancy had been associated with a high maternal death rate and fetal loss. However, recent studies have shown that these rates are declining due to earlier diagnosis and better treatment options^{6,12}.

CONCLUSIONS

Acute pancreatitis is a rare entity in pregnancy, mainly caused by gallbladder disorders, in which symptoms of cholelithiasis and biliary sludge in many cases precede the symptoms and clinical picture of acute pancreatitis. Diagnosis is based on clinical presentation, laboratory investigations and imaging methods performed with precaution because of potential radiation risk to the fetus.

General management of mild AP in pregnancy is conservative and supportive, while severe AP deserves hospitalization in intensive care unit and endoscopic or surgical interventions.

Copyright© 10 Oct, 2012.

REFERENCES

1. Langmade CF, Edmondson HA. **Acute pancreatitis during pregnancy and postpartum period: report of cases.** SurgGynaecolObstet 1951; 92:43-48.
2. Ramin K, Ramin S, Richey S, Cunningham FG. **Acute pancreatitis in pregnancy.** Am J ObstetGynecol, 1995; 173:187-191.
3. Hallberg P, Hallberg E, Amini H. **Acute pancreatitis following medical abortion: Case report.** BMC Women's Health 2004; 4:1.
4. Cynthia Ko. **Biliary sludge and acute pancreatitis during pregnancy.** Nature Clinical Practice Gastroenterology &Hepatology 2006; 3:53-57.
5. Fields K, Barkin J. **Pancreatic disease.** In **Principles and practice of medical therapy in pregnancy**, ed Gleicher N. Appleton & Lange, Stamford (CT) 1998, 1142-1147.
6. **Update on Non-Obstetric Surgical Conditions in Pregnancy.** Journal of Midwifery & Women's Health.

7. Parmar MS. **Pancreatic Necrosis Associated With Preeclampsia-Eclampsia.** JOP. J Pancreas (Online) 2004; 5(2): 101-104.
8. Myers C, Duncan KR, Gowland PA, Johnson IR, Baker PN. **Failure to detect intrauterine growth restriction following in utero exposure to MRI.** Br J Radiol 1998; 71: 549-551.
9. Kanal E, Gillen J, Evans JA, Savitz DA, Shellock FG. **Survey of reproductive health among female MR workers.** Radiology 1993; 187: 395-399.
10. Baker PN, Johnson IR, Harvey PR, Gowland PA, Mansfield P. **A three-year follow-up of children imaged in utero with echo-planar magnetic resonance.** Am J ObstetGynecol 1994; 170: 32-33.
11. Pai PR, Shah HK, Samsi AB. **Post-partum pancreatitis.** J Postgrad Med 1993; 39:93-4.
12. Legro R, Laifer S. **First trimester pancreatitis: maternal and neonatal outcome.** J Reprod Med 1995; 40:689-695.

Article received on: 31/10/2012

Accepted for Publication: 10/10/2012

Received after proof reading: 08/10/2012

Correspondence Address:

Dr. Shama Chaudhry
A-13 Shamim Apartments Ayesha Manzil
F. B. Area Block-10, Karachi
chshama@yahoo.com

Article Citation:

Chaudhry S, Hussain R. Case report of acute pancreatitis in pregnancy, a rare presentation. Professional Med J Oct 2012;19(5):747-750.