

MULLERIAN DUCT ANOMALIES; UNICORNUATE UTERUS WITH OR WITHOUT RUDIMENTARY HORN PREGNANCY

ORIGINAL
PROF-1925

DR. SARWAT ARA

MCPS, FCPS
Assistant Professor,
Gynecology & Obstetrics,
PMC Allied Hospital, Faisalabad.

DR. TASNEEM ALI

MBBS, FCPS
Senior Registrar
Gynecology & Obstetrics,
Allied Hospital, Faisalabad

ABSTRACT... Background: Müllerian duct anomalies (MDAs) occur with an incidence estimated to be 4.3%. A unicornuate uterus with or without a rudimentary horn; is a type of mullerian duct abnormality with a frequency of 0.4%. Rudimentary horn pregnancies are rare obstetric complication and may cause difficulty in diagnosis and subsequent management. **Objective:** To alert about Mullerian duct abnormalities especially unicornuate uterus with or without rudimentary horn. **Design:** Case series. **Setting:** Study was conducted in the department of Gynecology and obstetrics unit1, Allied Hospital Faisalabad. **Duration of study:** Cases detected during September 2006-October 2011. **Subjects and methods:** All admitted cases of MDA whether obstetric or gynecological were included. We calculated cases of unicornuate Uterus with or without rudimentary horn, also included cases of rudimentary horn pregnancy with or without rupture. **Results:** There were 120 cases of MDA out of which 8 (6.6%) were of unicornuate uterus. Out of 8 unicornuate uteri, 7/8 (87.5%) were with rudimentary horn and 1/8 (12.5%) without rudimentary horn. Left rudimentary horn in 4/8 patient (50%), right in 3/8 (37.5%) without horn 1/8 (12.5%). Out of 7 rudimentary horn 1/7 gynecologic and 6/7 were obstetric, 5/7 (71.42%) ruptured in second trimester, and 1/7 (14.28%) term pregnancy. In 1/7 (14.28%) horn not removed because tubal ligation was done. Unilateral renal agenesis was present in 3/8 patient (37.5%). Ovaries were preserved in 3/7 patients (66%). **Conclusions:** There must be high index of suspicion for Mullerian duct abnormalities especially rudimentary horn for achieving good success in diagnosis and management.

Key words: Mullerian duct abnormalities, Unicornuate uterus, Rudimentary horn.

INTRODUCTION

Müllerian duct anomalies are embryological consequence from non development or non fusion of the Müllerian ducts resulting in absent uterus & vagina, unicornuate uterus, didelphys, bicornuate uterus, septate and arcuate uterus¹. A unicornuate uterus is a type of MDA, which is smaller than a normal uterus. 65% of women have a rudimentary horn which may or may not be connected with the rest of the uterus and vagina². Pregnancy can occur in unicornuate uterus but there is risk of spontaneous abortion and premature labor because of the abnormal shape of the uterus itself and compromised blood flow to the uterus and placenta. A unicornuate uterus with a rudimentary horn may cause many gynecological and obstetrical complications. Pregnancy in a rudimentary uterine horn is not easy to diagnose in the antenatal period. Such pregnancies hardly ever reach viability and frequently result in rupture of the horn^{3,4}. The average duration of gestation has been estimated 21.5 weeks. Live birth has occurred in only 12% of reported cases since 1946⁵.

SUBJECTS AND METHODS

All admitted cases of MDA whether obstetric or

gynecological were included. We calculated cases of unicornuate Uterus with or without rudimentary horn, also included cases of rudimentary horn pregnancy with or without rupture.

RESULTS

There were 120 cases of MDA out of which 8 (6.6%) were of unicornuate uterus. Out of 8 unicornuate uteri, 7/8 (87.5%) were with rudimentary horn and 1/8 (12.5%) without rudimentary horn (Table-I). Left rudimentary horn in 4/8 patient (50%), right in 3/8 (37.5%) without horn 1/8 (12.5%). Out of 7 rudimentary horn 1/7 gynecologic and 6/7 were obstetric (Table-II). Left rudimentary horn in 4/8 patient (50%), right in 3/8 (37.5%) without horn 1/8 (12.5%) (Table-III). We got 5/7 (71.42%) ruptured in second trimester, and 1/7 (14.28%) term pregnancy. About the fate 6/7 (85.7%) excised while 1/7 (14.28%) horn not removed because tubal ligation was done. Recurrent or spontaneous miscarriages and pre term deliveries present in 6/8 (62.5%) cases (Table-I). Unilateral renal agenesis was present in 3/8 patient (37.5%). Ovaries were preserved in 3/7 patients (66%) (Table-IV).

Table-I. Summary of eight cases of unicornuate uterus with or without rudimentary horn pregnancy

Age	Parity	Duration of gestation	Emergency or OPD Admission	Clinical Features	USG Findings	Intra Operative Findings
27	G ₃ P ₀ A ₂	19-20 wks	OPD Admission	Pale, breathless, palpitations.	1. Abdominal pregnancy 2. Cornual 3. Pregnancy in bicornuate uterus	Ruptured right horn
36	G ₇ P ₃ A ₃	22 wks	Emergency	Shock, tense tender abdomen	Suspicion of ruptured uterus	Ruptured left horn
29	G ₄ P ₂ A ₁	23-24 wks	OPD Admission	Pregnancy induced hypertension	Normal intra uterine pregnancy	Ruptured left horn
30	G ₆ P ₃ A ₂	16 wks	Emergency	Shock, tense tender abdomen	Right adnexal mass	Ruptured right horn
26	G ₅ P ₂ A ₂	40 wks	OPD Admission	Electives for placenta previa with B.T.L	Pregnancy in bicornuate uterus	Pregnancy in unicornuate uterus with right rudimentary
14	Unmarried	-	OPD Admission	Cyclical severe dysmenorrhoea	Uterus didelphus	Unicornuate uterus with left rudimentary horn filled with blood
24	G ₂ P ₁	term	OPD Admission	For elective caesarean section	Placenta previa with fibroid	An alive baby 2.5 kg in left rudimentary horn, non pregnant unicornuate uterus
26	P ₂	Post LSCS	Emergency	Primary PPH	Intraperitoneal hemorrhage (hmg)	Unicornuate uterus with retained placenta increta without horn

Table-II. Pregnancy in unicornuate uterus or rudimentary horn

Site of pregnancy	Number	%age
In rudimentary horn	5	62.5%
Unicornuate	2	25%
With out pregnancy (gynecologic)	1	12.5%
Total	8	100%

Table-III. Location of rudimentary horn with unicornuate uterus

Location of horn	Number	%age
Left	4	50%
Right	3	37.5%
Without horn	1	12.5%
Total	8	100%

CASE 1

A 27 Years old married for 9 year G₃P₀A₂ was admitted through outpatient department as a case of secondary abdominal pregnancy diagnosed at 16 weeks from a private clinic. She had 2 spontaneous abortions at fourth month. When admitted she was pale, breathless with pulse rate 120/min. and having irregular missed beats.

Her blood pressure was 100/70 mm Hg. On cardiovascular examination she had pan systolic murmur. Abdominal examination showed a fundal height of 16 weeks slightly to the right of mid line. Abdomen was soft & non-tender. On examination by cardiologist she was diagnosed to have atrial fibrillation. She was shifted to the cardiology department where she was diagnosed as

Table-IV. Findings of renal anomalies with unicornuate uterus

Renal anomaly	Number of patients	%age
Present	3	37.5%
Absent	5	62.5%
Total	8	100%

a case of rheumatic heart disease having mitral stenosis with regurgitation. During her stay in hospital she was evaluated for her obstetric diagnosis by radiology department where ultrasound and MRI were done. Their report revealed a viable pregnancy of 16-17 weeks in bicornuate uterus. It was decided to allow the pregnancy to proceed under strict observation. From cardiology department patient was referred to Faisalabad Institute of Cardiology for further management. After three weeks of initial admission patient was readmitted in labor ward in a state of shock. In labor ward her emergency ultrasound revealed an empty uterus on left side having endometrial echoes while on right side there was a dead fetus corresponding to 19-20 weeks of gestation. Moderate amount of free fluid was seen in peritoneal cavity. We planned emergency laparotomy which confirmed unicornuate uterus with one tube and ovary while right ovary and tube were attached to rudimentary horn having dead fetus of 20 weeks size. The horn was ruptured at the funds from where fetus & placenta were delivered. Horn was attached to unicornuate uterus with a fibrous band which was excised. Horn had no connection with uterus. Post operative recovery was uneventful. Post op IVU confirmed both renal systems normal. Patient was discharged on seventh post op day.

CASE 2

A 36 years old $G_7P_3A_3$ presented in emergency in a state of shock with history of gestational amenorrhea of 24 weeks with acute abdominal pain for the last 6 hours she had previous 2 spontaneous and 1 induced miscarriages. On abdominal examination abdomen was tense, tender and distended. Emergency ultra sonogram revealed a 22 weeks dead fetus with free-fluid in peritoneal cavity. Her Hb. was 7.4g. Rest of investigations was normal. Pelvic examination could not

be conclusive because of extreme abdominal tenderness. A provisional diagnosis of ruptured uterus was made. On laparotomy 3.5 to 4 liter blood was present with ruptured left rudimentary horn at fundus with right side unicornuate uterus having 1 tube and ovary attached with it while other tube and ovary were attached with rudimentary horn. 500g fetus with intact sac found in peritoneal cavity. Right horn along with fallopian tube was removed from main uterine body and ovary preserved without any difficulty. Right tubal ligation was done. Post op recovery was uneventful. No abnormality detected on IVU. Patient was discharged in good health.

CASE 3

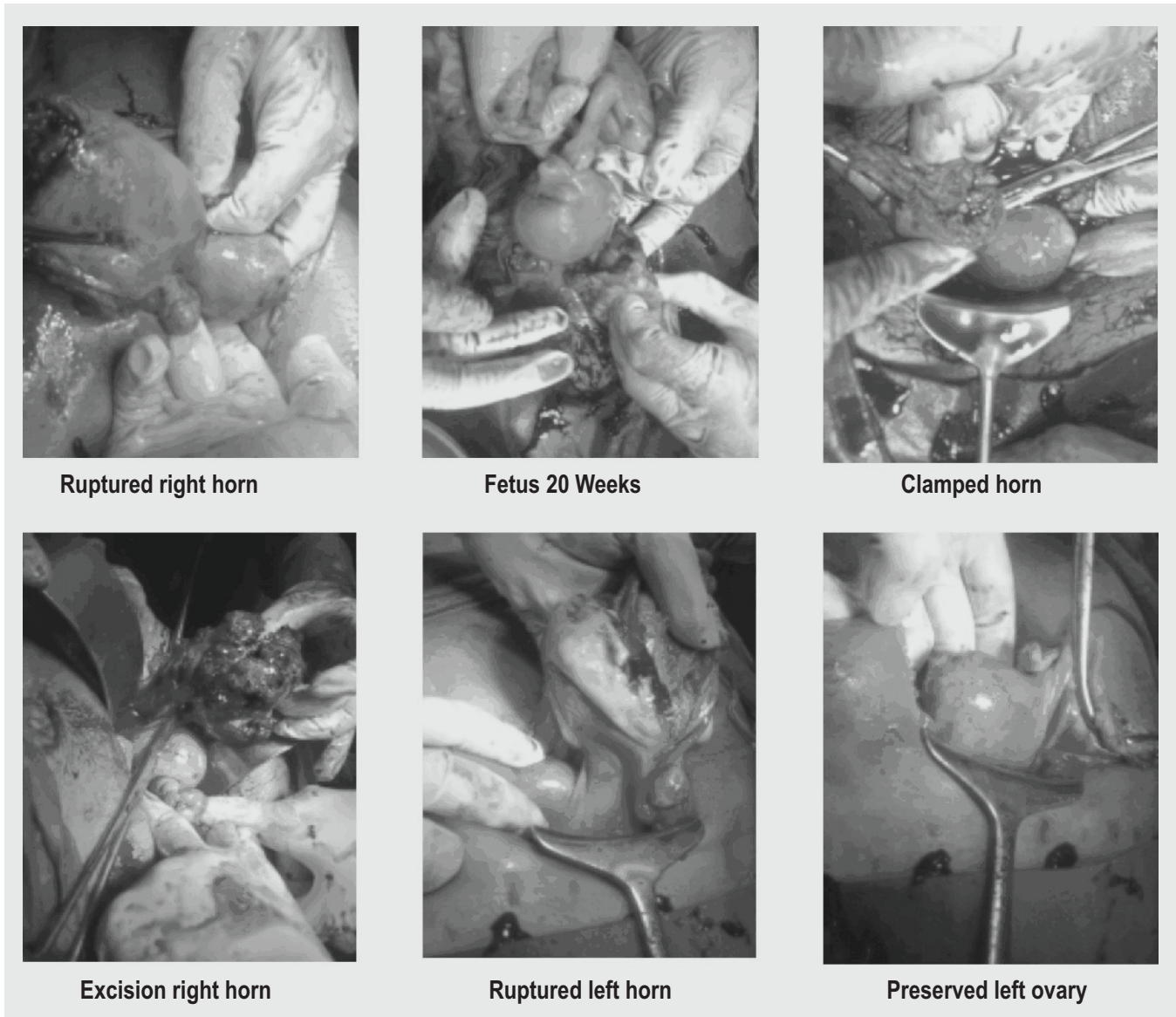
A 29 years $G_4P_2A_1$ with 2 pre term deliveries at 32 weeks and 1 spontaneous miscarriage presented at 24 weeks with severe pregnancy induced hypertension in out patient department and admitted for evaluation of blood pressure. On ultra sound examination she was having a gestation corresponding to 23-24 weeks with normal liquor and fetal movement. During her stay in hospital she went into sudden collapse; ultrasound examination confirmed intra peritoneal fluid with uterus and endometrial echoes on left side so a suspicion of ruptured rudimentary horn arose. Immediate laparotomy confirmed our suspicion. Left ruptured horn through which fetus was extruding was removed along with left tube while left ovary was preserved. Intravenous urogram confirmed left kidney to be absent. Patient was discharged home uneventful.

CASE 4

A 30 year married since 8 years $G_6P_3A_2$ at 4 months of gestation received in shock, with urine report for pregnancy test positive. Abdomen was distended. USG revealed an empty uterus with right adnexal mass and fetal echoes in peritoneal cavity, having free fluid in peritoneal cavity. Intraoperative findings revealed 3.5 litter blood in abdominal cavity with right-sided ruptured rudimentary horn with a fetus weighing 250g in peritoneal cavity. Right horn with tube and right ovary removed.

CASE 5

A 26 years G_3P_2 , received as a diagnosed case of bicornuate uterus with previous normal vaginal deliveries. Lower segment cesarean section was done



Ruptured right horn

Fetus 20 Weeks

Clamped horn

Excision right horn

Ruptured left horn

Preserved left ovary

for placenta previa. It was found to be unicornuate uterus with right rudimentary horn. BTL was done. Post operative IVU confirmed absent right kidney.

CASE 6

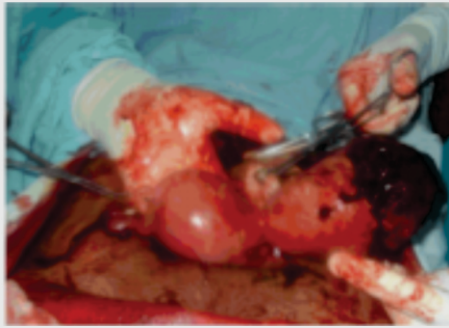A 14 years student of 9th class with history of menarche 1 year ago, presented with severe painful menstruation. IVU showed left renal agenesis. MRI confirmed uterus didelphys with non communicating left system having hematometra and haematocolpos. Laparotomy confirmed unicornuate uterus with non-communicating left horn with blind ended cavity. Horn filled with chocolate colored fluid, excised with difficulty.

CASE 7

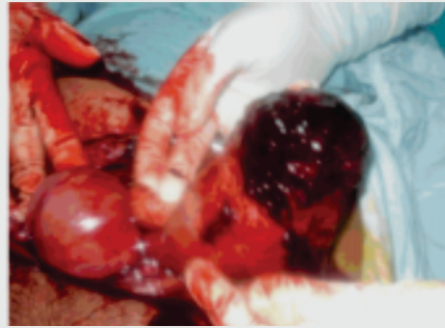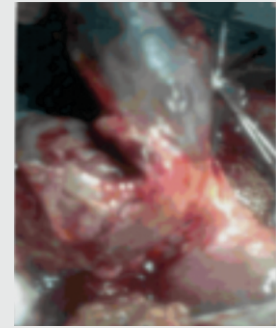
A 24 years G_2P_1 married since 3 years admitted for elective section with diagnosed placenta previa major degree with fibroid uterus. Intra operatively it was term pregnancy having 2.5kg alive baby in left rudimentary horn with normal non-pregnant unicornuate uterus. After delivering the fetus, rudimentary horn along with left tube and ovary was excised. Post operative IVU was normal.

CASE 8

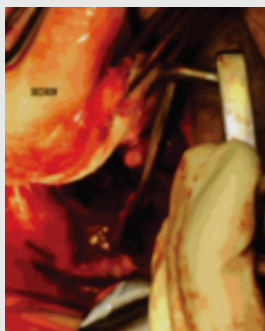
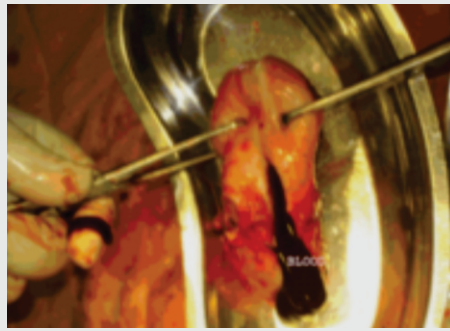
A 26 years P_2 presented 6 hours after lower segment caesarian section with primary PPH. On examination



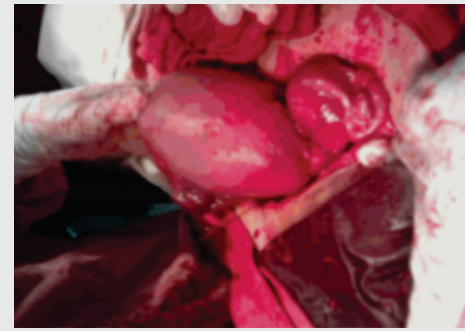
Excision right horn

Excision right horn
preserving both ovaries

Term pregnancy In horn

Cornuate Uterus
Communicating
left horn

Horn filled with blood

Unicornuate uterus
with right horn

fundal height was 32 weeks, on laparotomy unicornuate uterus with placenta percreta without rudimentary horn was found. Peripartum hysterectomy of unicornuate uterus was done. Post operative IVU was normal.

DISCUSSION

In women with a history of adverse pregnancy outcome, approximate 5 to 10% have MDA. Unicornuate uteri constitute about 10% of the total number of diagnosed congenital uterine anomalies². In current study we have 6.6% of unicornuate uteri incidence. The true incidence of rudimentary horn pregnancy is not easy to calculate but it is estimated to occur in 1/76,000 to 1/150,000 pregnancies^{4,6}.

A unicornuate uterus with rudimentary horn is a result of abnormal Mullerian duct development. Unicornuate uterus with rudimentary horn is of grave consequences. A serious notice of symptomatology of patients must be taken in to account. Considering different obstetric

presentations associated with unicornuate uteri came out to be: miscarriage in 37%, preterm birth in 16%, and term birth in only 45%². In current study recurrent or spontaneous miscarriages and pre term deliveries are present in 62.5% cases. Unicornuate uterus may not be detected until later in life as we can see in our many patients.

In mentioned study we encountered 85.7% (6/7) obstetric and 14.28% (1/7) gynecologic rudimentary horns. It is in contrast to 42.62% (156/366) Obstetric and 57.37% (210/366) gynecologic presented from 1966 to 2003 in an article by Jayasinghe⁷. This difference might be because of limited number of cases in our study.

No doubt rudimentary horn pregnancy is a rare occurrence but gains paramount significance because of its clinical effects prior to and after pregnancy. In unmarried girls it is associated with severe dysmenorrhoea whenever there is horn with functioning endometrium as happened in case no 6; after marriage

patients may present to gynecology department with dyspareunia, dysmenorrhoea, infertility, recurrent miscarriage and preterm labor⁸. It is also associated with intrauterine growth retardation, intraperitoneal hemorrhage and uterine rupture⁹.

Ultrasonography has only 26% sensitivity^{7,12} in diagnosing MDA including rudimentary horns. It is not encouraging result in diagnosing MDA. We suspected MDA on clinical grounds and tried to confirm sub type by MRI especially in case 1 and 6 but again MRI did not assist us although MRI was considered a significant tool in diagnosis of MDA including rudimentary horn by Marten¹ on basis of 100% result in his study carried out on 4 patients.

In present study 85.71 % (6/7) rudimentary horns were of non communicating variety similar to 92% in one study⁷. Pregnancy in the rudimentary horn arises either from a small communication with the uterine cavity or by transperitoneal migration of the fertilized ovum or sperm from the contra lateral side³.

If pregnancy occurs in rudimentary horn, the usual outcome is rupture in second trimester in 90% of cases¹ with intra peritoneal bleeding and shock. We encountered 80% rupture in this case series. Keeping in mind the diagnostic dilemma prior to rupture we must be familiar with a bicornuate uterus, interstitial pregnancy and abdominal pregnancy which are common sonographic misdiagnoses perplexed with rudimentary horn pregnancy⁵.

By reviewing the literature, a light is shed on the differential diagnosis among the above conditions. A tubal or abdominal pregnancy will not project a ring of myometrium surrounding the gestational sac so making the diagnosis easier. On the other hand differential diagnosis of pregnancy in corneal region, bicornuate uterus and rudimentary horn may be much difficult¹¹. However an extra uterine gestation with placenta surrounded by a thin layer of myometrium failing to demonstrate communication between the single cervix and the gestational sac will support the diagnosis of rudimentary horn pregnancy.

It is suggested by the most that immediate surgery should be performed whenever a diagnosis of pregnancy in a rudimentary horn is made even if unruptured⁷ but the fact is that cases of late and incorrect diagnosis leading to uterine rupture have been reported over and over again in the recent literature¹², similar to our case 7 where term pregnancy in rudimentary horn was diagnosed as placenta previa with fibroid which was unicornuate uterus. This diagnostic challenge can be dealt if the following diagnostic criteria described in literature¹² are taken in to account:

Pseudopattern of an asymmetrical bicornuate uterus.
Absent visual continuity between the cervical canal and the lumen of the pregnant horn and the presence of myometrial tissue surrounding the gestational sac.

It was also further concluded in the Tsafir study¹³ that MRI can be used to confirm the diagnosis before rupture and invasive procedure.

In the mentioned study 37.5% patients with unilateral renal agenesis which in review of literature appeared to be 15-40%^{7,14,15} including ectopic kidney, renal agenesis, double renal pelvis, horseshoe kidneys and unilateral medullary sponge kidney¹³.

CONCLUSIONS

Sonologist and obstetrician must have high index of suspicion for Müllerian duct abnormalities particularly rudimentary horn so that surgery must be opted prior to rupture. Urinary tract must always be explored for any abnormality.

Copyright© 07 Aug, 2012.

REFERENCES

1. Marten K, Vosshenrich R, Funke M, Obenauer S, Baum F, Grabbe E. **MRI in the evaluation of müllerian duct anomalies**. Clin Imaging 2003; 27(5):346-50.
2. Danielson K. **Unicornuate Uterus - What It Is and How It Affects Miscarriage / Pregnancy Risks**. [Internet] 2010-01-08 Available from: <http://miscarriage.about.com/od/problemswiththeuterus/p/unicornuate.htm>.
3. O'Leary JL, O'Leary JA. **Rudimentary horn pregnancy**. Obstet Gynecol 1963; 22:371-375.

4. Nahum GG. **Rudimentary uterine horn pregnancy: a case report on surviving twins delivered 8 days apart.** J Reprod Med 1997; 42:525–532.
5. Sutkin G, Jazayeri A. **Diagnosis of a rudimentary uterine horn in pregnancy.** J Ultrasound Med 2003; 22: 985–988
6. Ural SH, Artal R. **Third-trimester rudimentary horn pregnancy, a case report.** J Reprod Med 1998; 37: 919-921.
7. Jayasinghe Y, Rene A, Stalewski H, Grover S. **The presentation and early diagnosis of the rudimentary uterine horn.** Obstet Gynecol 2005; 105:1456-67.
8. Tufail A, Hashmi HA. **Ruptured ectopic pregnancy in rudimentary horn of the uterus.** Coll Physicians Surge Pak 2007; 17 (2): 105-106.
9. Jin Woo Shin, Hai Joong Kim. **Case of live birth in a non communicating Rudimentary horn.** J Ob& Gyn research 2005; 31(4): 329-331.
10. Liu MM. **Unicornuate uterus with rudimentary horn.** Int J Gynaecol Obstet 1994; 44:149-53.
11. Kriplani A, Relan S, Mittal S, Buckshee K. **Pre-rupture diagnosis and management of rudimentary horn pregnancy in the first trimester.** Eur J Obstet Gynecol Reprod Biol 1995; 58:203–205
12. Buntugu KA, Ntummy MY, Ameh EO, Obed SA. **Rudimentary Horn Pregnancy: Pre-Rupture Diagnosis and Management.** Ghana Med J 2008; 42(2): 92–94.
13. Tsafir A, Rojansky N, Sela HY, Gomori JM, Nadjarm M. **Rudimentary horn pregnancy: first trimester pre rupture sonographic diagnosis and Confirmation by magnetic resonance imaging.** Ultrasound Med 2005; 24(2):219-23.
14. Fedele L, Bianchi S, Agnoli B, Tozzi L. **Urinary tract anomalies associated with unicornuate uterus.** J Urol 1996; 155(3):847-8.
15. Heinonen PK. **Clinical implications of the unicornuate uterus with rudimentary horn.** Int J Gynecol Obstet 1983; 21(2): 145-50.

Article received on: 10/02/2012

Accepted for Publication: 07/08/2012

Received after proof reading: 08/10/2012

Correspondence Address:

Dr. Sarwat Ara
92-Faisal Gardens,
West Canal Road, Faisalabad.
sarwatara_fcps@hotmail.com

Article Citation:

Ara S, Ali T. Mullerian duct anomalies; unicornuate uterus with or without rudimentary horn pregnancy. Professional Med J Oct 2012;19(5): 723-729.

PREVIOUS RELATED STUDIES

Tasnim Tahira. MULLERIAN DUCT ANOMALIES; PRESENTATION AND REPRODUCTIVE OUTCOME (Original) Prof Med Jour 17(4) 676-678 Oct, Nov, Dec 2010.