

LAPAROSCOPIC CHOLECYSTECTOMY

FATE OF SPILLED BILE WITH GALLSTONES DURING LAPROSCOPIC CHOLECYSTECTOMY

ORIGINAL
PROF-1781

DR. MUHAMMAD RAHIM BHURGRI

Assistant Professor
Surgical department
Muhammad Medical College, Mirpurkhas

DR. SYED RAZI MUHAMMAD

Professor
Surgical department
Muhammad Medical College, Mirpurkhas

DR. MUHAMMAD JAWAID RAJPUT

Professor
Surgical department
Muhammad Medical College, Mirpurkhas

ABSTRACT... There is a continued debate on fate of spilled bile with gallstones during laparoscopic cholecystectomy, so we felt that the outcome needs further evaluation in detail. Although laparoscopic cholecystectomy become increasingly popular, but it is associated with a slightly higher chances of injury to biliary tree and perforation of gallbladder with spillage of bile only or with gallstones. **Objectives:** (1) To evaluate fate of spilled bile with gallstones during laparoscopic cholecystectomy. (2) To assess various possible outcomes. (3) Suggestions to prevent these and their management. **Design of study:** Prospective study. **Setting:** Surgical unit of Muhammad Medical College Hospital, Mirpurkhas. **Period:** February 2008 to April 2011. **Data source:** Total 100 patients who underwent elective laparoscopic cholecystectomy were included. Age, sex, duration of operation, operative findings, duration of hospital stay and post-op complications were recorded in proforma and analyzed on SSP version 10. **Material and method:** The patients who underwent cholecystectomy, and had intra-operative spillage were short-listed, included in this study and followed up. Short-term follow-up was based on OPD visits for 2 to 3 weeks postoperatively, and long-term follow-up was achieved by regular OPD visits or telephone conversation in patients at a mean of 1.4 years (range 2 to 39 months). All minor or major complications were recorded in preformed proforma. Results: A total of 100 patients underwent laparoscopic cholecystectomy. Among the patients who underwent elective laparoscopic cholecystectomy the incidence of iatrogenic perforation of the gallbladder is around 40%, of whom about 22% had spillage of only bile and 18% in whom spillage of both bile and gallstones. **Conclusions:** It is concluded that laparoscopic cholecystectomy with gall bladder perforation along and spillage of bile and stones took longer operative time than intact gall bladder. We suggest that attempts should be made to irrigate the operative field to evacuate spilled bile and to retrieve all gallstones spilled during the operative procedure. In our study, we revealed that no harm is caused by retained gallstones during laparoscopic cholecystectomy after long term followup by evaluation.

Key words: Laparoscopic Cholecystectomy, Spilled Bile, Gallstones

INTRODUCTION

Laparoscopic cholecystectomy is now the gold standard for the treatment of symptomatic gallstone disease. Although the overall complication rate is less than the traditional open approach, there are two operative complications that occur with greater frequency during laparoscopy. One is bile duct injury or bile leakage, and the other appears to be late infection due to dropped gallstones^{1,2}. During laparoscopic cholecystectomy, because of perforation of the gallbladder, the rate of bile leak and loss of gallstones into the peritoneum has been reported to be between 3% and 33%^{3,4} as compared to our study which is 40%..

During laparoscopic cholecystectomy, usually gallbladder gets perforated while gallbladder dissection from liver bed or while extracting through the port or during holding for retraction of gallbladder. Spillage of

gallbladder contents is thought to be relatively innocuous.

Although rarely clinically significant, intra-peritoneal gallstone spillage may cause localized or systemic infection, inflammation, fibrosis, adhesion, cutaneous sinuses, fistula, small bowel obstruction, generalized septicemia, empyema, and intra-abdominal and extra abdominal abscess^{5,6}. Most surgeons believe that free intra-peritoneal gallstones are harmless and therefore not a justification for conversion to laparotomy⁷ even if a large number is left in situ.

Nevertheless, recognition of this unusual entity is important because the clinical presentation can be confusing and the diagnosis significantly delayed^{8,9}. Bile leakage can be diagnosed soon after operation, but intra-peritoneal gallstone spillage can be manifested months

to years after operation, and have a confusing preservation, leading to further diagnostic examinations. Most such diagnostic tests are time consuming and expensive. Because gallstone spillage can have long-term unwanted consequences, conversion to laparotomy as an instant management tool is one of the topics under discussion in laparoscopic cholecystectomy.

In this study, we discuss the option of not converting to laparotomy after intra-peritoneal gallstone spillage as an acceptable approach.

MATERIAL AND METHODS

Among the patients who underwent cholecystectomy, patients who had intra-operative spillage were short listed, included in this study and followed up. Short-term follow-up was based on a OPD visit 2 to 3 weeks postoperatively, and long-term follow-up was achieved by regular OPD visits or telephone conversation at a mean of 1.4 years (range 2 to 36 months).

Operative procedure

A four-trocar technique with a 0-degree angled laparoscopic video camera was used. Dissection of the gallbladder was performed using a combination of electro-cautery and blunt dissection with fine graspers, and the cystic artery and cystic duct were ligated with titanium clips. The gallbladder was removed through epigastric port. When perforation of the gallbladder occurred, attempts were made to retrieve all spilled stones, and the peritoneal cavity was irrigated with saline solution to evacuate the spilled bile. Patients typically received one preoperative and one postoperative dose of antibiotic, most commonly a cephalosporin.

RESULTS

Among the patients who underwent elective laparoscopic cholecystectomy the incidence of iatrogenic perforation of the gallbladder is 40%, of whom about 22% had spillage of only bile and 18% in whom spillage of both bile and gallstones. The mean age of the perforated gallbladder group was greater than that of the intact group (46 years vs 40 years; $P < 0.001$), Adhesions between the gallbladder and the omentum conferred a greater risk of gallbladder perforation (60% vs. 20%; $P <$

0.001). Iatrogenic perforation of the gallbladder was higher in the first year (2008) of our experience with laparoscopic cholecystectomy (60%), but the incidence decreased progressively each year thereafter to 20% in 2010. Perforation of the gallbladder occurred during dissection of the gallbladder from the liver in 26% of patients, during extraction through the abdominal wall in 10% and as a result of intra-operative retraction in 4%. The operative time for patients in the perforated group was slightly longer (100 minutes vs. 46 minutes; $P < 0.001$) but of little clinical significance. Mean hospital stay is longer in case of perforated group ranging from 2-3 days where as less than 2 days in other group. In our study, we revealed that no harm caused by retained gallstones during laparoscopic cholecystectomy after long term follow-up by evaluation.

Table-I. Results and observations

	Age (Years)	Omental Adhesion	Duration of Surgery (Minutes)	Hospital Stay (Days)
Spill group	46	Present	Mean 100 minutes	2-3 days
Non-spill group	40	Not Present	Mean 46 minutes	< 2 days

Table-II. Learning curve affect on laparoscopic

Year	Total patient	Bile leakage	Bile + Stone leakage
2008	25	8 (32%)	7 (28%)
2009	30	7 (23.33%)	5 (16.66%)
2010	30	7 (23.33%)	3 (10%)
2011	15	2 (13.33%)	1 (6.66%)
	100	24%	16%

DISCUSSION

Laparoscopic cholecystectomy is gold standard treatment for symptomatic cholelithiasis¹⁰. The procedure, however, is not without complications, most notably a higher incidence of biliary tract injuries compared to open cholecystectomy¹¹. There are case reports of gallstones lost at the time of surgery

subsequently causing intra-abdominal abscesses^{11,12} empyema,^{13,14} abdominal wall abscesses,^{15,16} cutaneous sinus tracts¹⁷ and bladder fistulas¹⁸. It remains unclear whether stone spillage should be considered an indication for conversion to an open cholecystectomy¹⁹. Although these complications appear to be rare, their actual incidences are unknown.

To determine the potential consequence of spilled gallstones in the abdominal cavity a number of animal studies have been undertaken. Welch et al²⁰ and Cohen et al²¹ conclude that free intra-peritoneal gallstones are harmless and thus do not warrant exploratory laparotomy. Johnson et al²² found that leakage of bile in combination with gallstones was associated with a significant risk of postoperative adhesion formation and possible Intraabdominal abscesses. Gurleyik et al²⁴ and Johnston S et al²⁵ concluded that chemical composition plays a major role in the fate of intra-abdominal gallstones and that patients who have retained intra-abdominal pigmented stones should be followed closely because of the high prevalence of complications.

Many clinical studies have been undertaken to determine the potential consequence of spilled gallstones in the abdominal cavity. Soper and Dunnegan²⁶ and Schafer et al²⁷, who analyzed 10,174 laparoscopic cholecystectomies performed at 82 surgical institutions over a 3-year period, their findings showed that the mortality rate and the incidence of serious complications of retained gallstones are extremely low. They advised surgeons against converting laparoscopic cholecystectomy to an open procedure in case of spillage. These authors emphasized the need for removal of as many calculi as possible during laparoscopy. They also noted that percutaneous drainage of intra-abdominal abscesses in most of their patients was ineffective if the inciting gallstones were not removed^{28,29}.

Almost all surgical approaches have a potential of unwanted or unexpected outcome. The main goal for all surgeons should be to manage their own complications with minimal harm to the patient physically and psychologically³⁰. From this point of view, a complication can be accepted as an unwanted consequence of a

surgical approach. We recommend these steps during laparoscopic cholecystectomy in case of spillage

- Informed consent from patient and family preoperatively and mentioning that dropped stones are common depending on the size of stones and condition of the gallbladder wall and liver bed.
- Every effort should be made to retrieve the gallstones and the peritoneum should be irrigated with copious saline, in case of spillage.
- There is no need for converting the laparoscopic procedure to a laparotomy for spilled stones, but it should be essential to document spilled stones in the operation notes.
- All possible but unlikely consequences of the spillage should be informed to the patient.
- The surgeon should have long term follow up of these patients unlike other routine cholecystectomy, as there is possibility of delayed complications.
- In view of confusing delayed clinical presentation during post-op period, surgeon should be alert to rule out possible complications due to spillage and manage them accordingly.

CONCLUSIONS

The outcome as serious complications after intra-operative spillage of gallbladder contents during laparoscopic cholecystectomy is low. The surgeon should inform the patient preoperatively about the possibility of gallstone spillage. If spillage does occur, the patient should be informed postoperatively of the event. Such patients should be kept under close control to avoid wastage time and money for unnecessary examinations, as well as the psychological trauma associated with wrong diagnosis like malignancy as spilled gallstone may mimic malignancy in years to come. Surgeons should not hesitate to record the events and inform the patient about the spillage of gallstones and possible consequences. If gallstones are knowingly spilled within the abdominal cavity, every attempt should be made to remove all gallstones. Because infective complications are rare following gallbladder perforation, conversion to laparotomy is not routinely indicated.

ACKNOWLEDGMENTS

We wish to thank Drs. Muhammad Arif, Rahmatullah Soomro, Zubair Ahmed and Mashooque Ali for their help in the study particularly in the collection and processing of data.

Copyright© 06 July, 2011.

REFERENCES

1. Horton M, Florence MG. **Unusual abscess patterns following dropped gallstones during laparoscopic cholecystectomy.** Am. J. Surg. 1998; 175:375-378.
2. Fitzgibbons RJ, Annibaldi R, Litke BS. **Gallbladder and gallstone removal, open versus closed laparoscopy, and pneumoperitoneum.** Am. J. Surg. 1993; 165:497-504.
3. Siewert JR, Feussner H, Scherer MA, et al. **Fehler und Gefahren der Laparoscopic vs. open Cholecystectomy** Chirurg 1993; 64:221-229.
4. Zorluoglu A, Ozguc H, Yilmazlar T, et al. **Is it necessary to retrieve dropped gallstones during laparoscopic cholecystectomy?** Surg. Endosc. 1997;11:64-66.
5. Brockmann JG, Kocher T, Senninger NJ, Schürmann GM. **Complications due to gallstones lost during laparoscopic cholecystectomy.** Surg Endosc. 2002;16:1226-32.
6. Memon MA, Deek RK, Mafii TR, et al. **The outcome of unretrieved gallstones in the peritoneal cavity during laparoscopic cholecystectomy.** Surg. Endosc. 1999; 13:848-857.
7. Bennett AA, Gilkeson RC, Haaga JR, et al. **Complication of "dropped" gallstones after laparoscopic cholecystectomy: technical consideration and imaging findings.** Abdominal Imaging 2000; 25:190-193.
8. Hawasali A, Schroder D, Rizzo J, Thusay M, Takach T, Thao U et al. **Remote complications of spilled gallstones during laparoscopic cholecystectomy: causes, prevention and management.** J Laparoendosc Adv Surg Tech. 2002;12:123-27.
9. Tschmelitsch J, Glaser K, Klingler A, et al. **Late complication caused by stone spillage during laparoscopic cholecystectomy [letter].** Lancet 1993; 342:369.
10. Gouma DJ, Go PM. **Bile duct injury during laparoscopic and conventional cholecystectomy.** J Am Coll Surg 1994; 178:229-233.
11. Leslie KA, Rankin RN, Duff JH. **Lost gallstones during laparoscopic cholecystectomy: Are they really benign?** Can J Surg 1994; 37:240-242.
12. Dreznik Z, Soper NJ. **Trocar site abscess due to spilled gallstones: An unusual late complication of laparoscopic cholecystectomy.** Surg Laparosc Endosc 1993; 3:223-224.
13. Wilton PB, Andy OJ Jr, Peters JJ, et al. **Laparoscopic cholecystectomy. Leave no (spilled) stone unturned [see comments].** Surg Endosc 1993; 7:537-538.
14. Woodfield JC, Rodgers M, Windsor JA. **Peritoneal gallstones following laparoscopic cholecystectomy. Incidence, complications, and management.** Surg Endosc. 2004;18:1200-07.
15. Eldar S, Schein M. **Discharge of a gallstone 1 year after laparoscopic Cholecystectomy (letter).** Arch Surg 1994; 129: 1105.
16. Catarci M, Zaraca F, Scaccia M, et al. **Lost intraperitoneal stones after laparoscopic cholecystectomy: Harmless sequela or reason for reoperation?** Surg Laparosc Endosc 1993; 3:318-322.
17. Coadac RG, Lakra Yp. **Abdominal wall sinus tract secondary to gallstones: A complication of laparoscopic cholecystectomy [review].** J Laparoendosc Surg 1993; 3:509-511.
18. Donohue JH, Grant CS, Farnell MB, et al. **Laparoscopic Cholecystectomy-Operative technique.** Mayo Clin Proc 1992; 67:441-448.
19. Zulfikaroglu B, Ozalp N, Ozmen M, Koc M. **What happens to the lost gallstone during laparoscopic cholecystectomy.** Surg Endosc. 2003;17:158.
20. Laufer JM, Krahenbuhl L, Baer HU, et al. **Clinical manifestations of lost gallstones after laparoscopic cholecystectomy: a case report with review of the literature.** Surg. Laparosc. 1997; 7:103-112.
21. Welch N, Hinder RA, Fitzgibbons RJ, et al. **Gallstones in the peritoneal cavity: a clinical and experimental study.** Surg. Laparosc. Endosc. 1991; 1:246-247.
22. Cohen RV, Pereira PR, Barros MV, et al. **Is the retrieval of lost Peritoneal gallstones worthwhile?** Surg. Endosc. 1994; 8:1360.

23. Johnston S, O'Malley K, McEntee G, et al. **The need to retrieve the dropped stone during laparoscopic cholecystectomy.** Am. J. Surg. 1994; 167:608-610.
24. Gurleyik E, Gurleyik G, Yucel O, et al. **Does chemical composition have an influence on the fate of intraperitoneal gallstone in rat?** Surg. Laparosc. Endosc. 1998; 8:113-116.
25. Johnston S, O'Malley K, McEntee G, et al. **The need to retrieve the dropped stone during laparoscopic cholecystectomy [see comments].** Am J Surg 1994; 167:608-610.
26. Soper NJ, Dunnegan DL. **Does intraoperative gallbladder perforation influence the early outcome of laparoscopic cholecystectomy?** Surg. Laparosc. Endosc. 1991; 1:156-161.
27. Schafer M, Suter C, Klaiber CH, et al. **Spilled gallstones after laparoscopic cholecystectomy: a relevant problem? A retrospective analysis of 10,174 laparoscopic cholecystectomies.** Surg. Endosc. 1998; 9:344-347.
28. Rice DC, Memon MA, Jamison RL, et al. **Long-term consequences of intraoperative spillage of bile and gallstones during laparoscopic cholecystectomy.** J. Gastrointest. Surg. 1997; 1:85-91.
29. Hussain S. **Sepsis from dropped clips at laparoscopic cholecystectomy.** Eur. J. Rad. 2001; 40:244-247.
30. Sathesh-Kumar T, Saklani AP, Vinayagam R, Blackett RL. **Spilled gall Stones during laparoscopic cholecystectomy: a review of the literature.** Postgrad Med J. 2004; 80:77-9.

Article received on: 11/05/2011

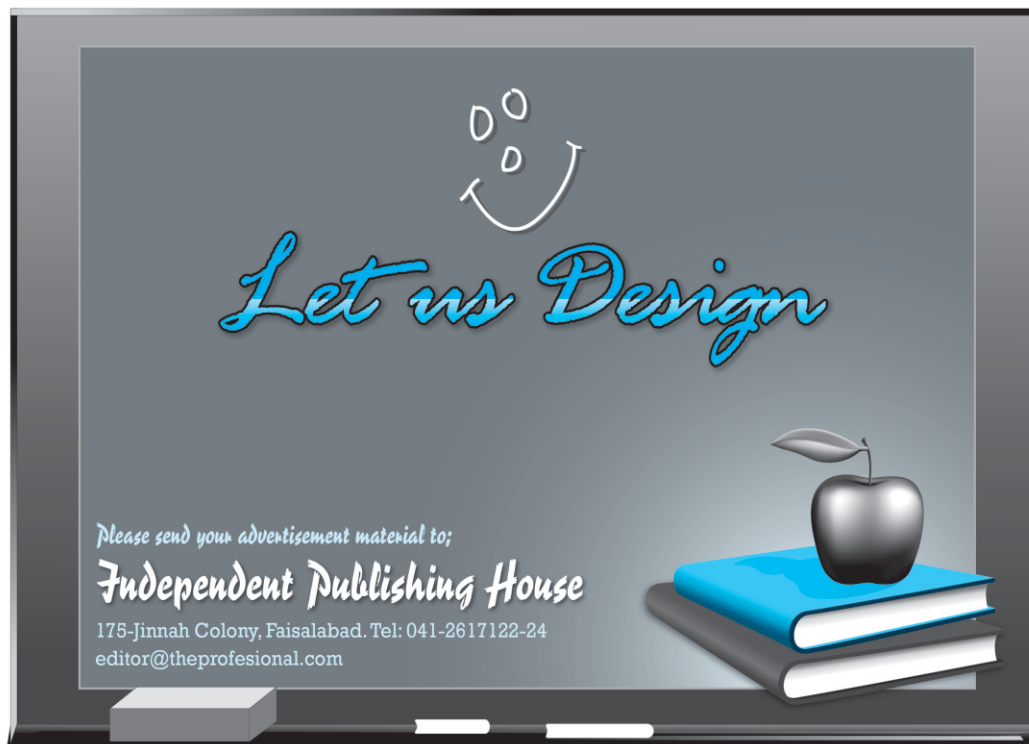
Accepted for Publication: 11/06/2011

Received after proof reading: 12/08/2011

Correspondence Address:
 Dr. Muhammad Rahim Bhurgri
 Medical Director
 Bhurgri Hospital,
 Hyderabad Road, Matli Town
 Distt: Badin
 m_raheem76@yahoo.com

Article Citation:

Bhurgri MR, Rajput MJ, Muhammad SR. Fate of spilled bile with gallstones during laparoscopic cholecystectomy. Professional Med J Sep 2011;18(3): 361-365.



Let us Design

Please send your advertisement material to:
Independent Publishing House
 175-Jinnah Colony, Faisalabad. Tel: 041-2617122-24
 editor@theprofesional.com