



REVERSE RADIAL FOREARM FLAP; MANAGEMENT OF SOFT TISSUE DEFECTS OF DORSUM OF HAND AND WRIST USING REVERSE RADIAL FOREARM FLAP

Hyder Ali¹, Bushra Zulfiqar²

1. MBBS, FCPS
Assistant Professor
Department of Plastic &
Reconstructive Surgery
Dow University of Health Sciences &
Dr Ruth KM Pfau
Civil Hospital Karachi, Pakistan.
2. MBBS, FCPS
Assistant Professor
Department of Plastic &
Reconstructive Surgery,
Dow University of Health Sciences &
Dr Ruth KM Pfau
Civil Hospital Karachi, Pakistan.

Correspondence Address:

Dr. Hyder Ali,
Assistant Professor,
Department of Plastic &
Reconstructive Surgery,
Dow University of Health Sciences &
Dr Ruth KM Pfau
Civil Hospital Karachi, Pakistan.
haider.450@hotmail.com

Article received on:

29/01/2018

Accepted for publication:

15/06/2018

Received after proof reading:

03/12/2018

ABSTRACT... Objectives: To highlight the usefulness of reverse radial forearm fasciocutaneous flap in covering various soft tissue defects of hand and wrist. **Study Design:** Descriptive, experimental study. **Setting:** Department of Plastic & Reconstructive Surgery, Dow University of Health Sciences & Dr Ruth KM Pfau Civil Hospital Karachi. **Period:** December 2016 to January 2018. **Material & Methods:** A total of 16 reverse radial forearm flaps were utilized to cover various soft tissue defects of hand and wrist from various etiologies including road traffic accidents, mechanical trauma, and industrial trauma and fireworks injuries were included. Patients with segmental bone loss and those patients having partial of complete amputation of thumb were excluded. The age ranged from 18 – 45 (mean 29.25) years. Soft tissue defects of dorsum were covered with this flap in 8 cases, 4 cases on palmer aspect and 2 cases for transmetacarpal level and 1st web space defects each. Donor site was covered with split skin graft in all cases. Patients were followed for at least three months postoperatively. **Results:** We had partial loss of flap in two cases which was managed with debridement and skin grafting. Superficial epidermolysis was found in one case and managed conservatively. Donor site was skin grafted in all cases which was healed uneventfully and quite acceptable to the patients in due course of time. **Conclusion:** Reverse radial artery flap has a quite long arc of rotation, which brings it great ease to cover the soft tissue defects of various areas of hand like palm, dorsum and first web space.

Key Words: Hand Injury, Reverse Radial Forearm Flap, Soft Tissue Coverage of Hand.

Article Citation: Ali H, Zulfiqar B. Reverse radial forearm flap; management of soft tissue defects of dorsum of hand & wrist using reverse radial forearm flap. Professional Med J 2018; 25(12):1791-1795. DOI: 10.29309/TPMJ/18.4683

INTRODUCTION

Hand trauma is quite common case we deal in our setup. Common causes include road traffic accidents, fireworks injuries, and industrial trauma.¹ Injuries of the hand render deep structures including tendons, nerves, vessels, bone and joints to become exposed.² In the forearm available regional pedicle flaps are reverse radial flap, posterior interosseus flap, ulnar artery flap and newer techniques includes perforator based flaps based on radial and ulnar arteries. The disadvantage of PIA flap is technically challenging and time consuming procedure.^{3,4} Doral ulnar flap has a limited arc of rotation due to its short pedicle.⁵ Distant flaps include abdominal and groin flap; but they need specific position of hand in dressing for at least 3 weeks which is cumbersome for the patient. Free flap is a time taking tedious and procedure which needs specialized skills and logistics.⁶

The radial forearm flap is a good option for coverage of soft tissue defects of hand.⁷ It is often nicknamed “the Chinese flap.” Cadaveric injection studies performed in Shenyang Military Hospital in 1978 by Dr. Yang Guofan and Dr. Gao Yuzhi led to the identification of the forearm flap and its subsequent description in a series of 60 clinical cases in 1981 in the Chinese literature. In 1980 a delegation of German surgeons visiting China saw this flap and subsequently introduced it to the western world.⁸ A reverse radial forearm flap is distally based flap and has retrograde flow through the ulnar artery and palmar arches after ligation of the proximal radial artery.⁹ The venous drainage is carried out through the venae comitentes of the radial artery.¹⁰

In our study we report our experience of reverse radial forearm flap on various defects of hand and wrist without necessitating the use of a

microvascular flap.¹¹

MATERIALS AND METHODS

This descriptive, experimental study was carried out at the Department of Plastic & Reconstructive Surgery, Dow University of Health Sciences & Dr. Ruth KM Pfau Civil Hospital Karachi, from December 2016 to January 2018. Total 16 patients having soft tissue defects of the dorsum of hand and wrist arising from various etiologies including road traffic accidents, mechanical trauma, and industrial trauma and fireworks injuries were included. Patients who had bone fracture with segmental bone loss, and those patients having partial or complete amputation of thumb were excluded. Age ranges between 18 – 45 (mean 19.25) years. Reverse radial forearm flap was found most suitable option in all these cases. Allen's test was performed preoperatively to confirm the continuity of palmar arch. Conventional reverse radial flap was used in all the cases. During the operation, once the flap has been raised, blood flow through palmar arch was confirmed by applying clamp on the proximal end of radial artery and only then the artery was divided and flap rotated on an arc of 180 degree. In majority of the cases flap was tunneled to the defect site. Only in three of the cases where subcutaneous tunnel was not found satisfactory, it was completely opened. Donor site was covered with split skin graft in all cases.

RESULTS

Sixteen cases of hand and wrist trauma were provided soft tissue cover with reverse radial forearm flap from December 2016 to January 2018. Twelve patients were males and 4 were females. Age ranges between 18 – 45 (mean 19.25) years. Most common soft tissue defects (8 cases) were in the area of dorsum of hand (Figure-3 & 4), in 4 cases this flap was used for the coverage of palmar defects (Figure 1) while two cases required coverage of amputation stump at transmetacarpal level (Figure 2). Web space defects were covered with this flap in 2 cases and yet another required a big flap to cover the soft tissue defects at palm and thumb. Patients were followed for at least three months postoperatively. There was partial loss of two flaps which was debrided and skin grafting was done. Superficial epidermolysis was found in only 1 case which was managed conservatively. Rest of all the flaps in this series survived completely. (Table-I). Skin graft was applied at donor site in cases which was taken well. Three patients were not satisfied with the color mismatch of the grafted area. The difference of color at grafted areas improved in the later follow ups visits. There was no difficulty in post op movement of the remaining hand function and symptoms of post-operative neuroma were absent.

S. No.	Age (years)	Gender	Location of defect	Size of flap (cm)	Outcome	Secondary procedure
1	27	M	Dorsum of hand	8.2 x 7.5	Flap survived	-
2	38	M	Dorsum of hand	6.8 x 8.5	Flap survived	-
3	19	M	Dorsum of hand	6 x 7.3	Flap survived	-
4	18	F	Dorsum of wrist	5.6 x 8	Flap survived	-
5	25	M	Transmetacarpal level	7 x 6.5	Flap survived	-
6	40	M	Palm and thumb	8 x 10.5	Partial flap necrosis	Debridement & Skin grafting
7	31	F	Dorsum of wrist	7.5 x 9	Flap survived	-
8	22	M	Dorsum of hand	6.2 x 8	Flap survived	-
9	28	M	Dorsum of wrist	6.4 x 8.4	Flap survived	-
10	34	M	1 st web space	7.4 x 9	Flap survived	-
11	23	M	Palm of hand	5.5 x 7.5	Superficial epidermolysis	Managed conservatively
12	45	M	1 st web space	6.8 x 7.8	Flap survived	-
13	24	F	Dorsum of hand	7.5 x 8.3	Flap survived	-
14	33	M	Transmetacarpal level	6.5 x 9	Flap survived	-
15	35	M	Palm of hand	7 x 9	Partial flap necrosis	Debridement & Skin grafting
16	26	F	Palm of hand	5.8 x 8	Flap survived	-

Table-I. Showing demographic data, size of the defect and outcome of reverse radial forearm flap

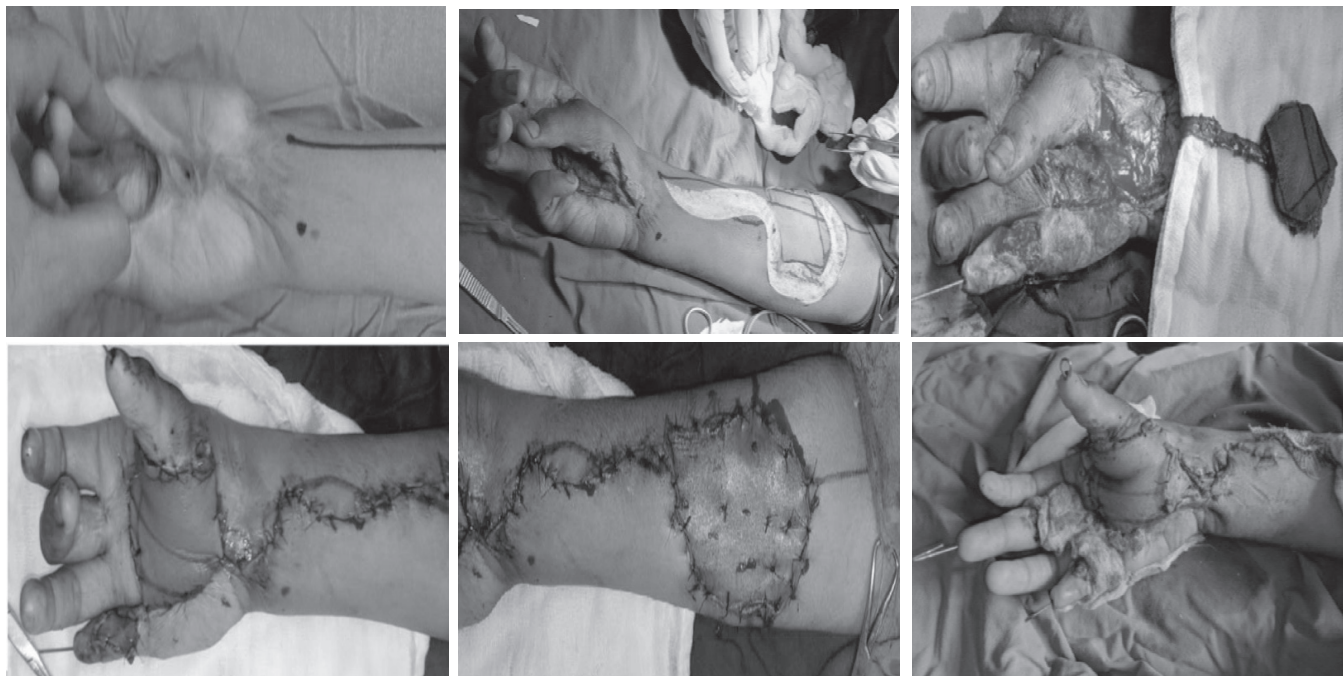


Figure-1. (Case # 16): Pictures of post burn contracture of a 26-years-old female, initial marking and incision of the flap, lap isolated after division of radial artery, inset of flap, skin grafting at the donor site, one week postoperative showing well perfused flap.

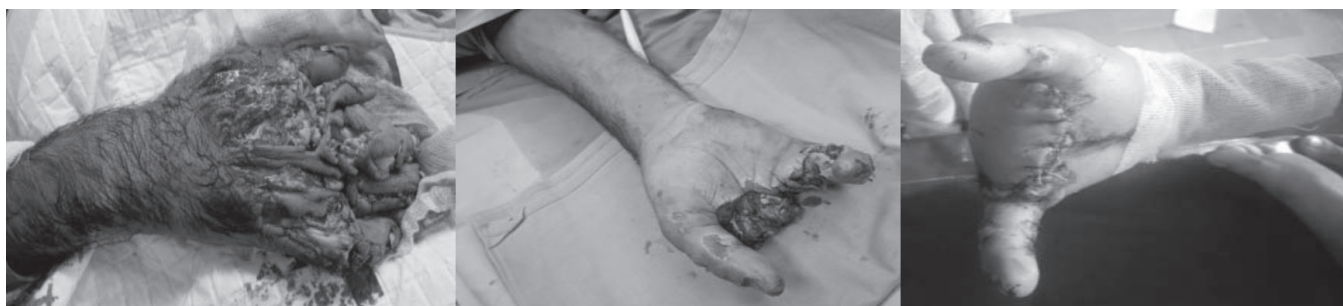

Figure-2. (Case # 5): A 25-years old, right hand dominant, laborer presented with machine injury of his right hand with severe crush injury of index, middle and ring fingers. (a) Injury (b) After debridement (c) Reverse radial forearm flap for soft tissue coverage of the defect.

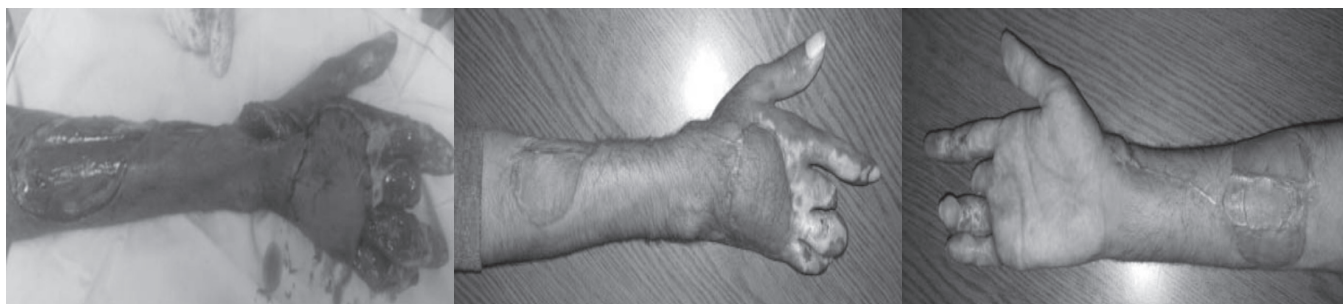

Figure-3. (Case # 3): A 28-years old, right hand dominant, presented with road traffic accident of his right hand with severe crush injury of middle fingers (a) Flap inset at the defect after debridement (b) After 6 weeks of procedure (c) Skin grafting at the donor site.

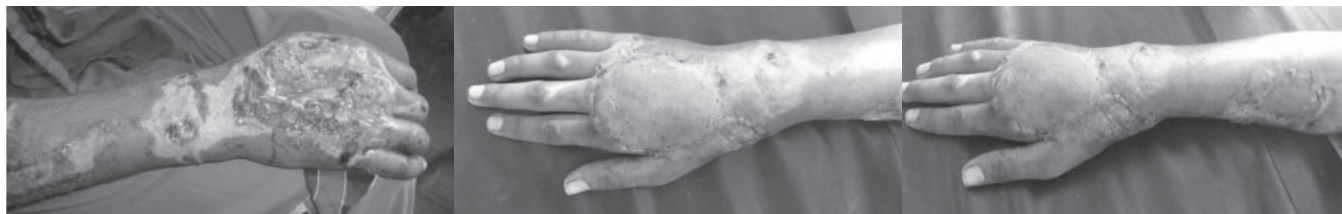

Figure-4. (Case # 2): A 38-years old, right hand dominant, presented with friction burn due to road traffic accident of his right hand with exposed extensor tendons (a) Injury at the time of presentation (b) After 2 months of procedure (c) After 3 months with skin grafting at the donor site.

DISCUSSION

Hand trauma is quite common case we deal in our setup. Common causes include road traffic accidents, fireworks injuries, industrial trauma and hand trauma. Injuries of the hand render deep structures including tendons, nerves, vessels, bone and joints to become exposed.¹ In plastic surgery armamentarium, reconstruction of soft tissues of hand remains a difficult task² in order to maintain the good function of the hand¹² as well as cosmesis¹³, in the meantime providing the coverage to all vital structures of the hand.¹⁴ In the literature various types of flaps have been described for the dorsal and palmer soft tissue defects of the hand.¹⁵ Many times it is noticed that dorsal aspect of the hand is more susceptible to injuries as a result the tendons, bones and joints becomes exposed.¹⁵ Options of various local flaps are available in the hand but they provide coverage to small wound only.⁵ For any wound on any part of the body wound coverage can be done by using local pedicle flaps, distant pedicle flaps or with the free flaps.¹⁵ Distant flaps of the hand essentially have the problems which include specific position of the hand in dressing for minimum of 3 weeks, it is two stage procedure resulting in prolong hospital stay and effects patient financial status due to late return of the patient to work, clinically patient would have stiffness on the all joints of the hand as well as edema which is secondary to prolong immobilization which is necessary for this procedure.⁵ In the forearm available regional pedicle flaps are reverse radial forearm flap, ulnar artery flap, posterior interosseus artery flap¹⁶, radial artery perforator flap and ulnar artery perforator flap, the latter flaps are newer techniques.¹⁵ Reverse radial forearm flap is very appropriate option for the medium and large wounds on the

dorsum of the hand extending from distal part of wrist to the metacarpophalangeal joint.⁸ It can be raised as fasciocutaneous flap, suprafascial or adiposofascial flap and provides robust tissues for soft tissue reconstruction of the hand, as it has constant anatomy, this flap also provide a better contour and avoids the necessity of having to thin the flap.^{3,8} This is a resourceful flap and according to the dimensions of the defects it can be raised in different sizes.¹⁷ Large defects can also be covered and it is documented in the literature that whole of the skin of the forearm can be raised on radial artery leaving 2cm cuff of skin on ulnar aspect dorsally.^{5,8} Donor site has cosmetic and functional disadvantages, because it can only be primarily closed if the diameter of the flap is less than 3cm in size, larger defects requires skin grafting for coverage of secondary defects.^{3,8} One of the most distressing complications of this flap during harvesting; is the damage of superficial sensory branch of radial nerve which can give rise to neuroma formation as well as sensory loss to anatomic snuff box area and care should be taken to avoid these problems.

Microvascular free flap we have various options like anterolateral thigh flap, lateral arm flap, scapular and parascapular fasciocutaneous flap and deep inferior epigastric flap. In addition to prolong surgical time, requires technical expertise and specialized instruments each free flap has its own drawback. Anterolateral thigh flap, parascapular and scapular flaps can be extremely thick resulting in poor contour of the hand and requires debulking later on. Lateral arm flap has a limitation of donor site closure and if skin paddle is > 6 cm needs skin grafting which produces unacceptable scar in the arm.¹⁸

CONCLUSION

The reverse radial forearm flap provides an effective, robust and versatile reconstructive option for upper extremity soft-tissue defects with constant anatomy, less operative time and good cosmetic result.

ACKNOWLEDGEMENTS

The authors would like to thanks The Department of Plastic & Reconstructive Surgery at Dow University of Health Sciences & Dr Ruth KM Pfau Civil Hospital Karachi for their general support.

CONFLICT OF INTEREST


All surgeries were performed at Dr Ruth K M Pfau Civil Hospital Karachi where treatment is provided free of cost.

Copyright© 15 June, 2018.

REFERENCES

1. Sajjad Y, Hameed A, Gill NA, Bhutto AW. **Use of a pedicled flap for reconstruction of extensive soft tissue defects around elbow.** J Coll Physic Surg Pakistan. 2010; 20 (1): 47-50.
2. Bilal M, Ahmed TM, Dar MF, Ahmed N. **Reverse posterior interosseus flap; Useful but problematic flap.** Pak Armed Forces Med J 2016; 66(3):341-45.
3. Hansen AJ, Duncan SFM, Smith AA&, Shin AY, Moran SL, Bishop AT. **Reverse radial forearm fascial flap with radial artery preservation.** Hand. 2007; 2(3): 159-63.
4. Vishal M. **Retrograde posterior interosseous flap.** Iowa Orthop J.2007; 27: 58–60.
5. Cheema SA, Talaat N. **Reverse radial artery flap for soft tissue defects of hand in pediatric age group.** J Ayub Med Coll Abbottabad. 2009; 21(1): 35-8.
6. Khan AT, Khan M, Ullah H, Haider SM, Aziz A, Tahir M. **An audit of pedicled flap reconstruction surgeries.** J Med Sci. 2016; 24(4): 234-240.
7. Maan ZN, Legrand A, Long CAB, Chang JC. **Reverse radial forearm flap.** PlastReconstSurg– Global Open. 2017; 5(4): e1287.
8. Wei FC, MardiniS. **Flaps and Reconstructive Surgery.** 2ndedition. London: Elsevier Health Sciences; 2009: 321-38.
9. Ashfaq F. **Upper extremity burn reconstruction with reverse flow flaps: Indications and utility.** Pak J Surg. 2013; 29(3): 195-8.
10. Akdag O, Karamese M, NebilSelimoglu M, Akatekin A, Abacı M, Sutcu M, et al. **Reverse adipofascial radial forearm flap surgery for soft-tissue reconstruction of hand defects.** Eplasty. 2016; 16: 284-92.
11. Zambacos, George J. M.D.; Mandrekas, Apostolos D. M.D., Ph.D. **The reverse radial forearm flap in reconstruction of the hand.** Plast Reconst Surg. 2008; 122(6): 1979-80.
12. Ahmed M. **Management of hand trauma.** Journal of Surgery Pakistan (International). 2008; 13(3): 128-31.
13. Bashir MM, Sohail M, Shamsi HB. **Traumatic wounds of the upper extremity: Coverage strategies.** Hand clinics. 2018; 34(1): 64-71.
14. Kaufman MR, Jones NF. **The reverse radial forearm flap for soft tissue reconstruction of the wrist and hand.** Tech Hand UpExtrem Surg. 2005; 9(1): 47-51.
15. Adani R. **Dorsal hand coverage.** BMC Proc. 2015; 9 (Suppl 3): A59.
16. Shahzad MN, Ahmed N, Qureshi KH. **Reverse flow posterior interosseous flap: Experience with 53 flaps at Nishtar Hospital, Multan.** J Pak Med Assoc. 2012; 62: 950-4.
17. Khalid K, Humayoun W. **Ulnar artery perforator flap for the coverage of electric injury defects at wrist.** PJMHS. 2016; 10(1): 240-3.
18. Neumeister M, Hegge T, Amalfi A, Sauerbier M. **The reconstruction of mutilated hand.** Semin Plast Surg. 2010; 24(1): 77-102.

AUTHORSHIP AND CONTRIBUTION DECLARATION

Sr. #	Author-s Full Name	Contribution to the paper	Author=s Signature
1	Hyder Ali	Chief Plastic surgeon involved in performing all surgeries, postoperative follow-up of patients, final approval of the manuscript and responsible for accuracy and integrity of results.	
2	Bushra Zulfiqar	Original design and writing of manuscript and assisting chief surgeons while performing surgeries.	