



# ORBITAL FLOOR RECONSTRUCTION WITH TITANIUM MESH;

## Our experience

Dr. Muhammad Usman Khalid<sup>1</sup>, Dr. Arshad Mahmood Malik<sup>2</sup>, Dr. Omer Sefvan Janjua<sup>3</sup>

1. BDS, FCPS  
Assistant Professor of Oral & Maxillofacial Surgery  
Punjab Medical College / Allied Hospital Faisalabad
2. BDS, MDS  
Associate Professor of Oral & Maxillofacial Surgery  
Punjab Medical College / Allied Hospital Faisalabad
3. BDS, FCPS, FFDRCSI  
Assistant Professor of Oral & Maxillofacial Surgery  
Punjab Medical College / Allied Hospital Faisalabad

**Correspondence Address:**  
**Dr. Muhammad Usman Khalid**  
Address: 7 A Staff Colony  
Punjab Medical College Faisalabad  
drusmankhalid82@hotmail.com

Article received on:  
20/05/2014  
Accepted for Publication:  
30/05/2014  
Received after proof reading:  
02/06/2014

**ABSTRACT... Objective:** To determine the outcome of orbital floor reconstruction with titanium mesh in terms of diplopia, enophthalmos, dystopia and infection etc. **Study design:** Descriptive case series. **Place & duration of study:** Department of Oral & Maxillofacial Surgery, Punjab Medical College / Allied Hospital Faisalabad. One and Half year from 01-10-12 to 31-03-14. **Material and Method:** Twenty two patients clinically and radiographically having defect in the orbital floor due to trauma were included in the study. Titanium mesh was used to reconstruct the orbital floor through infraorbital rim incision and secured in place with 5mm micro screws. The variables to be analyzed were diplopia, enophthalmos, orbital dystopia and infection. **Results:** In our study male gender predominates over female 20/22. Mean age of patients is 29.36 years  $\pm$  5.21. Diplopia persisted in 2/10 (20%) patients. Enophthalmos persisted in 7/18 (38.8%) patients. dystopia persisted in 1/4 (25%) patients. Infection didn't develop in any of our patient (0%). Visual acuity was not affected in any of the patient (0%). **Conclusions:** Titanium mesh is a suitable material for reconstruction of orbital floor fractures with little complication rate and no donor site morbidity.

**Key words:** Orbital floor reconstruction, diplopia, Enophthalmos.

**Article Citation:** Khalid MU, Malik AM, Janjua OS. Orbital floor reconstruction with titanium mesh; our experience. Professional Med J 2014;21(3): 575-579.

## INTRODUCTION

Orbital fractures account for 40% of craniofacial injuries. They vary from simple zygomatic fractures to complex craniofacial injury involving the orbital rim and several orbital walls. Orbital floor, which is extremely thin of the four walls of the orbit is the most frequently injured. According to the literature, such fractures account for 67 to 84% of cases of orbital fractures<sup>1,2</sup>.

The common causes of orbital floor fracture are motor vehicle accident, physical assault, and sport-related injuries. Rarely, it can be due to fall, gunshot or industrial accident.

Orbital floor fractures can be generally classified as pure or impure blowout fractures; the first are isolated orbital floor fractures and the second are also associated with an orbital rim fracture<sup>1,3</sup>.

Numerous materials such as autogenous bone,

cartilage and alloplastic implants have been used to reconstruct the orbital floor but the optimal material for reconstruction of orbital floor and walls remains highly controversial. The ultimate aims are the reconstruction of the bony orbital defect with reestablishment of anatomy, volume, function and esthetics<sup>4</sup>.

Alloplastic materials including titanium mesh, silastic, porous polyethylene etc have gained popularity for reconstruction of the orbit floor because of their ease of use and the fact that they involve no donor site morbidity. Titanium mesh is a very suitable reconstructive material because of its biocompatibility, shorter operative time, ease of intraoperative contouring and rigid fixation<sup>5,6</sup>.

Aim of this study is to share our experiences with the use of titanium mesh for orbital floor reconstruction.

## MATERIAL & METHOD

Twenty two patients presented to Oral & Maxillofacial Surgery Department Allied Hospital Faisalabad having clinical and radiographic defect of the orbital floor along with diplopia, enophthalmos or orbital dystopia were included in the study. Patients medically unfit for surgery under general anesthesia or having ipsilateral or contralateral vision loss were not included in the study.

After taking complete history, thorough clinical and systemic examination was carried out. Diplopia was checked using snellen chart and forced duction test, enophthalmos was assessed clinically by bird's eye view and worm hole view and orbital dystopia was checked by placing a wooden spatula in front of the eye balls parallel to Frankfort horizontal plane. To evaluate the exact extent of defect we performed, digital occipitomeatal view, Coronal & axial sections of Computed tomography (CT) scan and three dimensional reconstruction according to situation.

After explaining the outcome of surgical procedure to every patient included in this study an informed consent was taken before the surgical procedure. Infraorbital rim incision was used to expose the orbital floor defect in all patients. Titanium mesh was secured in place using 5mm microscrews after careful blunt sub periosteal dissection of the tissues. Preoperatively forced duction test was performed to assess muscle/soft tissue entrapment. Wound was closed primarily in all patients after achieving hemostasis. Patients were discharged on 2nd postoperative day.

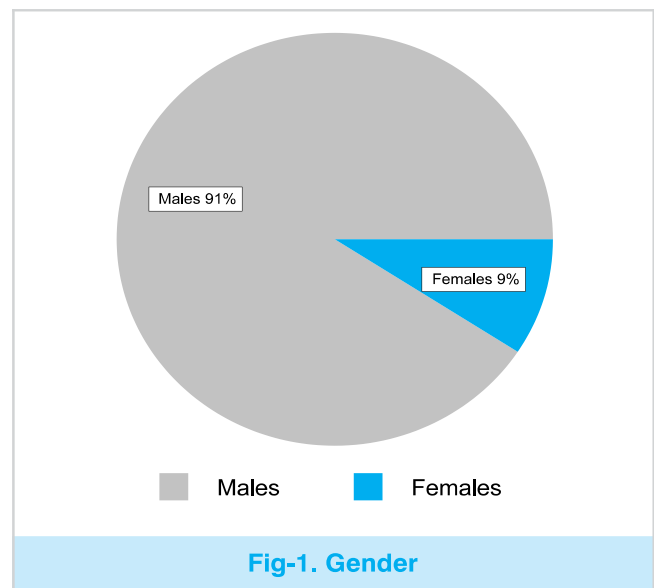
The clinical follow-up was performed at 1 week, 1 month, 3 months, and 6 months after treatment. On each follow-up patients were checked for persistence of diplopia, enophthalmos, dystopia, signs of infection which include presence of pus discharge or severe pain and loss of visual acuity. All the observations were entered on specially designed proforma.

## DATA ANALYSIS

Data was entered & analyzed by using SPSS version 17.0. Mean and standard deviation were calculated for quantitative variables like age. Qualitative data like gender, diplopia and enophthalmos were presented as frequency and percentages.

## RESULTS

In our study male gender predominates over female. 20/22 (91%) patients were male and 02/22 (9%) patients were female (Fig-1).



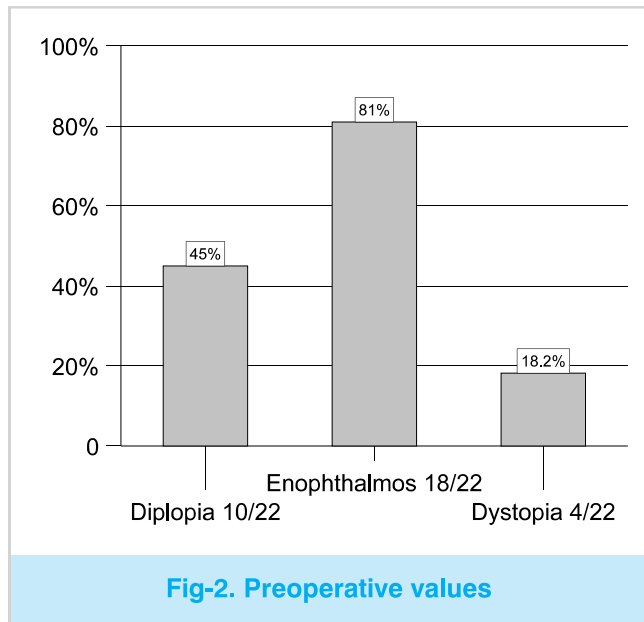
The age ranged from 22 to 40 years with mean age of 29.36 years  $\pm$  5.21. Male had the mean age of 29.6 years  $\pm$  5.33 while female had the mean age of 29.36 years  $\pm$  5.21.

Right orbital floor was more commonly affected than the left. Out of 22 patients 14 presented with right orbital floor fracture and 8 with the left.

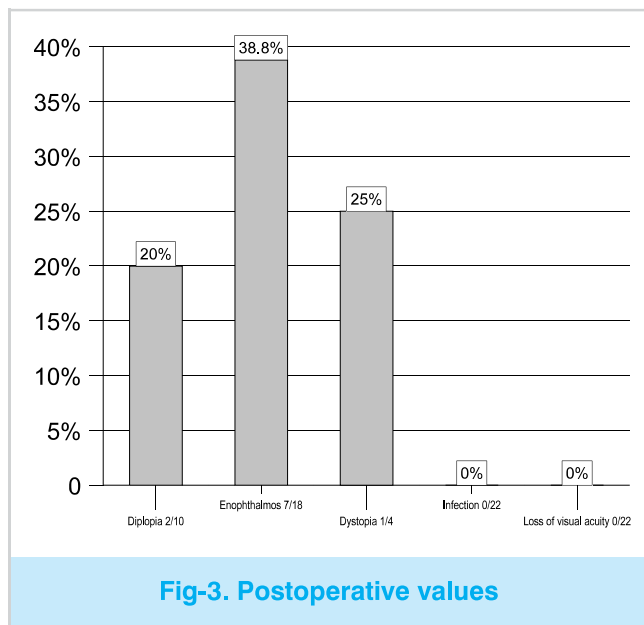
Pure blow-out fracture was present in 5 patients and in 17 patients orbital floor fracture was associated with other fractures. Out of 17 patients; 10 have associated zygomatic bone fracture, 4 have lefort III fracture and 3 have naso-orbito-ethmoidal (NOE) fracture.

Preoperatively Diplopia was present in 10 (45%) patients (Graph 2) and postoperatively diplopia

persisted in 2 out of these 10 (20%) patients postoperatively (Graph 3).



Enophthalmos was present preoperatively in 18 (81%) patients (Graph 2) and persisted in 7 (38.8%) patients postoperatively (Graph 3).



Orbital dystopia was present in 4 (18.2%) patients preoperatively (all had zygomatic bone fracture) (Graph 2) and persisted in 1 (25%) patient postoperatively (Graph 3).

None of our patients developed infection (0%)

postoperatively (Graph 3). There was no loss of Visual acuity in any of our patient (0%) postoperatively (Graph 3).

**DISCUSSION**

The orbit protects the visual apparatus through the bone structures, and it acts as a receptacle. Nevertheless, the slightest trauma can provide serious damage. This is why the integrity of the eye and associated tissues must be evaluated accurately and quickly to avoid irreversible damage.

The repair of the orbital floor fractures is not without risks, which must be taken into consideration when surgery is decided as a treatment of choice. Careful subperiosteal dissection prevents injury to the musculature and ensures complete release of the soft tissues from the osseous segments during bone reconstruction. Care must be taken to prevent entrapment of the soft tissues, especially when using metallic mesh systems, but also when using nonresorbable polymers or bone. Entrapment is avoided by eliminating sharp edges when contouring the mesh and not letting intraorbital tissue escape or be trapped by the mesh borders. It is useful to perform a forced duction test at the completion of the procedure to verify unrestricted movement<sup>1,4</sup>.

Reconstruction of the orbital floor with bioresorbable materials is a controversial subject. None of the materials has yet proven to be successful without any complications in clinical work. One of the main issues is the maintenance of the initial three dimensional shape of the implant. To achieve this, the implant need to resist coiling and deformation and to be strong enough to tolerate the pressure exerted by the orbital content without being passively moulded. It should also be biocompatible<sup>7</sup>.

The ideal material should have biological and physiological properties that replicate those of the tissue it replaces. The material should be permanently accepted by the host.

In our study male gender predominates over the female. It is consistent with previous studies. In a study carried by Gabrielli et al in 2011 male gender predominates<sup>4</sup>. Another study carried by Sakakibara et al in 2009 also show the same results<sup>8</sup>.

In our study most of the patients fall in the third and fourth decade of life. It is consistent with the literature. In a study carried by Sakakibara et al in 2009 mean age of the patients was 26 years<sup>8</sup>. In another study carried by Kosaka et al in 2004 most of the patients were in third and fourth decades of life<sup>9</sup>.

Patients who experience true diplopia naturally are troubled by this symptom and nearly always present this as their chief complaint. Basically diplopia may be monocular or binocular. The three most common hypotheses for binocular double vision and impaired eye movement are different eye ball level of both eyes, contusion injury to the extraocular muscles or soft tissue and incarceration of these structures to the fracture line<sup>10</sup>.

Our patients, in most of the cases, had double vision and limitation of movements in upward gaze. This can be explained by mechanisms mentioned in previous paragraph. CT scan has been reported to be sensitive for orbital fat, orbital muscles and hematoma<sup>11,12</sup>.

In our study diplopia was corrected in 80% patients and there were two patients in which diplopia persisted postoperatively. These findings are consistent with most of previous studies. One study carried by Gabrielli et al in 2011 shows same kind of results<sup>4</sup>.

In our study enophthalmos was corrected in 61.2% patients and there were 7 patients in which enophthalmos persisted postoperatively. These findings are consistent with some of previous data. A study carried by Avashia et al in 2012 on different materials used for orbital floor reconstruction also shows titanium mesh corrected enophthalmos in 85% of the patients<sup>5</sup>. Results of some studies are

not consistent with our study. In a study carried by Degala et al in 2013 enophthalmos was corrected in all of their patients postoperatively<sup>6</sup>.

None of our patient developed postoperative infection. These findings are not favored by some of previous studies. One study carried by Gabrielli et al in 2011 shows that infection developed in 4% of patients postoperatively<sup>4</sup>. but some studies favor these findings. A study carried by Degala et al in 2013 shows that infection developed in none of their patients<sup>6</sup>.

Visual acuity was not lost in any of our patient. These findings are consistent with previous studies. A study carried by Degala et al in 2013 shows same kind of results<sup>6</sup>.

## CONCLUSIONS

Titanium mesh is a suitable material for reconstruction of orbital floor fractures with little complication rate and no donor site morbidity if used properly and meticulously. It can give satisfactory results for the correction of diplopia, enophthalmos and dystopia.

Copyright© 30 May, 2014.

## REFERENCES

1. Piombino P, Iaconetta G, Ciccarella R, Romeo A, Spinzia A, Califano L. **Repair of orbital floor fracture; our experience and new technical findings.** Craniomaxillofac Trauma Reconstr. Dec 2010;3(4):217-22.
2. Tuncer S, Yavuzer R, Kandal S, Demir YH, Ozmen S, Latifoglu O, Atabay K. **Reconstruction of traumatic orbital floor fracture with resorbable mesh plate.** J Craniofac Surg 2007;18:598-605.
3. Tong L, Bauer R J, Buchman S R. **A current 10-year retrospective survey of 199 surgically treated orbital floor fractures in a nonurban tertiary care center.** Plast Reconstr Surg.2001;108:612-21.
4. Gabrielli MF, Monnazzi MS, Passeri LA, Carvalho WR, Gabrielli M, Hochuli-Vieira E. **Orbital wall reconstruction with titanium mesh; retrospective study of 24 patients.** Craniomaxillofac Trauma Reconstr. Sep 2011;4(3):151-6.
5. Avashia YJ, Sastry A, Fan KL, Mir HS, Thaller SR. **Materials used for reconstruction after orbital floor fracture.** J Craniofac surg 2012; 23: 49-55.

6. Degala S, Shetty SK, Biddappa L. **Reconstruction of pot-traumatic orbital wall defects with titanium mesh.** J Maxillofac Oral Surg. Oct 2013; 12(4): 418-23.
7. Woo KS, Cho PD, Lee SH. **Reconstruction of severe medial orbital wall fractures using titanium mesh plates by the pericircular approach.** J Plast Surg Hand Surg Dec 2013.
8. Sakakibara S, Hashikawa K, Terashi H, Tahara S. **Reconstruction of the orbital floor with sheets of autogenous iliac cancellous bone.** J Oral Maxillofac Surg 2009;67:957-61.
9. Kosaka M, Matsuzawa Y, Mori H, Matsunaga K, Kamiishi H. **Orbital wall reconstruction with bone grafts from the outer cortex of the mandible.** J Cranio Maxillofac Surg 2004;32:374-80.
10. Ahn HB, Ryu WY, Yoo KW, Park WC, Rho SH, Lee JH, et al. **Prediction of enophthalmos by computer-based volume measurement of orbital fractures in a korean population.** Ophthal Plast Reconstr Surg 2008;24:36-9.
11. Manfre L, Nicoletti G, Lombardo M, Consoil V, Pero G, Albanese V. **Orbital "blow-in" fracture: MRI.** Neuroradiology 1993;35:612-3.
12. Zhan Y, Engel M, Kujat C, Backens M, Kubale R, Kramann B. **Proton spin tomography of the orbit in posttraumatic motility disorders.** Rofo 1995;163:127-33.

# The Professional

## Medical Journal

Electronic submission saves time, postage costs and allows the manuscript to be handled in electronic form throughout the publication process.

Accepts electronic submission of articles via e-mail, attachment in MS Word format at following address:

info@theprofesional.com  
editor@theprofesional.com  
publication@theprofesional.com

for more details, visit us ;

[www.theprofesional.com](http://www.theprofesional.com)