



FAST ULTRASOUND;

A BASIC TOOL TO EVALUATE THE BLUNT ABDOMINAL TRAUMA PATIENT AND HELP TO DECISION MAKING FOR EMERGENCY SURGERY

Dr. Muhammad Jawed¹, Dr. Ubedullah Shaikh², Dr. Muhammad Laiq uz Zaman Khan³,
Dr. Shazia Ubed Shaikh⁴

1. FCPS. FRCS
Asst Professor Surgery &
Bariatric Surgeon Dow University &
Health Sciences Hospital
OJHA Campus Karachi
2. Senior Medical Officer
Surgery Department
Dow University &
Health Sciences Hospital
OJHA Campus, Karachi
3. FCPS
Asst Professor Surgery
Dow University &
Health Sciences Hospital
OJHA Campus, Karachi
4. Medical Officer
Radiology Department
Jinnah Postgraduate Medical Centre
Karachi

Correspondence Address:

Dr Muhammad Jawed
FCPS, FRCS
Asst Professor Surgery &
Bariatric Surgeon
Dow University &
Health Sciences Hospital,
OJHA Campus Karachi
dr.jaweddow@gmail.com

Article received on:

04/10/2013

Accepted for Publication:

16/11/2013

Received after proof reading:

21/04/2014

INTRODUCTION

Road vehicular trauma is the chief reason of blunt abdominal trauma in the civilian population. Auto-to-auto and auto-to-pedestrian collisions have been cited as causes in 50-75% of cases¹. Other common etiologies include falls and industrial or recreational accidents. The care of the trauma patient is demanding and requires speed and efficiency. Evaluating patients who have sustained blunt abdominal trauma remains one of the most challenging and resource-intensive aspects of

ABSTRACT... Objective: Fast ultrasound is a basic tool to evaluate the blunt abdominal trauma patient and help to decision making for emergency surgery. **Study design:** Observational study. **Place and duration of study:** The King Fahad Hospital Madina Munawara, over a period between 2010 and 2011. **Methodology:** This study consisted of 765 patients came in Emergency department The King Fahad Hospital Madina Munawara Level II, or Regional Resource Trauma Center Saudi Arabia. Detailed History was taken from all the patients with special regard to blunt abdominal trauma. All patients were brought to a trauma resuscitation area where a trauma team conducted a primary survey, after an airway and adequate oxygenation/ventilation were established. The FAST examinations were performed using 4 windows: subxiphoid, right upper quadrant, left upper quadrant, and suprapubic. The critical areas for intra-abdominal bleeding were the hepatorenal space (Morrison's pouch), the spleno-renal space, and the pelvic pouch of Douglas. The FAST examinations were interpreted on the spot and results Recorded. Results were prepared with help of tables and graphs. Data was analyzed through SPSS software. **Results:** 73 out of 765 patients who underwent FAST ultrasound in the Emergency Room. 40 (54.79%) cases were road traffic accident (RTA) injuries followed by injury due to fall were in 33(45.20%) cases. Findings are fast ultrasound observed 49 out of 73 patients (67.12%) were considered positive FAST who had fluid (blood) in the peritoneal cavity and these patients shift to Operative Room for surgery. While 24(32.87%) patients with no evidence of intraperitoneal fluid were considered negative for FAST and these patient underwent CT scans for evidence of solid organ injury(Chart No.2). 5 out of 24 cases of solid visceral trauma found on CT scan abdomen, but had not been detected by FAST then shift to operative room after resuscitation. **Conclusions:** We conclude that FAST ultrasound is very helpful to assessment of blunt abdominal trauma and to detect intraabdominal fluid. Fast ultrasound can help in the quick decision for surgical intervention within minutes of a patient's arrival at emergency department.

Key words: Blunt abdominal trauma, Diagnostic peritoneal lavage, Fast Ultrasound, Trauma Assessment

Article Citation: Jawed M, Shaikh U, Khan MLZ, Shaikh SU. Fast ultrasound; a basic tool to evaluate the blunt abdominal trauma patient and help to decision making for emergency surgery. Professional Med J 2014;21(2): 407-411.

acute trauma care². The most important initial concern in the evaluation of a patient with blunt abdominal trauma is an assessment of hemodynamic stability. In the hemodynamically unstable patient, a rapid evaluation must be made regarding the presence of hemoperitoneum or free fluid.

Clarke and colleagues' review of the Pennsylvania Trauma Systems Foundation trauma registry identified 243 hypotensive patients with intra-

abdominal injury who were initially evaluated in a trauma center³. The probability death increased as time spent in the ED increased up to 90 minutes. Hemodynamically stable patients allow for a more time intensive evaluation and alternative testing to diagnose intra-abdominal injury. While physical exam in the stable, alert, non-intoxicated patient was reasonably accurate, it is not infallible and clinical observation with serial examinations is warranted. Modalities for the evaluation of Blunt Abdominal Trauma (BAT) patient include diagnostic peritoneal lavage (DPL) and computed tomography (CT) of the abdomen. DPL is insensitive to abdominal injuries that do not produce intraperitoneal hemorrhage. As a result, it cannot help detect some injuries of the retroperitoneum, pancreas and contained injuries to solid intraperitoneal organs. A number of studies advocate that US should replace DPL for the reasons; it is less costly, noninvasive, easily repeated, and is a bedside examination. Using bedside ultrasonography to evaluate trauma patients⁴.

In comparison to US, the disadvantages of CT include higher costs, use of iodinated contrast medium that places the patient at risk of aspiration, and radiation exposure. Another disadvantage of CT is that the patient needs transport, which may be an added risk for the severely injured patient in unstable condition.

Since the 1980's the Focused Assessment with Sonography for Trauma (FAST) exam has been one of the most widely used applications in emergency bedside ultrasound, and has become a standard part of the initial assessment and resuscitation of the trauma patient. The FAST exam is a tool to evaluate the trauma patient for peritoneal hemorrhage. By utilizing four simple sonographic 'windows', the clinician can assess for peritoneal bleeding at the bedside in less than 5 minutes⁵.

In the recent metaanalysis by Stengel et al, a review of 30 clinical trials and over 9000 patients, found an overall sensitivity of 79% and specificity of 99%, leading the authors to conclude that a

negative exam does not obviate the need for further imaging such as CT scan⁶.

Thus, the investigators concluded that FAST in the hypotensive patient is an effective screening tool and, when coupled with risk assessment, can effectively rule out intra-abdominal injury requiring surgical intervention.

Therefore we sought to justify FAST is an emergency tool as bridge to decision in an unstable patients with Blunt Abdominal Trauma (BAT) for early intervention in decreasing morbidity and mortality. This may be the only diagnostic modality in unstable patients where CT is not available or not feasible for the patient

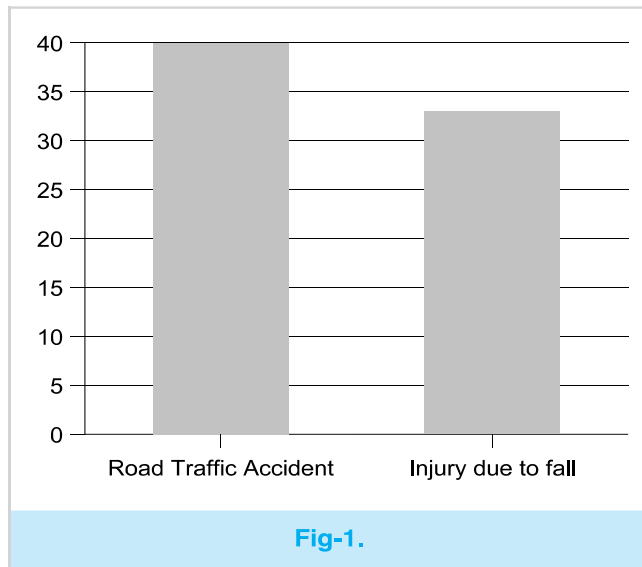
MATERIALS AND METHODS

All cases of trauma admitted through ER at the King Fahad Hospital Madina Munawara, over a period between 2010 and 2011 and who received a FAST ultrasound examination in the Emergency Department for blunt abdominal trauma were included. The King Fahad Hospital Madina Munawara Level II, or Regional Resource Trauma Center. All patients were brought to a trauma resuscitation area where a trauma team conducted a primary survey, after an airway and adequate oxygenation/ventilation were established. The FAST examinations were performed using 4 windows: subxiphoid, right upper quadrant, left upper quadrant, and suprapubic. The critical areas for intra-abdominal bleeding were the hepatorenal space (Morrison's pouch), the spleno-renal space, and the pelvic pouch of Douglas. The Ultrasound Apparatus kept in the trauma resuscitation area. General surgery residents performed the FAST with on call sonologist. The FAST ultrasound examinations were classified as positive (clearly showing fluid on at least one view), equivocal (no critical views seen), or negative (good visualization in at least three windows, no fluid seen). No quantitative scoring system was used for the amount of fluid detected. The primary aim of the FAST examination was to detect intra-abdominal blood. There was no attempt to determine visceral organ injury. The FAST examinations were interpreted on

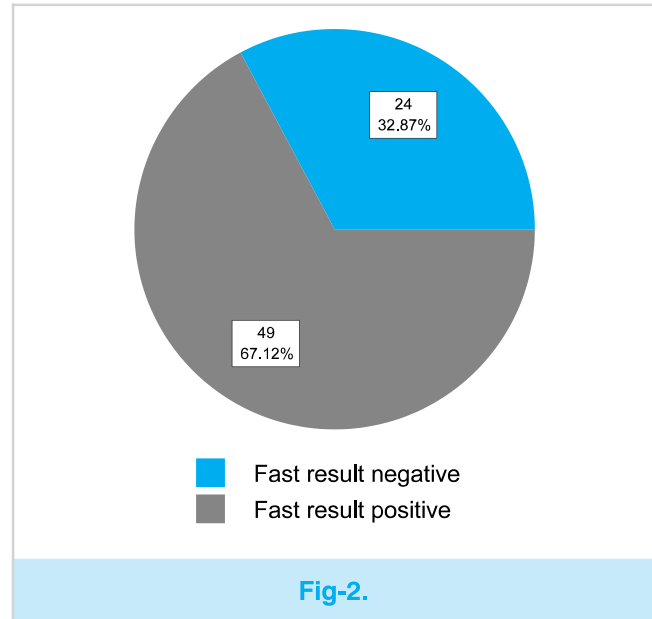
the spot and results Recorded. CT scans of the head, chest, abdomen, and pelvis were performed when indicated, usually if the clinical examination was equivocal or unreliable, and if the patient remained hemodynamically stable, Patients were grouped into FAST-positive, FAST-equivocal, and FAST-negative. As a separate group unstable patients, defined as admitted to the ED hypotensive (systolic blood pressure 90 mm Hg), were analyzed. Need for emergency operation was recorded, and operative findings were noted.

RESULTS

Total 765 patients from 2010 to 2011 (One year period), were admitted to the trauma service. Total 73 out of 765 patients who underwent FAST ultrasound in the Emergency Room. 40 (54.79%) cases were road traffic accident (RTA) injuries followed by injury due to fall were in 33(45.20%) cases Fig-1.



Findings: Fast ultrasound observed 49 out of 73 patients (67.12%) were considered positive FAST who had fluid (blood) in the peritoneal cavity and these patients shift to Operative Room for surgery. While 24(32.87%) patients with no evidence of intra-peritoneal fluid were considered negative for FAST and these patient underwent CT scans for evidence of solid organ injury (Fig-2). 5 out of 24 cases of solid visceral trauma found on CT scan abdomen, but had not been detected by FAST then shift to operative room after resuscitation



DISCUSSION

Even for experienced surgeons it is difficult and a challenge for diagnosis of blunt abdominal trauma. Most of time, clinical findings are usually not reliable in blunt abdominal trauma. In Europe since the 1970s, Abdominal ultrasound (US) has been used to evaluate trauma patients⁸.

Fast ultrasound findings that help to take quick critical decisions like the need for surgery or conservative treatment are compulsory in blunt abdominal trauma patients. In our study findings were fast ultrasound observed 49 out of 73 patients (67.12%) were considered positive FAST who had fluid (blood) in the peritoneal cavity and these patients shift to Operative Room for surgery. According to these findings we save the time and quickly shifted the patients to Operative Room for surgery and to prevent further morbidity or mortality.

Historically, the presence of a intraperitoneal fluid due to abdominal injuries is significant and ensures immediate laparotomy. During the last decade, however, the practice of non-operative abdominal injuries in adults and children has increased⁹⁻¹¹.

The presence of free intra-peritoneal fluid in blunt abdominal trauma injury and absence of

detectable clinical solid organ damage creates a dilemma. There is a 25% chance of missing bowel injuries¹². While FAST ultrasound findings when negative and in haemodynamically stable patients advised CT scan in blunt abdominal trauma associated equivocal findings on physical examination, neurological injury or impaired sensorium due to drugs or alcohol, multiple extra-abdominal injuries¹³, and suspected the injury of duodenal or pancreatic organ¹⁴. CT scan is contraindicated in a blunt abdominal trauma patient with clear indication of laparotomy and in haemodynamically unstable patient.

While In our study 24(32.87%) patients with no evidence of intraperitoneal fluid were considered negative for FAST and these patient underwent CT scans for evidence of solid organ injury. 5 out of 24 cases of solid visceral trauma found on CT scan abdomen, but had not been detected by FAST then shifted to operative room after resuscitation.

Experience of the hand is a most important factor that affects the findings¹⁵. It was proven that the results of FAST are not different in the hands of surgeons, radiologists or emergency physicians if they were trained properly. This is essential to ensure the quality of health care given to patients. Fast Ultrasound save the time and give mostly accurate findings and make the decision to emergency shifting of patient to operative room or admit for conservative treatment.

CONCLUSIONS

FAST ultrasound is very helpful to assessment of blunt abdominal trauma and to detect intraabdominal fluid. Fast ultrasound can help in the quick decision for surgical intervention within minutes of a patient's arrival at emergency department.

Copyright© 16 Nov, 2013.

REFERENCES

- Holmes JF, Lillis K, Monroe D, Borgianni D, Kerrey BT, Mahajan P, et al. **Identifying Children at Very Low Risk of Clinically Important Blunt Abdominal Injuries.** Ann Emerg Med. Jan 29 2013.
- Pathan A. **Role of ultrasound in the evaluation of blunt abdominal trauma.** JLUMHS January – April 2005;23-8.
- Isenhour JL, Marx J. **Advances in Abdominal Trauma.** Department of Emergency Medicine, Carolinas Medical Center, 1000 Blythe Boulevard, Charlotte, NC 28203, USA.
- Faruque AV, Qazi SH, Khan MAM, Akhtar W, Majeed A. **Focused abdominal sonography for trauma (FAST) in blunt paediatric abdominal trauma.** J Pak Med Assoc March 2013;63(3):361-4.
- Rozycki GS, Newman PG. **Surgeon-performed ultrasound for the assessment of abdominal injuries.** Adv Surg 1999; 33: 243-59.
- Riley D, Ashar T, Ladner H, Darvish A. **Emergency Ultrasound Fellowship Symptom Based Multimedia Teaching Modules: A New and Innovative Method for Real World Emergency Ultrasound Education.** In: Third Annual Emergency Medicine Mediterranean Conference; 2005 Sep 2005. Poster Presentation; 2005.
- Farahmand N, Sirlin CB, Brown MA, Shragg GP, Fortlage D, Hoyt DB, et al. **Hypotensive Patients with Blunt Abdominal Trauma: Performance of Screening US.** J Radiology 2005;235:436-43.
- Blackbourne LH, Soffer D, McKenney MG, Amortegui J, Schulmon U, Crookes B, et al. **Secondary ultrasound examination increases the sensitivity of the FAST exam in blunt trauma.** J Trauma 2004; 57: 934-8.
- Cogbill TH, Moore EE, Jurkovich GJ, Morris JA, Mucha P Jr, Shackford SR, et al. **Nonoperative management of blunt splenic trauma: a multicenter experience.** J Trauma 1989;29(10):1312–7.
- Bose SM, Mazumdar A, Gupta R, Giridhar M, Lal R, Praveen BV. **Expectant management of haemoperitoneum.** Injury 1999;30(4):269–73.
- Minarik L, Slim M, Rachlin S, Brudnicki A. **Diagnostic imaging in the follow-up of nonoperative management of splenic trauma in children.** Pediatr Surg Int 2002;18(5–6):429–31.
- Mohamed M. Radwan, Fikri M. Abu-Zidan. **Focused Assessment Sonograph Trauma (FAST) and CT scan in blunt abdominal trauma: surgeon's perspective.** African Health Sciences 2006; 6(3):187-190.
- Peitzman AB, Makaroun MS, Slasky BS, Ritter P. **Prospective study of computed tomography in**

- initial management of blunt abdominal trauma.** J Trauma 1986; 26: 585-92.
14. Jayaraman MV, Mayo-Smith WW, Movson JS, Dupuy DE, Wallach MT. **CT of the duodenum: an overlooked segment gets its due.** Radiographics 2001 ;21 SpecNo:S147-60.
15. Thomas B, Falcone RE, Vasquez D et al. **Ultrasound evaluation of blunt abdominal trauma: program implementation, initial experience, and learning curve.** J Trauma. 1997 42:384-8..



Only those who dare to
fail greatly can ever
achieve greatly.

Robert F. Kennedy

