

BILATERAL ADDUCTOR ABCESS FOLLOWING GRION INJURY

Case Report
PROF-1840

DR. NABEEL DASTGIR

Associate Professor
Department of Trauma & Orthopaedics
Central Park Medical College, Lahore

DR. RIZWAN AHMED KHAN

Associate Professor
Department of Trauma & Orthopaedics
Central Park Medical College, Lahore

DR. KAMRAN KHALID BUTT

Assistant Professor
Department of Trauma & Orthopaedics
Central Park Medical College, Lahore

ABSTRACT... Pubic pain is a common symptom in athletes and in soccer players. Its cause can be difficult to determine. We report a case in a 14-year-old boy who presented with bilateral adductor muscle abscesses following a trivial injury to the groin. The etiology, radiological findings and treatment, along with literature review are discussed. **Introduction:** The main causes of pubic pain after sports are thought to be sports related microtrauma to the pubic rami or symphysis and lesions of the oblique, rectus or adductor muscles or their tendons^{1,2}. Osteitis pubis refers to a painful inflammation of the periosteum, bone, cartilage and ligamentous structures of the anterior half of the pelvis. Pubic osteomyelitis is an uncommon entity, accounting for less than 1% of all cases of Haematogenous osteomyelitis. We report a case of bilateral adductor muscle abscess six week after a trivial injury in sports.

Key words: Pubic Osteomyelitis, Adductor Abscess.

CASE REPORT

A 14 year old boy was admitted through the accident & emergency department with pain in the groin for the previous four weeks. The patient recalled initial groin strain 4 weeks ago after football game. He felt pain initially but was able to play a practice match afterwards. The pain gradually increased and was aggravated on walking. He also gave a history of difficulty and urgency of micturation. On admission he was feeling generally ill, with pyrexia of 37.8 degree C, loss of appetite, nausea and incapacitating pain in the groin radiating to both thighs and lower back. Clinical examination revealed bilateral tender, inflamed fluctuant swellings in the upper medial thigh (fig 1). Hip movements were restricted and painful. The erythrocyte sedimentation rate was 90 mm/h and the serum C-reactive protein was 129 mg/l. Urinalysis and other laboratory investigations were within normal limits, blood cultures were negative. Patient was commenced on intravenous flucloxacilline and fucidic acid. A plain radiograph of the pelvis revealed widening of the symphysis pubis. Ultrasound examination demonstrated a 4-cm complex fluid collection in the suprapubic region. MRI scan of pelvis confirmed the presence of a suprapubic fluid collection located above the symphysis pubis and also deep to the anterior abdominal wall. In addition MRI revealed fluid collections extending inferiorly from the symphysis into

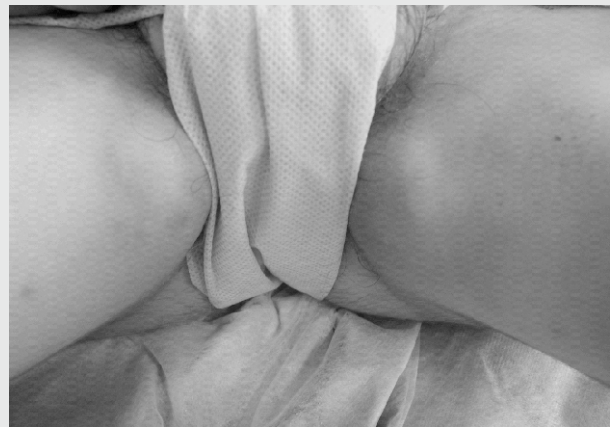

Fig-1.

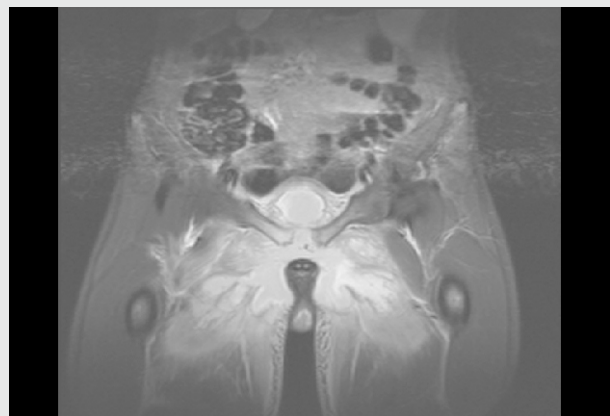


Fig-2

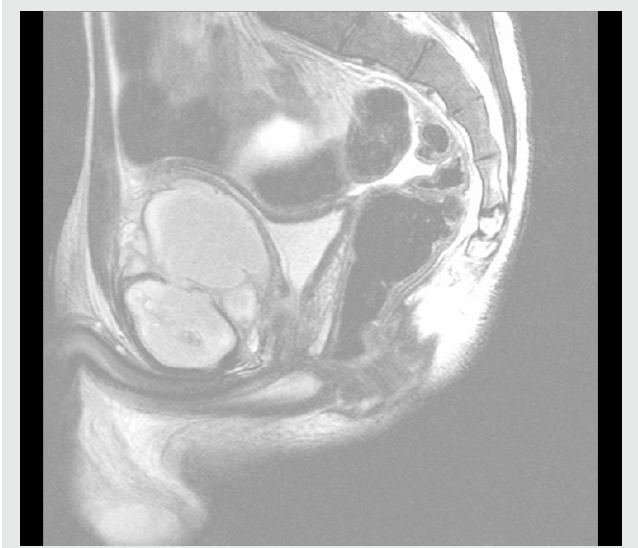

Fig-3.

the medial aspect of both thighs (fig 2,3).

Bilateral corrugated drain was left in situ. Cultures were positive for *Staphylococcus aureus*, sensitive to fucidin and flucloxacillin. Drains were taken out on the fourth postoperative day and the patient was discharged home on oral antibiotics for six weeks. The patient made uneventful recovery and at follow-up was asymptomatic.

DISCUSSION

Few cases of pyogenic pubic infection have been reported in athletes, accounting for < 1% of all cases of hematogenous osteomyelitis^{1,2}. Although rare, it has been well described in three settings; children in whom *Staphylococcus aureus* is the predominant pathogen³, elderly patients who have undergone genitourinary procedure⁴, parental drug abusers in whom *Pseudomonas aeruginosa* or other gram negative organism are the main causative organisms⁵. Athletes described in these case reports do not belong to any of the high risk groups. The most common presentation is pubic pain after a minor trauma or athletic injury. Presentation as bilateral adductor abscess has not been reported previously in literature. The early symptoms of pubic osteomyelitis mimic those of osteitis pubis. Osteitis pubis is a self-limiting condition, which has been described after genitourinary surgical intervention, in athletes and multiparous females⁸. Abscesses in the

muscles of the pelvic area are responsible for pubic pain, but usually occur after an invasive pelvic procedure such as transurethral resection of the prostate, hernia, child birth and gynecological procedures. The most common causative organisms are *Staphylococcus aureus* and *Streptococcus* including *Streptococcus pneumoniae*. The imaging findings in infective osteitis pubis occurring in athletes have been previously described^{3,4}.

Radiographs will initially be normal but within 2 to 4 weeks typically demonstrate symphyseal widening and subchondral lucency and erosions. Computer tomography will show these changes more accurately and confirm any abscess collection. Bone scintigraphy will demonstrate intense, abnormal uptake of radiotracer in the parasymphyseal pubic bone. Ultrasound examination can reveal abscess formation and confirm widening of the symphysis. MRI will display osseous and soft tissue changes including pubic bone osteomyelitis, symphyseal widening, and abscess formation.

Muscle enlargement and increased signal intensity in T1 and T2 weighted images have been reported in pyomyositis⁹. Antecedent trauma may be the most important etiologic factor in hematogenous osteomyelitis. Soft tissue lesions around the pelvis is common in athletes and radiographic changes have been documented in health athletes. Osteomyelitis involving the symphysis pubis has signs and symptoms similar to those of osteitis pubis i.e. anterior pelvic pain, spasm of the adductors and rectus abdominus muscles and waddling gait¹⁰. In contrast to osteitis pubis, the clinical course of osteomyelitis is progressive with increasing bone destruction and widening of the symphysis seen on radiographs. For this reason osteomyelitis is considered as a separate entity from that of osteitis pubis. The precise etiology of osteomyelitis of the pubic symphysis is unknown, but bacterial seeding of the pubis bone is felt to occur via transient bacteremia. It is hypothesized that athletic activity related microtrauma make muscles and bones more prone to bacterial infections, mainly in the setting of transient bacteremia.

To summarise pubic osteomyelitis should be suspected in athletes who have unexplained acute pubic and groin

pain especially after vigorous athletic activity.
Copyright© 11 Oct, 2011.

REFERENCES

1. Gibbon WW, Hession PR. **Diseases of the pubis and pubis symphysis: MRI Appearances.** A J Rad. 1997;169:849-53.
2. Godfroid, Stalens JP. **Thigh pain due to obturator internus phlegmon: a diagnostic challenge.** Eur J Paed. 1995;154:273-4.
3. Guis-Sabatier S et al. **Pubic Pain in athletes: a case due to an abscess in the Obturator muscle.** Rev. Rhum.(Engl.Ed), 1999,66(1),58-60.
4. Hedstrom SA, Lidgren I. **Acute hematogenous pelvic osteomyelitis in athletes.** Am J Sports Med 1982; 10:44-46.
5. Lopez-Guerra N, Garcia-Monco JC, Lario BA et al. **Osteomyelitis pubis in athletes.** J Rheumatology 1988; 15(3):530-532.
6. Ukwu HN, Graham BS, Latham RH. **Acute pubic osteomyelitis in athletes.** CID 1992; 15 (October) 636-638.
7. Sanchez EN, De Cal IW, Bernal NA et al. **Fusobacterium osteomyelitis of the pubic symphysis in a healthy soccer player.** J Rheumatology 2000; 27(3): 2047-2048.
8. Harris NH. **Lesions of the symphysis pubis in women.** BMJ 1974;4:209-11.
9. Gordon BA, Martinez S, Collins AJ. **Pyomyositis: characteristics at CT and MR imaging.** Radiology 1995;197:279-86.
10. Rosenthal RE et al. **Osteomyelitis of the Symphysis Pubis: A separate disease from Osteitis Pubis.**

Article received on: 07/09/2011

Accepted for Publication: 11/10/2011

Received after proof reading: 03/01/2012

Correspondence Address:

Dr. Nabeel Dastgir
 Consultant Trauma & Orthopaedics
 427 GG, Phase 4, DHA
 Lahore, Pakistan
 nabeeldastgir@gmail.com

Article Citation:

Dastgir N, Butt KK, Khan RA. Bilateral adductor abscess following grion injury. Professional Med J Feb 2012;19(1): 134-136.

The time to repair the roof
 is when the sun is shining.

John F. Kennedy