



## NON OPERATIVE TREATMENT; FUNCTIONAL OUTCOME OF RADIUS ULNA DIAPHYSEAL FRACTURES IN CHILDREN

Dr. Waqar Alam<sup>1</sup>, Dr. Faaziz Ali Shah<sup>2</sup>, Dr. Roohullah Jan<sup>3</sup>, Dr. Riaz-Ur-Rehman<sup>4</sup>

1. MRCS, FCPS (Orthopaedics), Consultant Orthopedic and Spine Surgeon DHQ Hospital Timergara, Distt: Dir Lower
2. FCPS (Ortho), Medical Officer, Orthopedics Unit, Mardan Medical Complex, Bacha Khan Medical College, Mardan KPK.
3. FCPS (Ortho), Medical Officer, Orthopedics and Trauma Unit, Khyber Teaching Hospital, Peshawar-Pakistan.
4. MRCS, IMM, FCPS I, Trainee Medical Officer, Neurosurgery Unit, Postgraduate Medical Institute, Hayat Abad Medical Complex, Peshawar-Pakistan.

#### Correspondence Address:

Dr. Waqar Alam  
Consultant Orthopedic and Spine Surgeon  
DHQ Hospital Timergara, Distt: Dir Lower  
waqaryousafzai@yahoo.com

Article received on:

03/09/2013

Accepted for Publication:

12/11/2013

Received after proof reading:

07/02/2014

**ABSTRACT... Background:** Pediatric forearm fractures result in substantial morbidity and costs. Despite the success of public health efforts in the prevention of other injuries, the incidence of pediatric forearm fractures is increasing. Most forearm fractures occurred during the spring season. Objective of the study is to determine the functional outcome of conservatively treated radius ulna fractures in Children. **Design:** Descriptive study. **Setting:** Department of Orthopedics and Traumatology, Khyber Teaching Hospital Peshawar. **Period:** March 2009 to April 2010. **Methodology:** Total 236 children with radius ulna fractures were manipulated and above elbow plaster Cast applied for 6-8 weeks and reviewed every second week. After plaster cast removal Pronation and supination measured with goniometer and fortnightly thereafter for 6 weeks. **Results:** All the fractures united. Normal range of pronation and supination at the end of follows up period was in 182(80.53%) children. Loss of pronation and supination of average 10 degrees were in 9(3.98%) patients. Patients having displacement of the fracture and opted for surgery were 35(15.46%). **Conclusions:** Closed reduction of diaphyseal fractures in children results in normal pronation and Supination in majority of the patients.

**Key words:** Radius ulna fracture, closed reduction, pronation and supination.

**Article Citation:** Alam W, Shah FA, Jan R, Riaz-ur-Rehman. **Non operative treatment;** functional outcome of radius ulna diaphyseal fractures in children. Professional Med J 2014;21(1): 016-019.

### INTRODUCTION

Pediatric forearm fractures result in substantial morbidity and costs. Despite the success of public health efforts in the prevention of other injuries, the incidence of pediatric forearm fractures is increasing. Most forearm fractures occurred during the spring season. The most common mechanism of injury was fall-related (83%) whereas direct trauma caused 10% of fractures. "Fall from monkey bars" was the specific mechanism of injury in 17% of all cases. The majority of forearm fractures (58%) resulted from minor trauma<sup>1</sup>. Childhood injuries contribute significant morbidity and mortality in Pakistan as well. A large proportion of falls is characteristics of childhood injury profile in our country at all locations - home, outside the building and in school<sup>2</sup>. Forearm shaft fractures are the third most common fracture in children. Although closed

reduction and casting is the preferred treatment; outcomes remain variable<sup>3</sup>. Closed reduction and casting are the primary means of treatment in over 90% forearm fractures in children<sup>4</sup>. Most displaced fractures of the forearm are best maintained in a long arm cast. However, redisplacement occurs in 7 to 13% of cases, usually within 2 weeks of injury. Unstable metaphyseal fractures should be percutaneously pinned. Unstable diaphyseal fractures can be stabilized by intramedullary fixation of the radius and ulna. If none of these techniques is helpful, plate and screw fixation is the best choice.

### METHODOLOGY

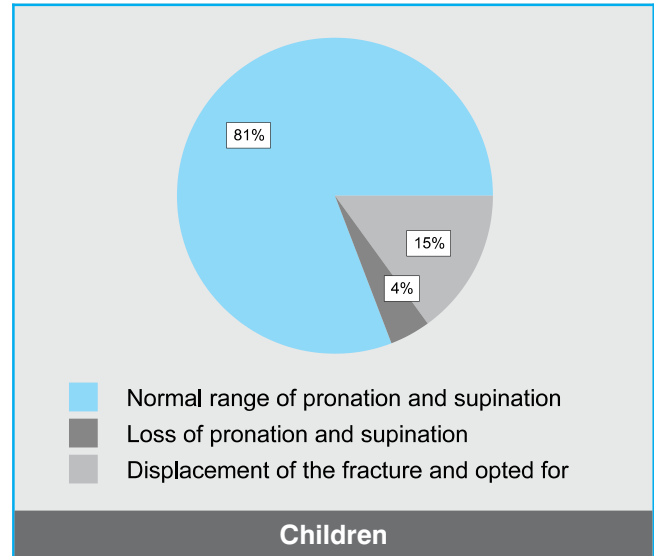
Total of 226 children of both genders with mean age of 7 years (range 4-16 years) with radius ulna fractures from OPD and Accident and Emergency department were included in the study. Closed

reduction was done and above elbow plaster of Paris cast was applied for 6-8 weeks. Children who had displaced fractures manipulated under intravenous sedation and cast applied. Children with open fractures, head injury, single bone fracture, and polytrauma patients were excluded from the study. X-ray of the forearm was taken to confirm the diagnosis. After informed written consent from the parents, fractures were manipulated under intravenous sedation where needed and above elbow plaster cast given. Check X-ray was done. Fractures were classified as proximal, middle, or distal, based on one-third division of the shaft. Thresholds for maximum acceptable angulation for male patients < 10 years and female patients < 8 years were as follows: 10 degrees for proximal-third, 15 degrees for middle-third, 20 degrees for distal-third fractures; for female patients ≥ 8 years and male patients ≥ 10 years, up to 10 degrees was considered acceptable at all the level<sup>5</sup>. Patients were discharged home and advised for follow up every 2nd week till plaster removal at 6 weeks and pronation and supination measured thereafter for 6 weeks. Data was entered into SPSS version 11. Mean, mode, median calculated. Data presented in tables and graphs.

**RESULTS**

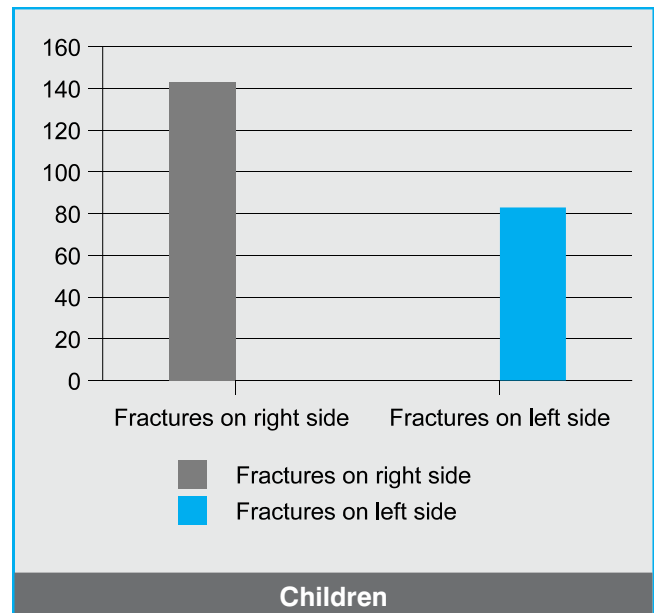
Total 226 Children of both genders were included in our study. Male were 167(73.89%).The mean age was 7 years (range 4-16 years). All the fractures were united. Normal range of pronation and supination at the end of follows up period was in 182(80.53%) children. Loss of pronation and supination of average 10 degrees were in 9(3.98%) patients. Patients having displacement of the fracture and opted for surgery were 35(15.46%).

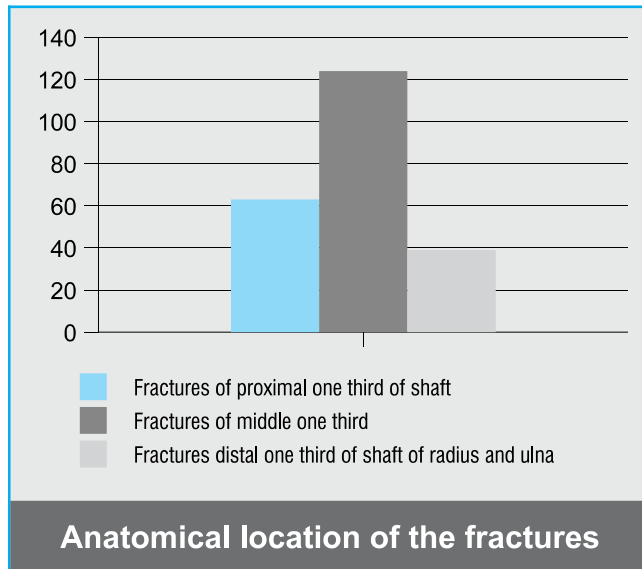
There were multiple causes for fractures in these children. Most children had history of fall during sports and other physical activities while some had history of Road Traffic Accidents, Physical assaults and other miscellaneous causes. Fractures were more on the Right side then the Left side. Patients having fractures on right side were 143(63.27%) while patients having fractures on left



side were 83(36.73 %).

Patients having fractures of proximal one third of shaft were 63(27.86 %), 124(54.87 %) patients had fractures of middle one third while 39(17.26 %) patients had fractures distal one third of shaft of Radius and Ulna. The success rate of conservative treatment was more in middle and distal third fractures while fractures of proximal third were more unstable in our study.





## DISCUSSION

The majority of the pediatric diaphyseal forearm fractures are treated with closed reduction and the application of an above elbow cast for a varying period, depending on the age of the child<sup>7</sup>. The goal when treating shaft fractures of the forearm bones is to obtain good bone healing with good preservation of upper limb function<sup>8</sup>. In our study normal pronation and supination was achieved in majority (42) of our patients. Tarmuzi NA, Abdullah S, reported that 86% of the patients had excellent functional outcomes and none had poor outcomes. There were significantly reduced angles of deformities before and after treatment ( $p < 0.05$ ). The level of fracture did not influence the outcomes. They concluded that conservative treatment is still an acceptable form of treatment especially for stable forearm fractures in children achieving excellent outcomes<sup>9</sup>. In our study 6 patients had lost reduction of their fractures and opted for surgery. One study observed 3 cases (4%) of secondary displacements under plaster<sup>10</sup>.

We applied an above elbow plaster cast for forearm fractures after manipulation while Webb GR and Galpin RD stated that A well-molded short arm cast can be used as effectively as a long arm cast to treat fractures of the distal third of the forearm in children four years of age and older, and they interfere less with daily activities<sup>11</sup>. Similarly Bohm ER and Bubbar V documented that Below-

the-elbow casts perform as well as above-the-elbow casts in maintaining reduction of fractures in the distal third of the forearm in children, and the complication rates are similar. Factors that are associated with a higher risk of loss of reduction include combined radial and ulnar fractures and residual angulation of the fracture after the initial reduction<sup>12</sup>.

Two of our patients had loss of pronation and supination of average 10 degrees at the end of follow up period. Similar to our study Zionts LE and Zalavras CG reported loss of forearm supination and pronation averaged 4 degrees (range 0 to 20 degrees) and 6.8 degrees (0 to 40 degrees), respectively. But this study had mean age 13.3 years, range 8.8-15.5 with follow up period of 49.6 weeks. These authors, however concluded that Closed reduction and casting of displaced both-bone diaphyseal forearm fractures, despite the residual angulation, results in satisfactory functional outcome and should remain a viable treatment option in the management of this injury<sup>13</sup>.

Our study had smaller number of patients and with shorter follow up period. Further studies with larger sample size and longer follow up period are recommended to further confirm our findings.

## CONCLUSIONS

Based upon the findings of our study, we can conclude that conservatively managed forearm fractures in children yielded excellent functional results. We therefore recommend conservative treatment as a method of choice for treating forearm fractures in children.

Copyright© 12 Nov, 2013.

## REFERENCES

1. Ryan LM, Teach SJ, Searcy K, Singer SA, Wood R, Wright JL, Chamberlain JM. **Epidemiology of pediatric forearm fractures in Washington, DC. J Trauma.** 2010;69(4 Suppl):S200-5.
2. Rehmani, R., **Childhood injuries seen at an emergency department.** J Pak Med Assoc 2008; 58(3): 114-118.
3. Bowman EN, Mehlman CT, Lindsell CJ, Tamai J.

- Nonoperative treatment of both-bone forearm shaft fractures in children: predictors of early radiographic failure.** J Pediatr Orthop. 2011;31(1):23-32.
4. Tarmuzi NA, Abdullah S, Osman Z, Das S. **Paediatric forearm fractures: functional outcome of conservative treatment.** Bratisl Lek Listy. 2009;110(9):563-8.
  5. Rodríguez-Merchán EC. **Pediatric fractures of the forearm.** Clin Orthop Relat Res.2005;(432):65-72.
  6. Bowman EN, Mehlman CT, Lindsell CJ, Tamai J. **Nonoperative treatment of both-bone forearm shaft fractures in children: predictors of early radiographic failure.** J Pediatr Orthop. 2011;31(1):23-32.
  7. Garg NK, Ballal MS, Malek IA, Webster RA, Bruce CE. **Use of elastic stable intramedullary nailing for treating unstable forearm fractures in children.** J Trauma.2008;65(1):109-15.
  8. Mseddi MB, Manicom O, Filippini P, Demoura A, Pidet O, Hernigou P. **[Intramedullary pinning of diaphyseal fractures of both forearm bones in adults: 46 cases].** Rev. Chir-orthop. Reparatrice Appar Mot. 2008; 94 (2):160-7.
  9. Tarmuzi NA, Abdullah S, Osman Z, Das S. **Paediatric forearm fractures: functional outcome of conservative treatment.** Bratisl Lek Listy. 2009;110(9):563-8.
  10. Ouattara O, Kouame BD, Odehouri TH, Gouli JC, Yao K, Dick RK. **[Results of treatment of forearm fractures in the child].** Mali Med. 2007;22(3):43-6.
  11. Webb GR, Galpin RD, Armstrong DG. **Comparison of short and long arm plaster casts for displaced fractures in the distal third of the forearm in children.** J Bone Joint Surg Am. 2006;88(1):9-17.
  12. Bohm ER, Bubbar V, Yong Hing K, Dzus A. **Above and below-the-elbow plaster casts for distal forearm fractures in children. A randomized controlled trial.** J Bone Joint Surg Am. 2006 ;88(1):1-8.
  13. Zions LE, Zalavras CG, Gerhardt MB. **Closed treatment of displaced diaphyseal both- bone forearm fractures in older children and adolescents.** J Pediatr Orthop. 2005;25(4):507-12.

*“Whatever is begun in anger  
ends in shame.”*

*Sir Winston Churchill (1874-1965)*