

“WHEAT PILL (ALUMINUM PHOSPHIDE) POISONING”;

Commonly ignored dilemma. A comprehensive clinical review

Muhammad A. Ghazi

ABSTRACT... Purpose: The number of deaths due to wheat pill poisoning is enormous and despite aggressive management only a few patients survive the fatal effects of the wheat pill poison. Despite the growing number of patients appearing in the emergency departments with this easily available poison in the market, very little effort has been put forth to study the subject scientifically and to prevent the ongoing loss of precious lives. This is a narrative review of the wheat pill poisoning, highlighting the important steps in diagnosis and management. **Methods:** Data sources include Pubmed, Scopus, Medline (1996 to date), Cochrane library and Google scholar. We included all clinical trials, systematic reviews and ongoing cohort studies. **Conclusions:** Wheat pill (Aluminum Phosphide) poisoning is a lethal toxin and its effective treatment requires prompt diagnosis and early, time-efficient management. Early transfer to a healthcare facility, good resuscitation, diagnosis, monitoring, gastric lavage and supportive therapy are the hallmarks of management and may result in improved outcomes. The governmental and legislative authorities must take appropriate steps towards limiting its availability at the grass-roots level. Aluminum Phosphide poisoning must be a part of the medical students’ curriculum and long-term, well-designed comprehensive research studies are required to discover new modalities of treatment.

Key words: Aluminum Phosphide, Wheat pill, rice tablet or pill, Poisoning

Article Citation

Ghazi MA. “Wheat pill (aluminum phosphide) poisoning”; Commonly ignored dilemma. A comprehensive clinical review. Professional Med J 2013;20(6): 855-863.

INTRODUCTION

“Wheat pill” or Aluminum Phosphide (AIP) poisoning is rampant in the northern Indian subcontinent and many other parts of Asia, especially South Asia. It is also known as “rice pill” in some parts of the world. It is used as a rodenticide to prevent the wheat and rice infestation in agricultural countries. It is widely used in several developing countries like Pakistan, India, Iran, Morocco and Nepal. We do not have exact statistics for the global impact of the acute poisoning from these pills, but it can be safely said that it proves fatal in most of the cases. The incidence of Aluminum Phosphide poisoning is increasing in Pakistan as it is a cheap and readily available poison used for the suicide¹. No effective antidote exists to date and most of the treatment is supportive and symptom driven. The purpose of this article is to enlighten the readers about the underlying pathophysiology and effective management of the emergent cases by prompt diagnosis and quality supportive critical care.

The most common form of ingestion reported is suicidal, followed by accidental ingestion or

occupational exposure. Accidental cases have been reported in developed countries like the United States and several European countries where it is used as a rodenticide and a fumigant.

Methods

The terms Aluminum Phosphide, Zinc Phosphide and Phosphine were searched in data sources including Pubmed, Scopus, Medline (1996 to date), Cochrane library and Google scholar. We included all clinical trials, systematic reviews and ongoing cohort studies.

Epidemiology and magnitude of the problem

According to Mehrpour et al. the Aluminum Phosphide poisoning accounts for 25 % of all suicide attempts in India and 31% of the fatal suicide attempts in Iran². In a large study done in India, the mortality was reported as 60%³. The exact figures for the Pakistani population are not available. In European countries the sale of Aluminum Phosphide pills is restricted to qualified users, however rare cases of poisoning have been reported in Denmark, UK and France. In the developed world, most of the cases are due to accidental

exposure to fumigants such as improper storage and disposal, re-entry in the fumigant structures and drift from the agricultural fields⁴. The lethal dose is reported to be 0.5 grams². Survival chances are meager for ingestion of more than 1.5 grams. In a case study done in a tertiary care hospital at Lahore, there was a mortality rate of 70%¹ and another study also reports a mortality rate of 55-90%⁵.

Most of the patients with wheat pill poisoning are young, with mean age reported to be 25 ± 5 years in a study done in Pakistan⁵.

What is a wheat pill?

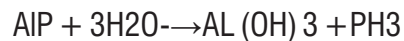
Wheat pills or rice pills are commonly available pesticides which are composed of Aluminum Phosphide or Zinc Phosphide. The pill is composed of about 44% inert ingredients to prevent decomposition of the tablet, while Aluminium Phosphide is about 56% of the pill. It is also available in the form of pellets, sachets and powder. The common trade names include Celphos, Alphos, Quickphos, Phostek, Delicia and Chemfume⁶.



Picture-1. Commercially available Aluminum Phosphide pills

Aluminium Phosphide is highly water soluble and decomposes in the presence of moisture. The

chemical reaction between water (H₂O) and aluminum Phosphide (AIP) liberates the phosphine gas (PH₃) which is highly toxic. Exposure to 1400 mg/m³ or 1000ppm is usually fatal.



Aluminum Phosphide is used as a fumigant, rodenticide, pesticide and semiconductor.

Pathophysiology of Aluminum Phosphide poisoning

Aluminum Phosphide releases phosphine after oral ingestion, which alters the conformation of mitochondria and inhibits oxidative respiration up to 70%⁷.

The effect of phosphine on the cellular mechanisms has been postulated by three ways: a) inhibition of acetylcholinesterase, b) inhibition of peroxidase and/or c) inhibition of glycerol phosphate dehydrogenase. In vitro studies of phosphine have shown that it acts on the complex IV cytochrome oxidase to inhibit the electron transport chain and therefore mitochondrial function. Cellular oxidative stress is caused by the generation of reactive oxygen species (ROS) [i.e., superoxide (SO₂-) and hydrogen peroxide (H₂O₂)] and reactive nitrogen species (RNS), predominantly nitric oxide (NO). These are highly damaging to the cell leading to eventual cell death⁸. Acetylcholine is an excitatory neurotransmitter and therefore the inhibition of esterase results in an excitatory state, which is commonly manifested in the form of seizures. Inhibition of cytochrome oxidase results in the failure of several metabolic pathways at the cellular level as well as the destabilization of cell membranes.

Clinical symptoms

Common clinical effects of Aluminum Phosphide ingestion include gastritis, hepatic necrosis, cardiac arrhythmia, metabolic acidosis, congestive heart failure and hypotensive shock. According to Iftikhar et

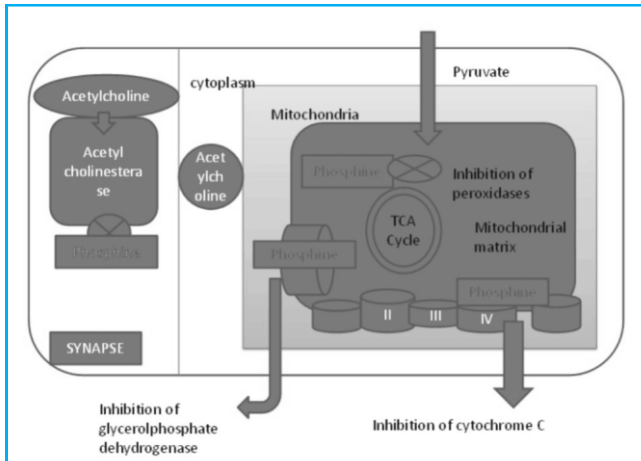


Fig-1. An illustration of the effects of Phosphine cellular mechanisms⁹ (Adapted with changes)

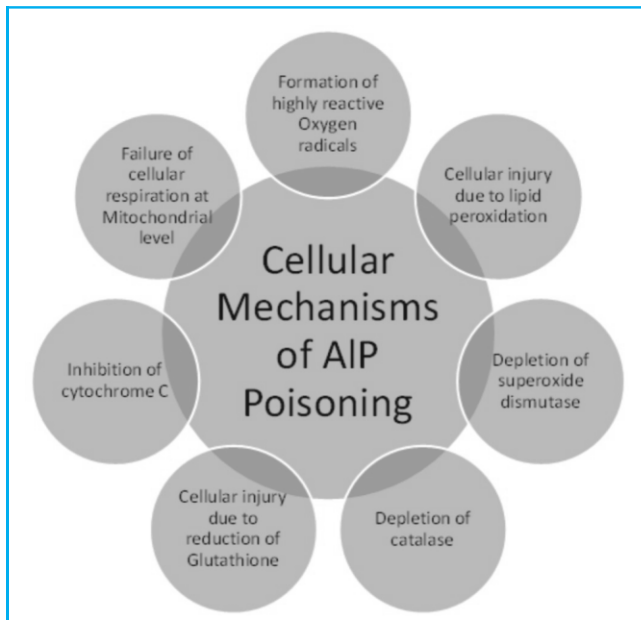


Fig-2. Cellular mechanisms of Aluminum Phosphide poisoning

al., the more common presenting complaints were hypotension followed by vomiting⁵. The common signs and symptoms of AIP poisoning are summarized in the table below:

Gastrointestinal	Nausea and vomiting Thirst Epigastric burning Abdominal cramps Hepatic tenderness Acute pancreatitis
Cardiovascular	Hypotension Bradycardia Tachycardia Shock Chest tightness
Pulmonary	Dyspnea Cough Pulmonary edema Pleural effusions
Renal	Oliguria Proteinuria Hematuria Acute renal failure
Nervous System	Anxiety Restlessness Seizure Coma
Electrolyte imbalance	Hypomagnesemia Hypokalemia Hyperkalemia Metabolic acidosis
Endocrine system	Hypoglycemia Hyperglycemia

Table-I. Categorization of Clinical symptoms and signs according to the organ system involved

Several studies show that phosphides denature hemoglobin to form Heinz bodies. There is intravascular hemolysis and methemoglobinemia on exposure to phosphine⁹ and disseminated intravascular coagulation is a potential complication of AIP poisoning.

Cardiovascular effects include raised jugular venous pressure, feeble heart sounds, S3 gallop rhythm, broad complex tachycardia¹⁰, T-wave abnormality and markedly reduced LV diastolic function on

echocardiogram¹¹. Cases have been reported of sub-endocardial infarction¹². In the case of acute poisoning, antero-inferior ischemia associated with incomplete right bundle branch block can lead to idioventricular rhythm and T wave changes which are secondary to myocardial toxicity. Signs of poor prognosis include hypotension, acidosis and early shock⁶. Inhalation of phosphine or its formation after ingestion of AIP results in the irritation of the pulmonary membranes leading to pulmonary edema. The patient may develop acute respiratory distress syndrome (ARDS). Gastric and duodenal inflammation and bleeding has been reported in several cases of oral ingestion¹³.

Metabolic acidosis or a mixed metabolic acidosis and respiratory alkalosis are frequently seen shortly after the acute AIP poisoning⁹. Hypokalemia and hypomagnesemia are common electrolyte abnormalities and should be monitored. Adrenal cortex involvement is common and leads to necrosis of the adrenal glands. An increase in plasma cortisol levels is observed in the early phase of AIP poisoning, followed by steadily low cortisol levels in critically ill patients¹⁴. Plasma renin activity is high in acute poisoning and has a direct correlation with increased mortality¹⁵. Rarely, microangiopathic hemolytic anemia and disseminated intra-vascular hemolysis are seen in Aluminum Phosphide poisoning.

Histopathological evidence of organ damage from Aluminum Phosphide Poisoning

The liver shows histo-pathological changes like central venous congestion and mononuclear infiltration of hepatocytes. Kidneys develop congestion in the glomerulus and parenchyma. Brain histology reveals degeneration of Nissl granules and degenerated nuclei in the cortex. Lungs show alveolar thickening and dilated capillaries. Varying degrees of edema, congestion and leukocytic infiltration, suggestive of cellular hypoxia, are seen in lungs, liver, kidney, brain, adrenals, stomach and heart. Lungs, kidneys and adrenal glands are the most extensively

affected organs¹⁶.

Long term complications of AIP ingestion

Esophageal strictures can lead to dysphagia in survivors¹⁷. Death is a common result of Aluminum Phosphide poisoning, usually occurring within 24-48 hours⁵. However, other studies have shown mortality within four days.

Management of Acute Aluminum Phosphide poisoning

There is no specific antidote for Aluminum Phosphide poisoning and most of the treatment is supportive. The foremost supportive measures include Circulation, Airway, and Breathing (CAB). The patient should be assessed for neurological deficits and must be removed from the source of poisoning to avoid ongoing exposure. Aluminum phosphate can be absorbed directly through the skin, therefore the exposed must be washed with soap and water. Medical and first aid teams must take precautionary measures to avoid exposure to the poison. An IV line should be established and the patient should be given a bolus of 0.9% normal saline to avoid hypotension.

A Silver Nitrate test can be done to confirm the diagnosis after a careful history. Silver Nitrate impregnated paper is exposed to the patient's breath or gastric contents, which turns black after exposure to Silver Phosphide, which is formed from the reaction between phosphides and Silver Nitrate. This test strip can be used to check the breath (50% sensitive) and gastric contents (100% sensitive)¹⁸.

Serial blood levels of Phosphine (PH₃) can be monitored during the acute intoxication. These levels correlate with the severity of Aluminum Phosphide toxicity¹⁹. Other tests include complete blood count, hemoglobin and hematocrit, arterial blood gases, coagulation profile, and renal and liver function tests. Chest x-rays and electrocardiography are also required to assess lung and heart function.

Gastric lavage with Potassium permanganate and mineral oil or coconut oil has been shown to reduce morbidity²⁰. A recent case report has described the usefulness of the gastric ventilation technique. A nasogastric tube is inserted to insufflate the air in the distal part of stomach, while an oro-gastric tube is inserted to serve as an inflow tube. An air-pump is used to blow air in the naso-gastric tube while Phosphine-contaminated air comes out of the oro-gastric tube. Further clinical trials are required to assess the usefulness of the technique²¹.

For nausea and vomiting, metoclopramide or ondansetron can be used and repeated as needed. For severe metabolic acidosis Sodium Bicarbonate should be used. Hypotensive shock due to wheat pill poisoning usually requires plenty of fluids and is mostly refractory. IV fluid therapy should be guided by central venous pressure (CVP) and a pulmonary capillary wedge pressure (PCWP). The CVP should be aimed between 12-14 cm of water. The systolic blood pressure should be kept above 90mmHg by low dose dopamine (at 4-6 µg/kg/min) in case of hypotension resistance to fluids. Hydrocortisone 200-400mg q 4-6 hours given via IV helps to reduce the dose of dopamine and prevents capillary leakage in the lungs to prevent Acute Respiratory Distress Syndrome (ARDS).

Diuretics like Furosemide can be given if the systolic BP is >90mmHg to enhance the elimination of phosphine through the renal route. Bicarbonate levels less than 15 mEq/L should prompt the use of IV Sodium Bicarbonate 50-100 mEq q 8 hours. The target bicarbonate level should be 18-20 mEq/L. A few case reports have shown the role of Digoxin in the management of refractory cardiac shock²².

In acute Aluminum Phosphide poisoning the most common cause of mortality within 12-24 hours of presentation is usually of a cardiovascular cause such as hypotensive shock and/or arrhythmias. After 24

hours, liver failure is the usual cause of death⁵. All patients with AIP poisoning should be on a cardiac monitor and electrolytes, such as Potassium and Magnesium, should be checked frequently and replaced accordingly. Low Magnesium may lead to Torsades de Pointes and ventricular fibrillation. These conditions should be managed according to the ACLS guidelines. According to Siwach et al., Magnesium replacement is the only intervention shown to reduce the mortality in the AIP poisoning²³. However, the clinical utility of Magnesium replacement has been debatable. Magnesium replacement has been shown to provide an anti-peroxidant effect and also stabilizes the cell membranes to eliminate the risk of wide complex arrhythmias and Torsades de Pointes. Chugh et al. showed that Magnesium combats the free radical stress slowly and independently of phosphine elimination²⁴.

There are case reports of arrhythmias such as the Brugada pattern of toxic myocarditis in AIP poisoning²⁵. Heart failure is evident with acute pulmonary edema²⁶. Hypotensive shock can be treated with inotropic support, Digoxin and Trimetazidine. Trimetazidine is useful to stop ventricular ectopic beats and bigeminy and preserves the oxidative metabolism². Siaddiah et al. reported the use of an intra-aortic balloon pump for cardiogenic shock in AIP poisoning²⁷.

There have been case reports of the useful effects of coconut oil in the management of acute poisoning from AIP. Shahdina et al.,²⁰ showed that coconut oil decreases the absorption of phosphine, which is formed after the ingestion of AIP. Coconut oil has shown to be effective even 6 hours after the acute ingestion of Aluminum Phosphide. There are some animal studies which show that hyperbaric oxygen therapy may improve survival in the animal exposed to Aluminum Phosphide. N-acetylcysteine (NAC) is an antioxidant and is postulated to reduce the mortality in cases of acute Aluminum Phosphide poisoning. In a

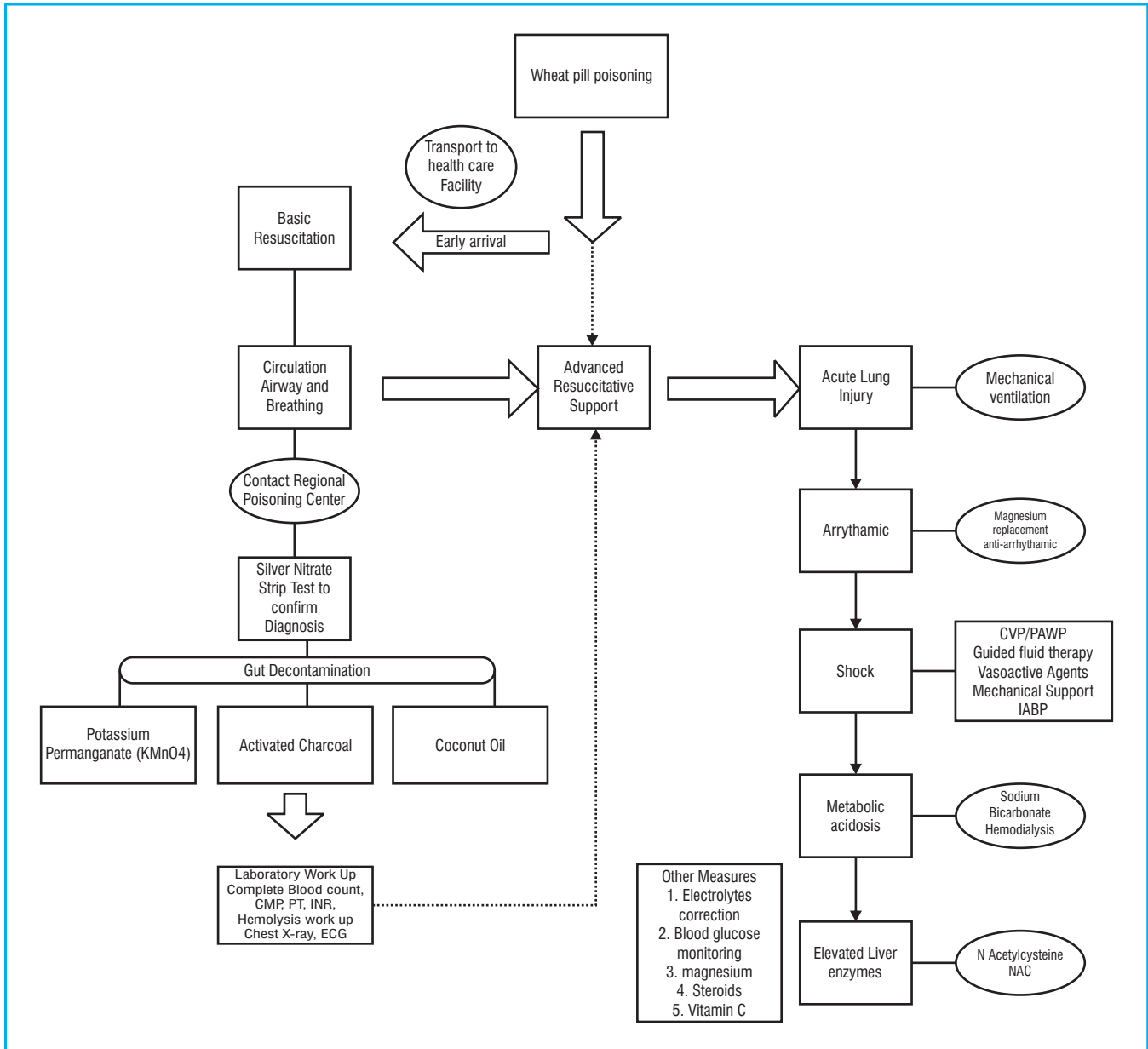


Fig-3. Management of acute Aluminum Phosphide Poisoning - A summary of basic and advanced resuscitative measures (CVP = Central venous Pressure, PCWP = Pulmonary Capillary Wedge Pressure, IABP = Intra-aortic Balloon Pump)

randomized controlled trial done in Iran²⁸, NAC reduced the duration of hospitalization, need for intubation and ventilation, and mortality.

A systematic scheme for the management of wheat pill poisoning is given in the Figure 3.

All survivors of the Aluminum Phosphide poisoning with a history of intentional ingestion should be evaluated by a psychiatrist for the evaluation of depression and other underlying psychosocial issues.

Prognosis

Patients with AIP poisoning have a poor prognosis with

mortality reaching up to 70%¹. Presence of ECG abnormalities and the need for mechanical ventilation are poor predictors of the outcome²⁹. A list of poor prognostic signs is tabulated below³⁰.

High APACHE II (“Acute Physiology and Chronic Health Evaluation II”) score
Low Glasgow coma scale score
Shock
ECG (electrocardiograph) changes
Low prothrombin rate
Hyperleukocytosis
Use of mechanical ventilation
Use of vasoactive drugs
Table-II. Poor Prognostic signs in Wheat pill poisoning

Poison Center resources

1. World health Organization Directory of Poison Centers available at http://www.who.int/gho/phe/chemical_safety/poisons_centres/en/
2. Jinnah Postgraduate Medical Centre toll-free telephone number (0800-77767)
3. American association of poison control centers 1-800-222-1222

Prevention recommendations

The supply of Aluminum Phosphide tablets should be restricted to farmers and must be issued under a special license. Easy access and availability markedly increased mortality due to poisoning. Steps should be taken at all levels to educate the masses about the deadly effects of these fumigants and appropriate protocols should be instated to prevent future damage.

1. Fumigants like Aluminum Phosphide should not be kept in the homes.
2. People handling these fumigants must be

3. educated about their harmful effects.
3. Law enforcement agencies should restrict the open sale of these pesticides and fumigants to everyone.
4. Vendors and shopkeepers should restrict selling these pills to underage children, and therefore require proper verification of age.

CONCLUSIONS

Aluminum Phosphide (wheat pill) is a dangerous and lethal poison and the symptoms progress quickly to death and there is no antidote for this poison. Therefore, an effective strategy is the early transport to a tertiary healthcare facility with good supportive care. There is limited data about the exact prevalence and therapeutic measures of wheat pill poisoning, therefore large-scale studies are required to improve the survival from the exposure to this dangerous poison.

ACKNOWLEDGMENT

The written would like to thank Jennifer Harb and Sanjay Jain for providing technical support in the process of review.

Copyright© 27 Aug, 2013.

REFERENCES

1. Khan, Z.U. **Rise in wheat pill poisoning: study.** Dawn 1/20/2013]; Available from: <http://arcliives.dawn.com/archives/70423>.
2. Mehrpour, O., M. Jafarzadeh, and M. Abdollahi, **A systematic-review of aluminium phosphide poisoning.** Arh Hig Rada Toksikol, 2012. 63(1): p. 61-73.
3. Siwach, S.B. and A. Gupta, **The profile of acute poisonings in Harayana-Rohtak Study.** J Assoc Physicians India, 1995. 43(11): p. 756-9.
4. Burgess, J.L., et al., **Fumigant-related illnesses: Washington State’s five-year experience.** J Toxicol Clin Toxicol, 2000. 38(1): p. 7-14.

5. Iftikhar R., T.K.M., Saeed F., et al., **WHEAT PILL: CLINICAL CHARACTERISTICS AND OUTCOME.** Pakistan Armed Forces Medical Journal, 2011. September (3).
6. Gurjar, M., et al.. **Managing aluminum phosphide poisonings.** J Emerg Trauma Shock, 2011. 4(3): p. 378-84.
7. Moghadamnia, A.A., **An update on toxicology of aluminum phosphide,** Daru, 2012. 20(1): p. 25.
8. Nath, N.S., et al. **Mechanisms of phosphine toxicity.** J Toxicol, 2011. 2011: p. 494168.
9. Proudfoot, A.T. **Aluminium and zinc phosphide poisoning.** Clin Toxicol (Phila), 2009. 47(2): p. 89-100.
10. Bogle, R.G., et al.. **Aluminium phosphide poisoning.** Emerg Med J, 2006. 23(1): p. e3.
11. Gupta, M.S., A. Malik, and V.K. Sharma, **Cardiovascular manifestations in aluminium phosphide poisoning with special reference to echocardiographic changes.** J Assoc Physicians India, 1995. 43(11): p. 773-4, 779-80.
12. Kaushik, R.M., R. Kaushik, and S.K. Mahajan, **Subendocardial infarction in a young survivor of aluminium phosphide poisoning.** Hum Exp Toxicol, 2007. 26(5): p. 457-60.
13. Chhina, R.S., R. Thukral, and L.S. Chawla, **Aluminum phosphide-induced gastroduodenitis.** Gastrointest Endosc, 1992. 38(5): p. 635-6.
14. Chugh S.N., et al. **Adrenocortical involvement in aluminium phosphide poisoning.** Indian J Med Res, 1989. 90: p. 289-94.
15. Chugh, S.N., et al. **Plasma renin activity in shock due to aluminium phosphide poisoning.** J Assoc Physicians India, 1990. 38(6): p. 398-9.
16. Arora, B., et al., **Histopathological changes in aluminium phosphide poisoning.** J Indian Med Assoc, 1995. 93(10): p. 380-1.
17. Jain, R.K., et al., **Esophageal complications following aluminium phosphide ingestion: an emerging issue among survivors of poisoning.** Dysphagia, 2010. 25(4): p. 271-6.
18. Chugh, S.N., et al.. **Spot diagnosis of aluminium phosphide ingestion: an application of a simple test.** J Assoc Physicians India, 1989. 37(3): p. 219-20.
19. Chugh, S.N., et al.. **Serial blood phosphine levels in acute aluminium phosphide poisoning.** J Assoc Physicians India, 1996. 44(3): p. 184-5.
20. Shadnia, S., et al., **Successful treatment of acute aluminium phosphide poisoning: possible benefit of coconut oil.** Plum Exp Toxicol, 2005. 24(4): p. 215-8.
21. Hassanian-Moghaddam, H. and A. Shahbazi, **Gastric ventilation: a new approach to metal phosphide fumigant ingestion.** Clin Toxicol (Phila), 2012. 50(5): p. 435-7.
22. Sanaei-Zadeh, H. and H. Farajidana, **Is there a role for digoxin in the management of acute aluminum phosphide poisoning?** Med Hypotheses, 2011. 76(5): p. 765-6.
23. Siwach, S.B., P. Singh, and S. Ahlawat, **Magnesium in aluminium phosphide poisoning--where have we erred?** J Assoc Physicians India, 1994. 42(3): p. 193-4.
24. Chugh, S.N., et al., **A critical evaluation of anti-peroxidant effect of intravenous magnesium in acute aluminium phosphide poisoning.** Magnes Res, 1997. 10(3): p. 225-30.
25. Nayyar, S. and M. Nair, **Brugada pattern in toxic myocarditis due to severe aluminum phosphide poisoning.** Pacing Clin Electrophysiol, 2009. 32(11): p. e16-7.
26. Alter, P., W. Grimm, and B. Maisch, **Lethal heart failure caused by aluminium phosphide poisoning.** Intensive Care Med, 2001. 27(1): p. 327.
27. Siddaiah, L., et al., **Intra-aortic balloon pump in toxic myocarditis due to aluminum phosphide poisoning.** J Med Toxicol, 2009. 5(2): p. 80-3.
28. Tehrani, H., et al., **Protective effects of N-acetylcysteine on aluminum phosphide-induced oxidative stress in acute human poisoning.** Clin Toxicol (Phila), 2012.

29. Nejad FT, M.A., Behnoush B, et al., **Predictors of Poor Prognosis in Aluminum Phosphide Intoxication.** Iranian Journal of Toxicology, 2012. 6(16): p. 610-614.

30. Louriz, M., et al., **Prognostic factors of acute aluminum phosphide poisoning.** Indian J Med Sci, 2009. 63(6): p. 227-34.

AUTHOR(S):

1. **MUHAMMAD A. GHAZI, MD**
Clinical Instructor
Department of Family Medicine
University at Buffalo

Correspondence Address:

Muhammad A. Ghazi, MD
Clinical Instructor
Department of Family Medicine
University at Buffalo
drmaghazi@gmail.com

Article received on: 23/07/2013
Accepted for Publication: 27/08/2013
Received after proof reading: 03/12/2013

