



DENTIGEROUS CYSTS AND AMELOBLASTOMAS; EXPRESSION OF MCM2 IN DENTIGEROUS CYSTS AND AMELOBLASTOMAS AN IMMUNOHISTOCHEMICAL STUDY

dr.rabianjum@gmail.com

Dr. Rabia Anjum¹, Dr. Nadia Naseem², Dr. A.H Nagi³

1. Department of Oral Pathology/
Morbid Anatomy and
Histopathology,
University of Health Sciences
Lahore, Pakistan
2. Department of Oral Pathology/
Morbid Anatomy and
Histopathology,
University of Health Sciences
Lahore, Pakistan
3. Department of Oral Pathology/
Morbid Anatomy and
Histopathology,
University of Health Sciences
Lahore, Pakistan

Correspondence Address:

Dr. Rabia Anjum
Department of Oral Pathology/
Morbid Anatomy and Histopathology,
University of Health Sciences Lahore,
Pakistan
dr.rabianjum@gmail.com

Article received on:

11/05/2016

Accepted for publication:

09/09/2016

Received after proof reading:

00/00/2016

ABSTRACT... Objectives: The aim of study was to observe the expression of MCM2 in dentigerous cyst and ameloblastoma. **Introduction:** Minichromosome maintenance protein (MCM2) may be a structurally and functionally complicated replication moiety that synergizes with different molecular factors therefore regulate DNA synthesis. MCM proteins play a job in maintaining genomic integrity and stop re-replication once per cell cycle. It's absent from chromatin in quiescent cells however abundant in mitotically active cells so making it a helpful marker for cellular proliferation. Dentigerous cyst (DC) is the commonest biological process odontogenic cyst having high proliferative index that may lead to dysplastic changes and development of tumours. Ameloblastoma is uncommon, benign and regionally aggressive odontogenic neoplasm with high rate of repetition after surgery. **Study design:** It was a descriptive study and designed to work out the expression of MCM2 in DCs and ameloblastomas. **Setting:** Department of Morbid Anatomy and Histopathology/ Oral Pathology. **Period:** Six months. **Material and methods:** Twenty-five patients presenting with DCs (n=12) and ameloblastomas (n=13) were selected. Clinical and radiographical findings were recorded and biopsies were submitted for histological diagnosis. MCM2 immunopositivity was assessed by immunohistochemistry in four microscopic high power fields showing most range of immunopositive cells. **Results:** Mean age was 26.5 ± 11.24 years and 42.07 ± 9.24 years whereas male to feminine magnitude relation was 7:5 and 7:6 for DCs and ameloblastomas severally. Most of the patients (58.3%) of DCs were asymptomatic whereas 41.6% patients reportable with painful swelling. Comparing, all patients with ameloblastomas conferred with painless swelling. Radiographically, all DCs were unicystic radiolucent lesions. While 46.2% of ameloblastomas were unicystic whereas 53.8% were multicystic radiolucent lesions. Histologically, basal layer atypia was seen in 50% and 23% of DCs and ameloblastomas respectively. High MCM2 immunoreactivity was ascertained within the epithelial lining of the DCs and the neoplastic cells of ameloblastomas. **Conclusion:** MCM2 expresses the higher proliferation potential that might lead to neoplastic development in DCs while local invasive and recurrence potential in ameloblastomas.

Key words: Dentigerous cyst, Ameloblastoma, MCM2

Article Citation: Anjum R, Naseem N, Nagi AH. Dentigerous cysts and ameloblastomas; Expression of MCM2 in dentigerous cysts and ameloblastomas an immunohistochemical study. Professional Med J 2016;23(12):1561-1565.

DOI: 10.17957/TPMJ/16.3166

INTRODUCTION

Mcm2, is the companion of the mini-chromosome maintenance (mcm) group of proteins that shows a key role in deoxyribonucleic acid duplication throughout G-1 of the cellular progression. Cells show its maximum expression while multiplying as it is weak or vague in the G-0 level. It is frequently utilized as a marker for cellular proliferation.¹ Primarily, these macromolecules along with others are involved in forming the re-plication branch. These molecules jointly standardizes the production of DNA. They build a ring shaped

compound that gets stimulated when other factors are intended. Thus these retain the coherence of the genome and replication of DNA. Cells show great intensity of mcm in proliferation stage which does not appear in inactive, or grown cells.² It is often detected in normal cells in addition to pre-cancerous and cancerous cells throughout cellular propagation.³

Among the oral cystic lesions, denti-gerous cyst is thought to be more prevalent representing about twenty percent of cystic lesions arising during. It

develops as fluid accumulates in the middle of the reduced enamel epi-thelium and tooth crown broadening dental follicle further than standard diameter of 3 mm.⁴

Amelo-blastoma is a rare but benign and aggressive regional odontogenic tumor constituting about ten percent of tumors found in both jaws.⁵ Though the etiology unknown yet it is considered to come from dental epithelial tissue.⁶

Methodology

We took n=25 cases comprising of denti-gerous cyst (n = 12) and amelo-blastoma (n = 13) from Surgery Department of de'Montmorency College of Dentistry Lahore. The study period was 6 months. Data were consisted of age of patient, sex, location along with radiographic verdicts. Minor curetting, split biopsies and true cut were collected. Blocks were prepared next to noting the gross details of biopsy. There were n=12 cases of denti-gerous cyst, while n=13 were ameloblastoma. These were recorded after making H&E stained sections on glass slides and looked under light microscope by pathologists.

Immunohistochemistry

Around four microns sections were taken on poly L-lysine glazed glass slides. These were then de-paraffinized and re-hydrated in xylene and graded ethyl alcohol, followed by dipping in citrate buffer solution having pH 4.8. Afterwards they were dried before staining procedures. Streptavidin biotin system was employed to perform the peroxidase anti-peroxidase immuno-histochemical staining. The sections were incubated with primary monoclonal anti-mcm2 antibody DAKO and then they were treated with DAB chromogen after that counter staining was done with hematoxylin. Strength and level of mcm-2 expression was determined by counting 100 nuclei in every case

and ratio of positive nuclei among the overall ranks of nuclei were recorded.

RESULTS

In dent-igerous cyst mean age was 26.5 ± 11.24 years whereas in amelo-blastoma it was 42.07 ± 9.24 years with male's predominance in both. (Figure-1)

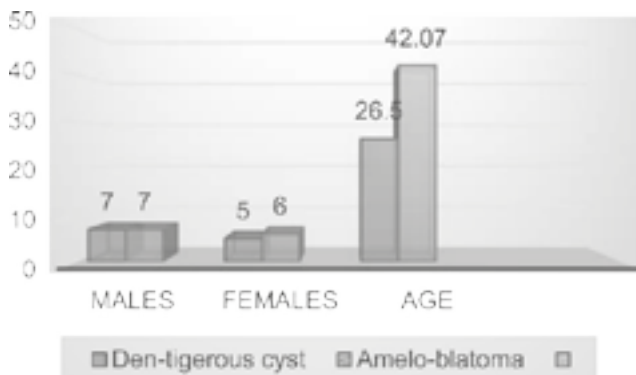


Figure-1. Frequency of distribution of sex and age.

Molar region of lower jaw was more commonly effected while comparing to incisor area of both upper and lower jaw. Out of n = 25cases, n = 13 were seen on right and n = 7 on left side. Though n = 3 were located in incisor area. A notable variation was seen at both clinical and radiographic examination. (Table-I)

Histologically, denti-gerous cyst were characterized by stratified squamous epithelial tissue with connective tissue encompassing a cystic space (Figure-2).

Chronic inflammatory infiltrate was ascertained in n = 10 (83.3%) cases of denti-gerous cyst. Atypical features illustrated by pleo-morphism, changed nuclear to cytoplasm relation and amplified stratification affecting basal layer was seen in 50% (n = 6).

	Denti-gerous Cyst	Amelo-blastoma
Clinical Features	Pain 75% (n=9) Asymptomatic 25% (n=3)	Painless swelling 100%(n=12)
Radiographic Features	Uni-cystic radio-lucency 100% (n=13)	Uni-cystic radiolucency 46.2% (n=6) Multi-cystic radiolucency 53.8% (n=7)

Table-I. Clinical & Radiographic Features

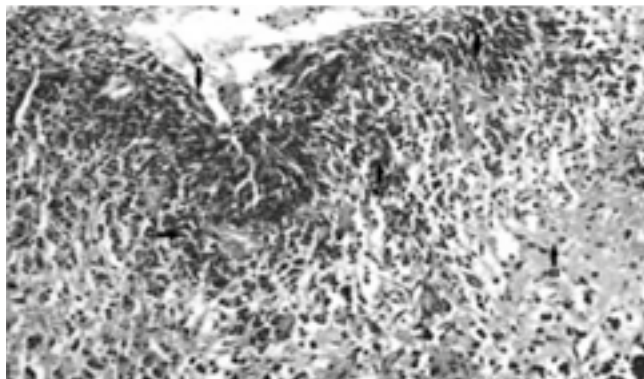


Figure-2. H&E stained tissue section reveals epithelium (A), edematous connective tissue (B) and intrusive inflammation (C). (40X)

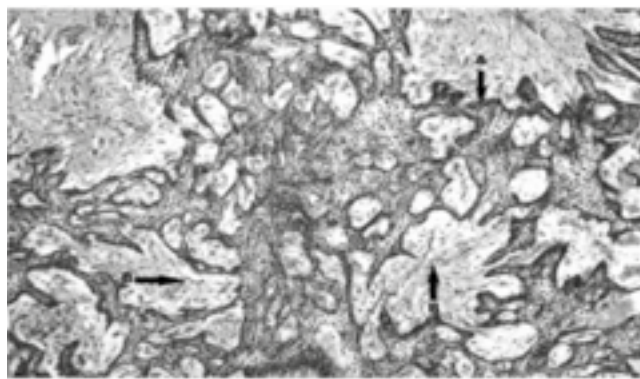


Figure 3: H & E stained tissue section shows plexi-form type of amelo-blastoma; reverse polarization (A) and stellate reticulum cells (B). (20x)

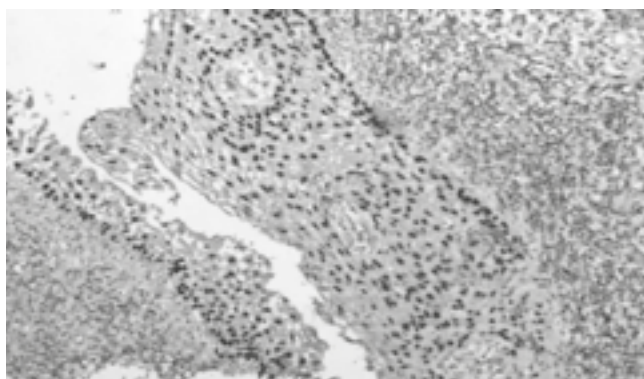


Figure-4. This demonstrates the positive expression of mcm2 in dentigerous cyst.

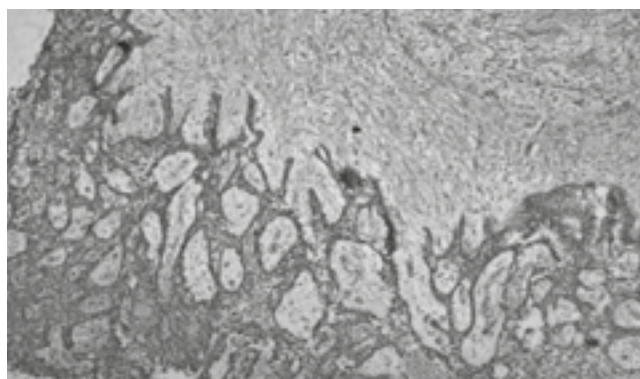


Figure-5. It presents the +ve mcm2 expression amelo-blastoma.

In amelo-blastomas, 15.38% (n = 2) follicular, 38.46% (n = 5) plexi-form and 46.15% (n = 6) uni-cystic types were identified (fig 3). Only 23% (n = 3) showed atypical characteristics.

All cases of denti-gerous cysts showed positive mcm2 expression as brown colour in nucleus of epithelial cells (Figure-4).

In amelo-blastoma mcm2 expression was seen in nuclei of epithelial cells while in stellate reticulum it was infrequent (Figure-5).

DISCUSSION

Denti-gerous cysts are thought of foremost major odonto-genic cysts.⁷ sometimes, few tumours like amelo-blastoma can grow from the epithelium of denti-gerous cyst.⁴

As regards age, it was 26.5 ± 11.24 years in current study while it was stated as 22.2 years in alike study.⁸ This difference could be due

to variation in inheritance, race, backgrounds and socio-economic rank. Female majority is seen that is inconsistent to other alike study.⁹ Patients were mainly symptomless only limited were related with pain that is analogous with the outcomes in different studies.⁴ Radiographic and morphological features of dentigerous cysts comprehended in current study were same to the verdicts reported by Scholl RJ in his research.⁷ Ameloblastomas might grow completely from different sources of odonto-genic epithelium, together with epithelial lining of dental follicle.⁶ About fifty percent amelo-blastomas are supposed to ascend from the epithelium of a denti-gerous cyst.⁷ Though amelo-blastomas are benign yet destructive in nature. Multi-cystic variants are more belligerent. They can re-ocurre.¹¹

In amelo-blastoma, mean age 42.07 ± 9.24 years along with high proportion of males was reported in current study Whereas Abdel-Aziz Amin stated mean age 44.18 ± 6.97 years with preponderance

of females.¹² Barnes et al ascertained alike medical, radio-graphic and morphological features as comprehended in the present study.¹³

Firstly, various cell-ular multiplying markers like Ki67, PCNA, Ag-NOR, and p-53 were employed to define the bio-logic activities of odonto-genic cysts and tumor.¹⁴ PCNA is thought to be linked with malignant change, blood vessels penetration and metastatic potential. Therefore it's stood to delineate as a Colo-rectal Adenocarcinoma Biomarker.¹⁵ Ki67 is considered as a decent marker for measuring the mitotic activity since it is often detected in all parts of the cellular progression apart from the G0-point.¹⁶

An assessment of mcm2 countenance in healthy and neoplastic tissues depicts it as a consistent bio-marker.¹⁷ In current study, mcm2 immunostaining was found in epithelium of denti-gerous cyst that is in accordance with the observations reported by NurhanG"uler. He performed his study on n=20 cases of denti-gerous cyst including dental follicles as well.¹⁸

Concerning, mcm2 immuno-expression in amelo-blastoma no study was established yet.

CONCLUSION

MCM2 determines increased mitotic activity in denti-gerous cyst which might lead to development of neoplasm while in amelo-blastomas it depicts aggressive nature and probability of re-emergence.

Copyright© 08 Sep, 2016.

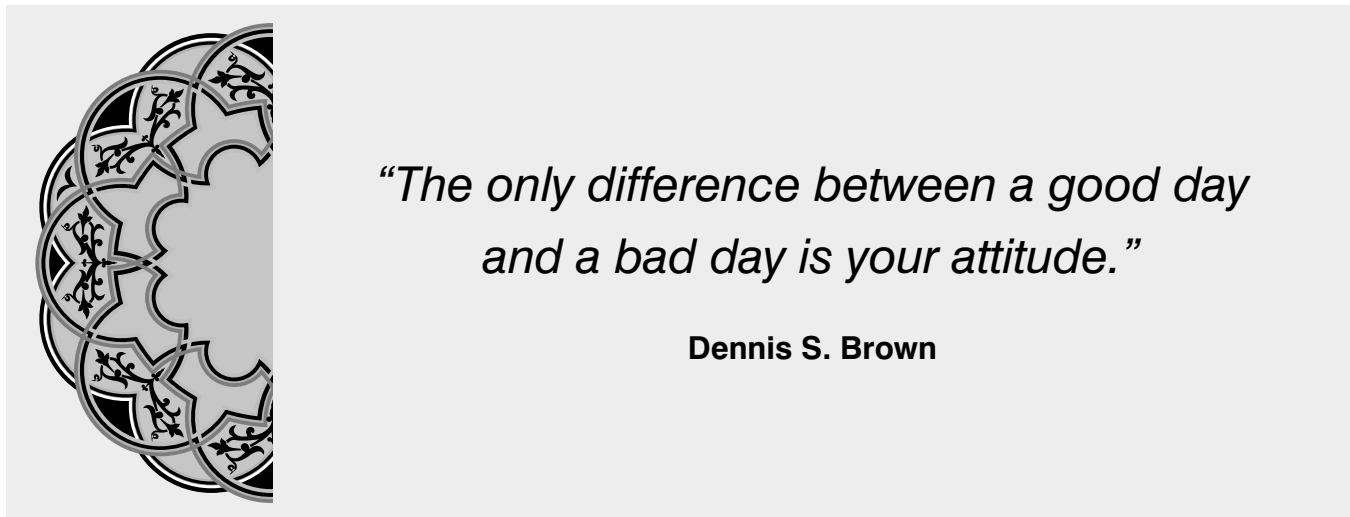
REFERENCES

1. Davies RJ, Freeman A, Morris LS, Bingham S, Dilworth S, Scott I, Laskey RA, Miller R and Coleman N: **Analysis of mini-chromosome maintenance proteins as a novel method for detection of colorectal cancer in stool.** Lancet 359: 1917-1919, 2002.
2. J. J. Blow and A. Dutta, "Preventing re-replication of chromosomal DNA," Nature Reviews Molecular Cell Biology, vol. 6, no. 6, pp. 476-486, 2005.
3. Freeman, L. S. Morris, A. D. Mills et al., "Minichromosome maintenance proteins as biological markers of dysplasia and malignancy," Clinical Cancer Research, vol. 5, no. 8, pp. 2121-2132, 1999.
4. Shibata Y, Asaumi J, Yanagi Y, Kawai N, Hisatomi M, Matsuzaki H, Konouchi H, Nagatsuka H, Kishi K: **Radiographic examination of dentigerous cysts in the transitional dentition.** Dentomaxillofac Radiol 2004, 33:17-20.
5. Zemann W, Feichtinger M, Kowatsch E, Kärcher H: **Extensive ameloblastoma of the jaws: surgical management and immediate reconstruction using microvascular flaps.** Oral Surg Oral Med Oral Pathol Oral Radiol Endod 2007, 103:190-196.
6. Kumamoto H, Ooya K: **Immunohistochemical detection of retinoblastoma protein and E2 promoter-binding factor-1 in ameloblastomas.** J Oral Pathol Med 2006, 35:183-189.
7. Scholl RJ, Kellett HM, Neumann DP, Lurie AG. **Cysts and cystic lesions of the mandible: clinical and radiologic-histopathologic review.** RadioGraphics 1999; 19(5):1107-1124.
8. Serra VG, Conde DM, et al: **Odontogenic cysts in children and adolescents: a 21-year retrospective study.** Braz. J. Oral Sci. 2012, vol.11(2) .
9. Hyomoto M, Kawakami M, Inoue M, Kirita T: **Clinical conditions for eruption of maxillary canines and mandibular premolars associated with dentigerous cysts.** Am J Orthod Dentofacial Orthop. 2003; 124(5):515-20.
10. Lau S, Samman N: **Recurrence related to treatment modalities of unicystic ameloblastoma: a systematic review.** Int J Oral Maxillofac Surg 2006, 35:681-690.
11. Abdel-Aziz and Amin: **EGFR, CD10 and proliferation marker Ki67 expression in ameloblastoma: possible role in local recurrence.** Diagnostic Pathology 2012 7:14.
12. Barnes, L., Eveson, J. W., Reichart, P., & Sidransky, D. (2005). **Pathology and genetics of head and neck tumors (IARC WHO Classification of Tumours, No 9 ed.).** Switzerland: WHO Press
13. R. A. Mendes, J. F. C. Carvalho, and I. Van Der Waal, "A comparative immunohistochemical analysis of COX-2, p53, and Ki-67 expression in keratocystic odontogenic tumors," Oral Surgery, Oral Medicine, Oral Pathology, Oral Radiology and Endodontology, vol. 111, no. 3, pp. 333-339, 2011.
14. Yang HB, Hsu PI, Chan SH, Lee JC, Shin JS and Chow NH: **Growth kinetics of colorectal adenocarcinoma sequence: an immunohistochemical study of proliferating cell nuclear antigen expression.** Human Pathology 10: 1071-1076, 1996.

15. Sahin AA, Ro JY, Brown RW, Ordonez NG, Cleary KR, elNaggar AK, Wilson P and Ayala PG: **Assessment of Ki-67 derived tumor proliferative activity in colorectal adenocarcinomas.** Mod Pathol 17: 17-22, 1994.

16. Maiorano D, Lutzmann M and Mechali M: **MCM proteins and DNA replication.** Curr Opin Cell Biol 18: 130-136, 2006.

17. Güler N, Comunoğlu N, Cabbar F. **Ki-67 and MCM-2 indental follicle and odontogenic cysts: the effects of inflammation on proliferative markers.** ScientificWorldJournal 2012; 2012:946060. doi: 10.1100/2012/946060. Epub 2012 Jun 18.



AUTHORSHIP AND CONTRIBUTION DECLARATION

Sr. #	Author-s Full Name	Contribution to the paper	Author=s Signature
1	Dr. Rabia Anjum	Conception, Synthesis and Planning of research active participation in methodology, Interpretation, analysis and discussion	
2	Dr. Nadia Naseem	Conception, synthesis and planning of research, Interpretation, analysis and discussion	
3	Dr. A.H Nagi	Conception, synthesis and planning of research, Interpretation, analysis and discussion	