



1. FRCS
Chief of Surgery
Foundation Hospital Rajana
2. MBBS,FCPS
Consultant Gynecologist,
Foundation Hospital Rajana
3. MBBS,FCPS(1)
Consultant Surgeon,
Foundation Hospital Rajana

Correspondence Address:
Prof. Altaf Hussain Rathore
Chief of Surgery
Foundation Hospital Rajana
surgrathore@gmail.com

Article received on:
18/08/2016
Accepted for publication:
20/09/2016
Received after proof reading:
14/11/2016

LEIOMYOMA; THE ROUND LIGAMENT (A CASE REPORT).

surgrathore@gmail.com

Prof. Altaf Hussain Rathore¹, Dr Faiza Rafiq², Dr. Sadaf Malik³

ABSTRACT... A rare case of leiomyoma of round ligament is reported. It presented as irreducible right inguinal hernia. Its shape and size was of a normal kidney for which peroperative I.V.U was done to exclude the ectopic kidney. No. such case has been reported in the literature so far.

Key words: Leiomyoma of round ligament- inguinal hernia, case report.

Article Citation: Rathore AH, Rafiq F, Malik S. Leiomyoma; the round ligament (a case report). Professional Med J 2016;23(10):1429-1431. DOI: 10.17957/TPMJ/16.3590

INTRODUCTION

Leiomyoma is the most common gynecological tumor in female. It occurs between reproductive age in 15-20% and rare after menopause.¹ Majority of the tumors arise from the body of the uterus but uncommon sites are cervix, fallopian tubes, ovaries, round ligament, broad ligament, sacro uterine ligament, vagina and urethra.^{2,3,4,5,6,7} Leiomyoma arising from the round ligament is rare, usually single and unilateral and 50% are associated with the same lesion of the body of the uterus.⁸ Due its rarity and mistaken diagnosis, it is diagnosed at operation, if it involves the portion of the round ligament in the inguinal region.⁹ We report a similar rare case of leiomyoma of the round ligament,

CASE REPORT

N.M 45 years married woman presented with a swelling in the right inguinal region which went on increasing in size progressively. She was a house wife, had two sons, two daughters between 7 years to 15 years all delivered normally after full term. Her menarche was at the age of 13 years and her menstruation had always been normal. She had no such problems in the family. (The swelling was nontender, firm; mobile oblong about 10 cms X 3.5 cms) Cough impulse was absent. Clinically it was diagnosed as an irreducible right inguinal hernia..

Investigation

Blood examination Hb 11.6, Sugar 72 and blood group B+.

Ultrasound

Revealed a soft tissue mass about 8.9 * 3.2 cms in right iliac fossa which could be a lipoma or subcutaneous haematoma. Both ovaries, ovarian tube and uterus were normal.

IVP (Peroperative)

Both kidneys were in normal place; functioning normally, ureter and bladder were normal, no mass or filling defect.

Operation: (Fig 1,2)

She was operated under GA. An oblique incision over swelling was given. A kidney shaped swelling 10cm x 5cm, firm, pink in colour was found between external oblique aponeurosis and internal oblique, attached with normal looking right round ligament. It was drawing its blood supply from internal iliac vessels. (Initially we thought it was and ectopic kidney, thinking round ligament as ureter). Uterus and both ovaries were absolutely normal. The removal of whole swelling with the right round ligament was an easy job. She made an uneventful recovery and was sent home 3 days after. Healing was good. She never reported again.

MICROSCOPIC EXAMINATION REPORT

Revealed marked proliferation of oval spindle shaped smooth muscle cells arranged in sheets and groups at places. Typical whirl pattern is also present. Foci of hemorrhage are also demonstrated. There is no evidence of specific inflammation or malignancy. Picture is suggestive of leiomyoma.

DISCUSSION

No doubt leiomyoma of the round ligament is rare but no very rare. It was first reported by Well's in 1865 and upto 1933 Watkin collected 173 cases of tumor of round ligament from the

medical literature.¹⁰ The tumor of inguinal part of round ligament is difficult to diagnose due to its rarity; so commonly diagnosed as inguinal hernia, hydrocele of round ligament (cyst of canal of Nuck) thrombosis of varicose veins around round ligament and endometriosis.^{11,12,13}

Kirkhan et al¹⁴ and picek³ reported similar case mimicking clinically inguinal hernia. The most interesting part of our case is its size and shape which resembled a kidney. To exclude it we had to perform preoperative intravenous urography.

Copyright© 20 Sep, 2016.

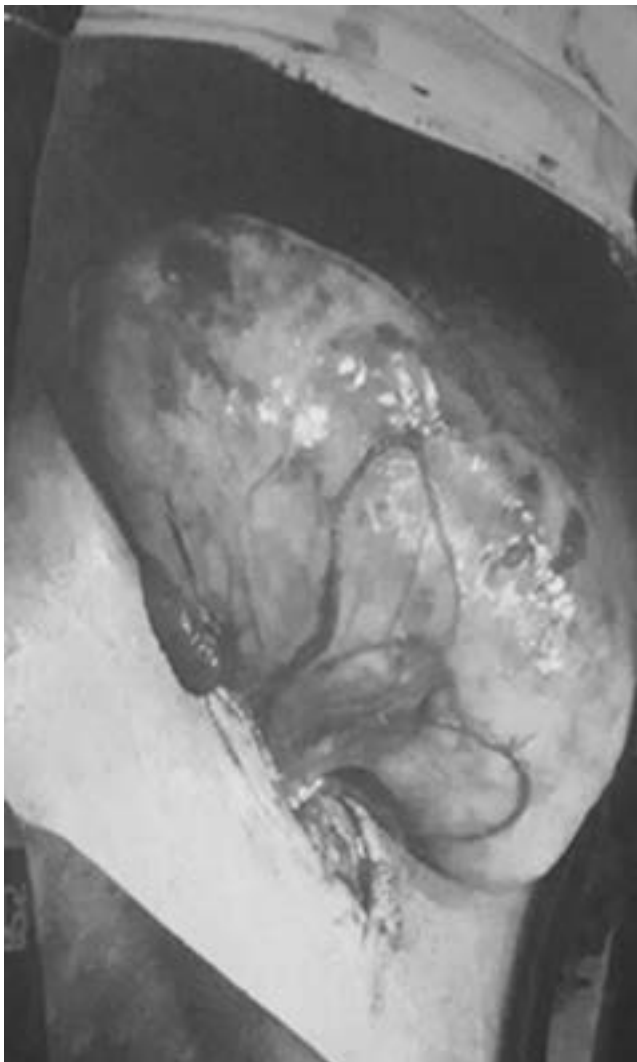


Fig-1. At operation posterior view of Tumour

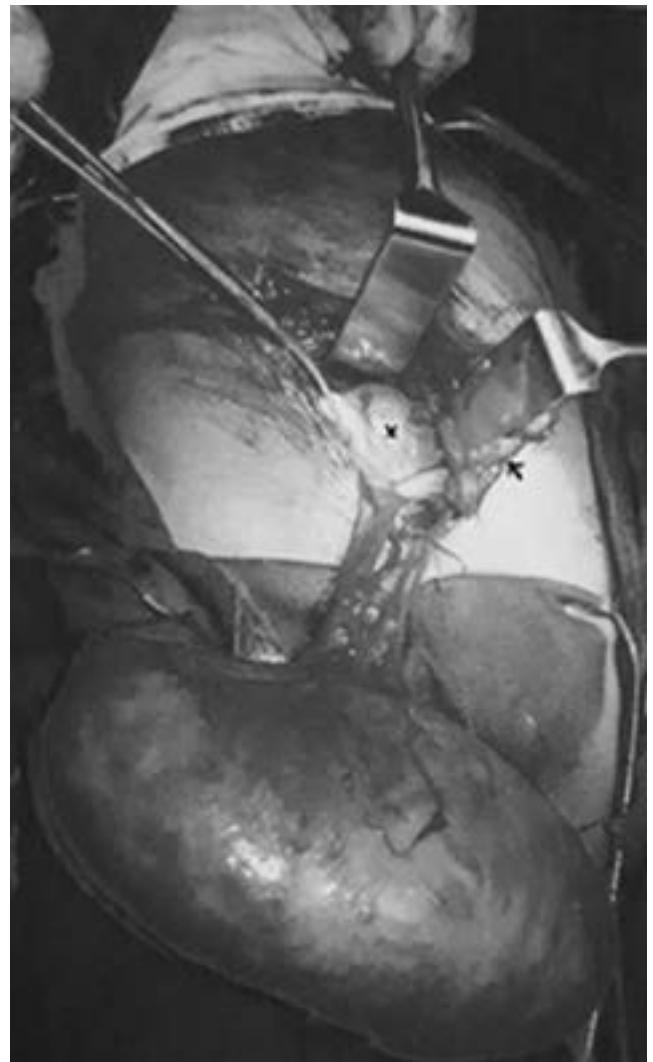



Fig-2. Anterior view of the tumour (Round ligament, X Left Cornu of uterus)

REFERENCES

1. Mahudkar VM, **leiomyoma of round ligament during early pregnancy**, journal of obstetrics, gynecology and family welfare, 199;1 :15-6.
2. Jeffcoate's principles of Gynaecology, edition V , 2001, Arnold Publishers , chapter 27, pages 500-3.
3. Pisek A Ismaili H, **Myoma of the round ligament mimicking the clinical appearance of the inguinal hernia- a case report**, ZDRAV VESTN, 2004; 73: 911-4.
4. Roberts CL, Marschall HK. **Fibromyoma of the fallopian tube**. AM J Obstet Gynecol 1961; 82:364.
5. Fallahzadeh H Dockerty MB Lee RA. **Leiomyoma of the ovary**. AM J Obstet Gynecol 1972; 112:394.
6. Breen JL, n=Neubecker RD, **tumor of the round ligament. A review of the literature and report of 25 cases**. Obstet Gynecol 1962; 19:771-80.
7. Tiwari OP, Gupta A, Gupta M. **Leiomyoma of the vagina**. The Indian journal of Radiology and imaging. 1999;9;3.
8. Kwack MJ, Kim JE, Lee WA, Park MC, jin K, **A case of large cystic myxoid leiomyoma in uterine round ligament**, Korean J Obstet Gynecol 2005;48: 1069-73.
9. Chhabra, Bala N. **Huge leiomyoma of round ligament**. The Antriseptic 2001; 98: 141-6.
10. Mayo CW, Schunke GB, **Leiomyoma of the round loigament**, Arch surg. 1940; 41: 637-45.
11. Break JS ed. Novak's Gynecology. Baltimore: Williams and Williams 1995: 359-61.
12. Harper GB Jr, Awbrey BJ, Thomas CG Jr, Askin FB. **Mesothilal cysts of the round ligament simulating inguinal hernia**. Report of four case and review of the literature AM J surg 1986; 151:515-7.
13. Candiani GB Vercellini P , Fedele L, Vendola N, Cerinelli S, Scaglione V, **Inguinal endometriosis: pathogenic and clinical implications**. Obstet Gynecol 1991; 78: 191-4.
14. Kirkhan JC, Nero CJ, Tambouret R.H Yoon SS, **Leiomyoma and leiomyosarcoma Arising from the round ligament of the Uters**, journal of the American collage of surgeons 2008; 207:3.



*“Life consists not in holding good cards,
but in playing those cards you hold well.”*

Unknown

AUTHORSHIP AND CONTRIBUTION DECLARATION

Sr. #	Author-s Full Name	Contribution to the paper	Author=s Signature
1	Prof. Altaf Hussain Rathore	1st Author	
2	Dr Faiza Rafiq	2nd Author	
3	Dr. Sadaf Malik	3rd Author	