



## INGUINAL HERNIA;

“A SOLUTION FOR THE 3RD WORLD HERNIA PATIENTS” (E-TEP) THE ENHANCE OR EXTENDED VIEW TOTALLY EXTRA PERITONEAL TECHNIQUE FOR THE REPAIR WITHOUT SPACER BALLOON and TACKER.

aghanadeem42@gmail.com

1. Senior Registrar  
Department of Surgery
2. Assistant Prof. of Surgery  
Department of Surgery
3. Senior Registrar  
Department of Surgery
4. Professor of Surgery  
Department of Surgery  
Nishtar Hospital Multan.

**Correspondence Address:**  
Dr. Agha Nadeem Ahmed Khan  
Senior Registrar (W 6),  
Nishtar Hospital Multan.  
Address: 78B Meharban Colony  
Multan  
aghanadeem42@gmail.com

**Article received on:**

02/07/2016

**Accepted for publication:**

21/09/2016

**Received after proof reading:**

14/11/2016

### INTRODUCTION

In Pakistan the inguinal hernia is a common and frequently presenting condition in outpatient department (OPD). Majority of the patients belong to low socio-economic group usually laborers, cannot stay away from work for a longer period of time. The term laparoscopic inguinal herniorrhaphy can refer to any of the following.

- Intraperitoneal onlay mesh (IPOM) repair.
- Transabdominal preperitoneal (TAPP) repair.
- Totally extraperitoneal (TEP) repair.
- The enhanced or extended view totally extraperitoneal (e-TEP) repair.

The IPOM repair has largely fallen from favor, and currently the most commonly performed laparoscopic techniques are the TEP and TAPP repairs although many facets of laparoscopic inguinal hernia repair continue to be debated. Such as the possible superiority of one laparoscopic approach to another, comparison between laparoscopic and open surgery, the learning curve and training issues, and the socio economic implication. Both TEP and TAPP have

**Dr. Agha Nadeem Ahmed Khan<sup>1</sup>, Dr. Shafiq Ullah<sup>2</sup>, Dr. Muhammad Farrukh Aftab<sup>3</sup>,  
Dr. Khalid Hussain Qureshi<sup>4</sup>**

**ABSTRACT... Objectives:** To highlight an economical laparoscopic technique for rapid recovery & early return to work especially for the 3rd world inguinal hernia patients. **Study Design:** Descriptive study. **Setting:** Surgical unit of Nishtar Hospital Multan. **Period:** 02 years i.e. from January 2014 to January 2016. **Methods:** There were 90 patients in the study. A prolene mesh of 15 x 15 cm used for the repair of inguinal hernia laparoscopically without the use of spacer balloon & tacker (To make it cost effective). **Results:** Out of 90 patients only 3 patients develop scrotal seroma. All the patients discharged on the 1st postoperative day & allowed to return to their normal routine work from the 3rd postoperative day onward. **Conclusion:** (e-TEP) without spacer balloon & tacker is an economical approach toward the inguinal hernia repair.

**Key words:** Laparoscopic totally extra peritoneal repair, hernioplasty, cost effective laparoscopic repair.

**Article Citation:** Khan ANA, Shafiq Ullah, Aftab MF, Qureshi KH. Inguinal hernia; “A solution for the 3rd world hernia patients” (E-Tep) the enhance or extended view totally extra peritoneal technique for the repair without spacer balloon & tacker. Professional Med J 2016;23(11):1311-1318. DOI: 10.17957/TPMJ/16.3519

been shown to be acceptable and safe for the repair of inguinal hernia.

The favored laparoscopic approach for the repair of inguinal hernia is the total extra peritoneal (TEP) repair due to the fact that there is no incursion into the abdominal cavity therefore lessening the risk of visceral injury and limiting the formation of adhesences. The (e-TEP) the extended view laparoscopic repair is a modified form of TEP repair which provides an excellent view of the structures in the inguinal region and of the hernias that occurs in this space.<sup>2</sup> The conventional e-TEP technique requires spacer balloon and tacker. In this sutudy we did not use the spacer balloon and tacker. Enhanced view or extended total extra peritoneal repair of hernia without spacer balloon and tacker is an economical approach, the average cost of spacer balloon is Rs 15000/- and the cost of the tacker (Steel) Rs 15000/- and (Secure strap) Rs 34000/-. Avoiding this much cost reduces the cost of the (e-TEP) making it cost effective<sup>6,7</sup>, moreover early return to work<sup>10</sup>, make it more economical for the

patient and his family and short hospital stay reduces the burden of hospital. The technique is indicated in the primary inguinal hernias, bilateral inguinal hernias<sup>9</sup>, and recurrent inguinal hernias. (e-TEP) Compensate the primary disadvantage of (TEP) which is a limited surgical field.(e-TEP) provide an ample surgical field and favor flexible port sites placements, these elements are useful in dealing with inguino scrotal hernias. Moreover not using the tacker avoids the inadvertent entrapment of nerves which in turn avoids post-operative pain, in addition to reducing the cost of the procedure.


**PATIENTS and METHODS**

All patients in this study were male and belong to age group between 20 to 60 years. Patients with reducible inguinal, Inguino Scrotal, Recurrent and bilateral inguinal hernia were included. Patients

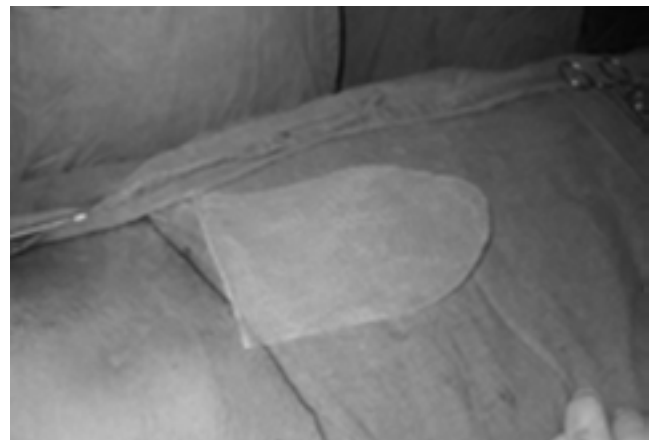
with non-reducible, obstructed or strangulated hernias were not included similarly the patients with an unacceptable surgical risk i.e. ASA III or IV were also not included. All the patients operated under general anesthesia. A prolene mesh of size 15 x 15 cm was used in all the cases for unilateral repair<sup>11</sup>, where bilateral repair required we used 2 meshes of the same size. All the patients have been followed up on weekly basis in OPD for the period of one month post operatively.

**Preparation of Mesh**

1. A prolene mesh of 15 x 15 cm size.
2. A piece of about 3cm separated with straight scissors from Mesh.
3. Mesh tapered to point on one side ( for the lateral side)
4. One side corner of the mesh made rounded for bladder curve.



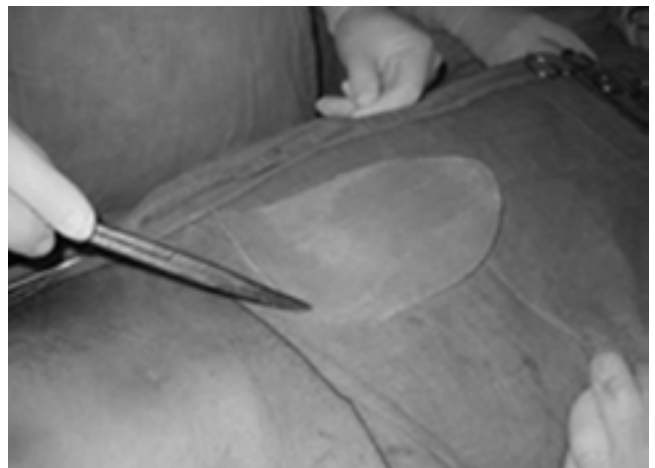(I)



(III)


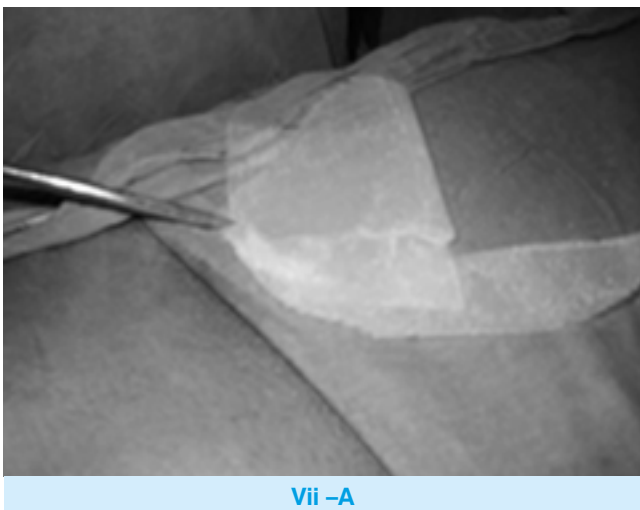




(II)



(IV)

5. Split tapered side to about middle of mesh.
6. The 3cm piece stitched to the larger segment.
7. The mesh folded & prolene stitch is applied to keep it in the form of a roll as shown in vii A, B & C.



**Technique of Operation**

After aseptic measures a 10mm port placed at the side of umbilicus on the side of hernia so that the lower edge lies at the lineasemilunaris or arcuate line as shown in figure-1.

An incision of about 1.2cm made near the upper end of the port, the incision deepened with the help of retractors up to the Rectus sheath as shown in figure-2 and 3.

Sheath incised & rectus muscle splits with the help of artery forceps. The posterior rectus sheath exposed & port passed over it, space created under the rectus muscle & over the posterior rectus sheath by side to side movement of the port as shown in figure-4.

The Co<sub>2</sub> insufflator attached & gas filled to help in making a tunnel. A 10mm, 0 degree telescope passed into the port & advanced to create space

in the retropubic area & to observe the anatomy of the inguinal region from posterior approach<sup>2</sup>. As shown in figure-5.

Two 5mm ports (Small sized specially tailored) in the mid line between the pubic symphysis & umbilicus under direct vision with the guidance of syringe needle as shown in the fig 6a,b and c and in Figure-5.

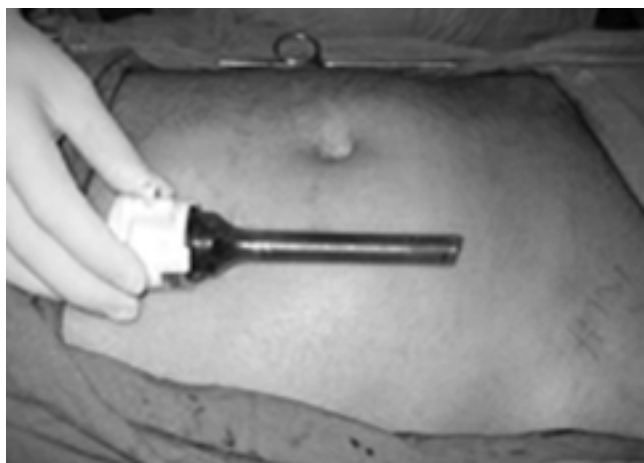

Figure-1.

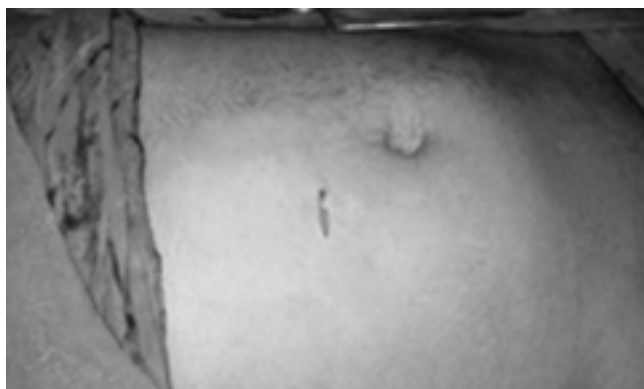


Figure-2

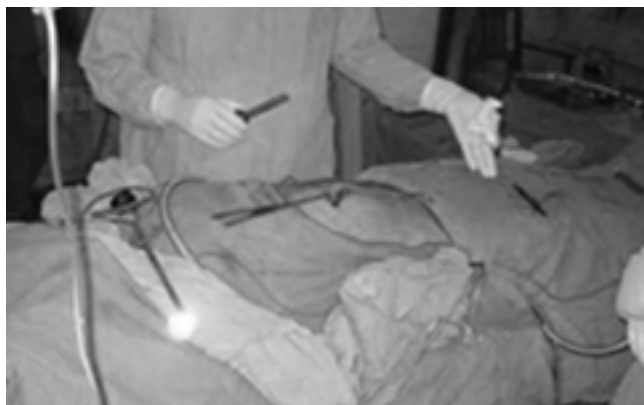

Figure-3

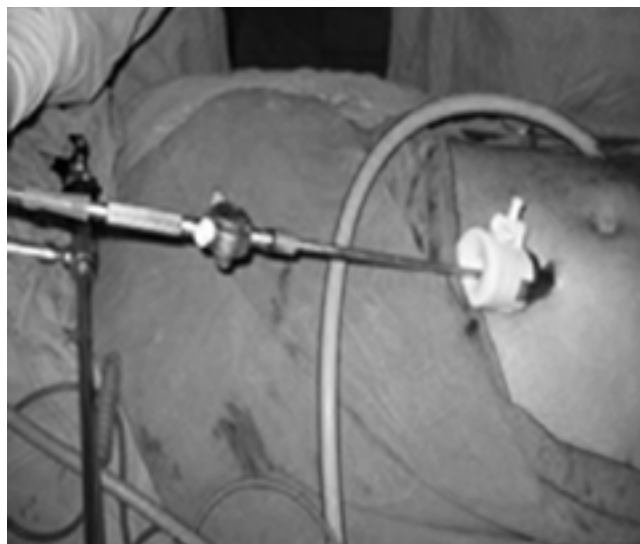


Figure-4

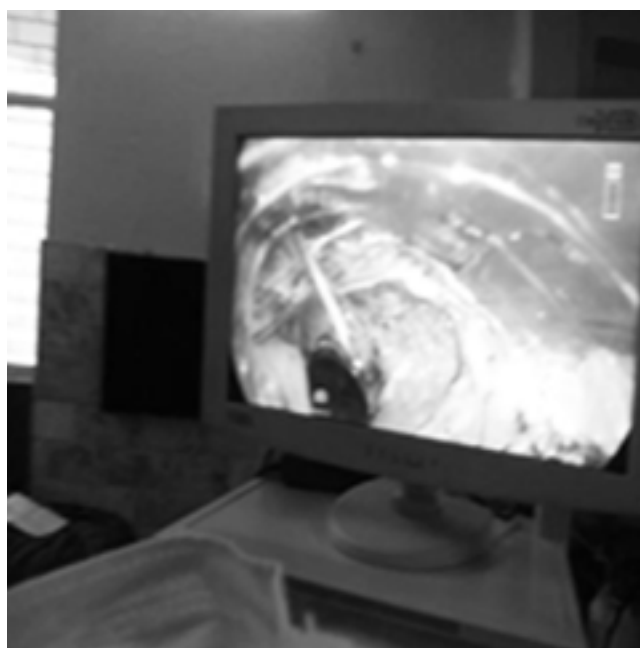


Figure-5

Dissection done to create space firstly on medial side then space created on lateral side this is an essential step for easy expansion of mesh. The inferior epigastric artery identified & protected throughout the procedure. The Retzius space (from midline to the inferior epigastric artery) should be displayed showing the place of direct inguinal hernia, obturator hernia & femoral hernia. The space of bogros, which is the lateral space displaying the sight of indirect inguinal hernia i.e the deep inguinal ring must be displayed.

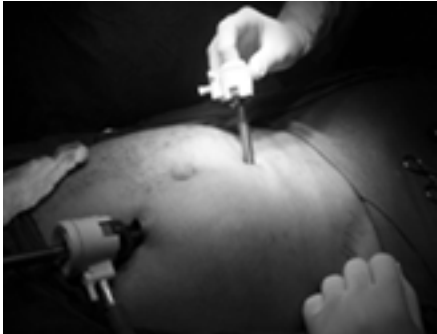

Figure-6a

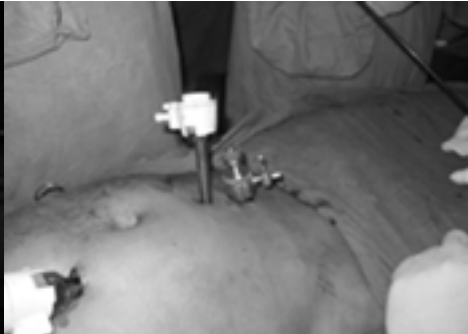


Figure-6b

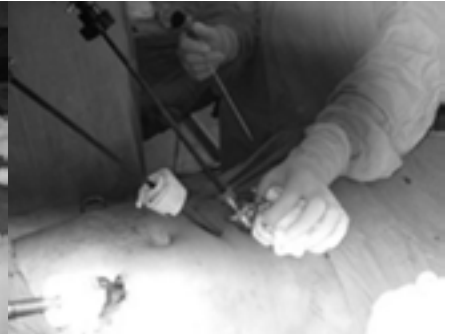

Figure-6c

Attention must be paid to the triangle of doom (Apex at deep inguinal ring medial boundary by vas deference, lateral boundary by spermatic vessels & base by the peritoneum), to prevent injury to the major vessels as shown in figure-7.

bogros to cover the deep inguinal ring as shown in figure-10 and 11, the deflation done, the port sites closed with subcuticular stitches with 2/0 vicryl as shown in figure-12.




Figure-7

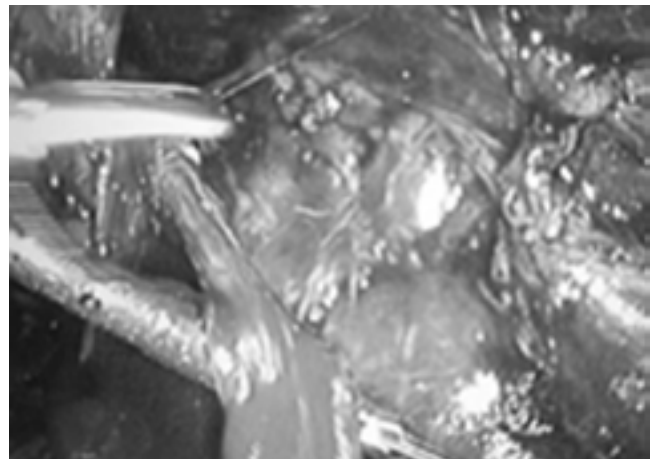


Figure-8

The hernial sac identified & separated from the ductus deference & vessels and the retro peritoneal space must be exposed behind the vas and spermatic vessels. During dissection grasping ductus deference may cause fertility problems, which must be avoided. The sac retraction done and a window created between the ductus deference & scrotal vessels as shown in figure-8.

Then the prepared mesh passed into the space via 10mm port, the tapered side brought to lateral side behind the vessels as shown in figure-9, and the holding stitch cut, then the medial side of mesh opened & spread out in a way to cover all the hernial orifices in Retzius space and the lateral half of the mesh also spread out in the space of




Figure-9




Figure-10



Figure-12



Figure-11

**RESULTS**

Our study included a total of 90 patients undergoing (e-TEP) hernioplasty. The types of inguinal hernia operated in this study are shown in table-I. Out of these 90 study cases, 65 patients (72%) were laborers and 25 (28%) were non laborers as shown in Figure-13. Mean age of our study cases was  $46.87 \pm 5.90$  years (with minimum age was 28 years while maximum age was 60 years of age). Distribution of ages in different groups has been presented in Figure-14 and table-III. Among the 90 Inguinal Hernia patients only three patients developed scrotal seroma, remaining patients recovered uneventfully and returned to the normal routine work from the third post operative day onwards as shown in table-II.

Total Number of Patients	Indirect	Direct	Recurrent	Bilateral
90	62	18	07	03

Table-I. Type of Inguinal Hernia Operated

Total Number of Patients	Indirect	Direct	Recurrent	Bilateral
90	62	18	07	03
Scrotal Seroma	00	03	00	00
Uneventful recovery	62	15	07	03

Table-II. Scrotal Seroma in Operated Cases

Total Number of Patients	20-30 years	31-40 years	41-50 years	51-60 years
90	05	22	51	12

Table-III. Age wise distribution of study cases

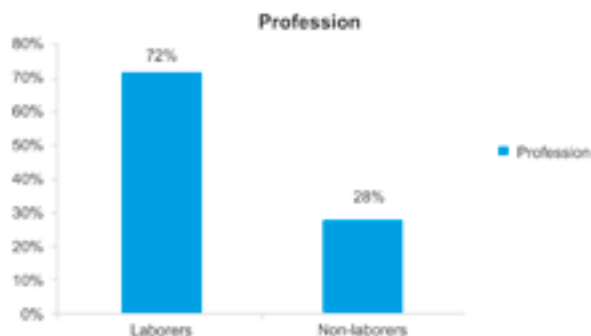


Figure-13. Graphical Representation of profession

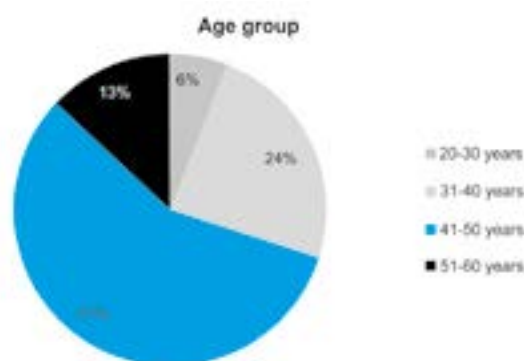


Figure-14. Percentage of age wise distribution of study cases.

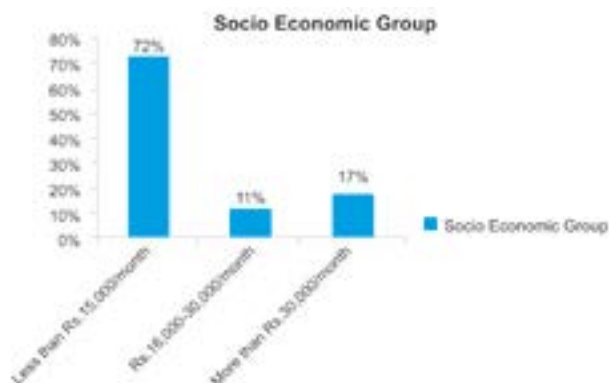


Figure-15. Graphical Representation of Socio-economic group

**DISCUSSION**

The development of laparoscopic techniques have revolutionized hernia repair, since it has an economical impact among endoscopic hernioplasties, totally extra peritoneal (TEP) and transabdominal pre-peritoneal (TAPP), approach are widely accepted alternative to open surgery<sup>1</sup>, both providing less post-operative pain, short hospital stay and early return to work. Several

studies have indicated (TEP) as the preferred technique<sup>1</sup>, since it avoids intraperitoneal approach and provides even less post-operative morbidity however it is demanding technique and requires an average of 60 to 70 procedures per surgeon to achieve a plateau of operative time.<sup>8</sup> In Pakistan most of the patients suffering from inguinal or inguino scrotal hernia belongs to low socio-economic group more over majority are laborers as shown in Figure-13 and Figure-15. Most of the patients cannot afford the cost of conventional e-TEP which requires the spacer balloon and tacker. After open hernioplasty we usually advise patients not to carry heavy weights for about 2 to 3 months.<sup>5</sup> This means we are not allowing laborers to work, who may be the only earning member of the family. In this study only three patients returned in second post-operative week with scrotal seroma during follow up visit. All the three patients who developed scrotal seroma were operated for direct inguinal hernia, remaining patients recovered uneventfully and returned to their normal routine work from the third post-operative day. The conventional e-TEP technique requires spacer balloon and tacker. In this sutudy we did not use the spacer balloon and tacker. Enhanced view or extended total extra peritoneal repair of hernia without spacer balloon and tacker is an economical approach, moreover early return to work<sup>10</sup>, make it more economical for the patient and his family and short hospital stay reduces the burden of hospital.

**CONCLUSION**

(e-TEP) enhanced view or extended view total extra peritoneal repair of hernia without spacer balloon and tacker is a solution for the 3rd world hernia patients.

Copyright© 21 Sep, 2016.

**REFERENCES**

1. Bracale U, Melillo P, Pignata G, Di Salvo E, Rovani M, Merola G, et al. **Which is the best laparoscopic approach for inguinal hernia repair: TEP or TAPP? A systematic review of the literature with a network meta-analysis.** Surg Endosc 2012; 26:3355-66.
2. Brassier D, Elhadad A. **Classic and endoscopic surgical anatomy of the groin.** J Chir (Paris) 2007; 144:5-10.

3. Daes J. **The enhanced view-totally extra peritoneal technique for repair of inguinal hernia.** Surg Endosc. 2012 Apr; 26(4):1187-9.
4. Misra MC, Kumar S, Bansal VK. **Total extra peritoneal (TEP) mesh repair of inguinal hernia in the developing world: comparison of low-cost indigenous balloon dissection versus direct telescopic dissection: a prospective randomized controlled study.** Surg Endosc 2008; 22:1947-58.
5. Juul, P, Christensen, K. **Randomized clinical trial of laparoscopic versus open inguinal hernia repair.** Br J Surg. 1999; 86:316–319.
6. Kald, A, Anderberg, B, Carlsson, P, Park, PO, Smedh, K. **Surgical outcome and cost-minimisation-analyses of laparoscopic and open hernia repair: a randomized prospective trial with one year follow up.** Eur J Surg. 1997; 163:505–510.
7. Heikkinen, TJ, Haukipuro, K, Hulkko, A. **A cost and outcome comparison between laparoscopic and Lichtenstein hernia operations in a day-case unit.** A randomized prospective study. Surg Endosc. 1998; 12:1199–1203.
8. Liem, MS, van Steensel, CJ, Boelhouwer, RU, Weidema, WF, Clevers, GJ, Meijer, WS et al, **The learning curve for totally extra peritoneal laparoscopic inguinal hernia repair.** Am J Surg. 1996; 171:281–285.
9. Kald, A, Domeij, E, Landin, S, Wiren, M, Anderberg, B. **Laparoscopic hernia repair in patients with bilateral groin hernias.** Eur J Surg. 2000; 166:210–212.
10. Wright, DM, Kennedy, A, Baxter, JN, Fullarton, GM, Fife, LM, Sunderland, GT et al, **Early outcome after open versus extraperitoneal endoscopic tension-free hernioplasty: a randomized clinical trial.** Surgery. 1996; 119:552–557.
11. Johansson, B, Hallerback, B, Glise, H, Anesten, B, Smedberg, S, Roman, J. **Laparoscopic mesh versus open preperitoneal mesh versus conventional technique for inguinal hernia repair: a randomized multicenter trial (SCUR Hernia Repair Study).** Ann Surg. 1999; 230:225–231.

**PREVIOUS RELATED STUDY**

Gulzar Ahmad Malik, Kashif Kurshid Qureshi, Imtiaz Ahmad, Muhammad Afzal. DARNING VS BASSINI REPAIR FOR INGUINAL HERNIA; A PROSPECTIVE COMPARATIVE STUDY (Original) Prof Med Jour 14(1) 134 - 143 Jan, Feb, Mar, 2007.

Iftikhar Ahmed Bhatti. INGUINAL HERNIA REPAIR IN A PERIPHERAL HOSPITAL (Original) Prof Med Jour 13(4) 691-696 Oct, Nov, Dec, 2006.




Muhammad Javed, Abdul Nasir. INGUINAL HERNIAS; COMPARISON OF OPEN PRE-PERITONEAL MESH REPAIR WITH LIECHTENSTEIN TENSION FREE REPAIR (Original) Prof Med Jour 13(4) 710-715 Oct, Nov, Dec, 2006.

Mirza Asadullah, Syed Hussein Mehdi, Sheeraz Shakoor Siddique. EARLY COMPLICATIONS OF INGUINAL HERNIA REPAIR (Original) Prof Med Jour 14(1) 119 - 122 Jan, Feb, Mar, 2007.

Shahzad Avais, M. Zakir, E. Rehman, Masood Rashid. INGUINAL HERNIA REPAIR; EXPERIENCE OF LAPAROSCOPIC TOTAL EXTAPERITONEAL APPROACH (Original) Prof Med Jour 17(1) 35-39 Jan, Feb, Mar 2010.

Quddus-ur-Rehman, Tajammal Abbas Shah, Usman Latif. INGUINAL HERNIA; LICHTENSTEIN AND DARN REPAIR A COMPARATIVE STUDY (Original) Prof Med Jour 17(1) 50-54 Jan, Feb, Mar 2010.

**AUTHORSHIP AND CONTRIBUTION DECLARATION**

Sr. #	Author-s Full Name	Contribution to the paper	Author=s Signature
1	Dr. Agha Nadeem Ahmad Khan	Study planning, Designing, Coordination in DATA Collection, Paper writing & editing	
2	Dr. Shafiq Ullah	Study planning, Designing, DATA Entry, DATA Analysis	
3	Dr. Muhammad Farrukh Afifab	DATA Collectin, Menu script writing & editing	
4	Dr. Khalid Hussain Qureshi	Study designing, Supervision & menu script writing	