



RENAL AND URETERIC CALCULI; BENEFITS OF DOUBLE J STENTS IN MANAGEMENT WITH ESWL

draliakbar@hotmail.com

Dr. Syed Ali Akbar¹, Dr. Johar Ali², Dr. Talat Shahzad³

1. Associate Professor
Women Medical College
Abbottabad
2. Professor
Frontier Medical College
Abbottabad
3. Associate Prof.
Women Medical College
Abbottabad

Correspondence Address:

Dr. Syed Ali Akbar
Associate Professor
Women Medical College
Abbottabad.
draliakbar@hotmail.com

Article received on:

14/03/2016

Accepted for publication:

30/07/2016

Received after proof reading:

07/10/2016

ABSTRACT... Objectives: To assess the role of double J stent in management of renal and ureteric calculi measuring 1.5 to 2.5 cm size prior to ESWL. **Period:** 1st January 2015 to 30th December 2015. **Study Design:** Retrospective study. **Methods:** We included 120 patients which were divided in two groups. In group A we took 40 patients in whom double J stents were inserted before ESWL while in group B, 80 patients underwent ESWL without stenting. We included patients of both sex having radio-opaque stones in kidney or proximal ureter measuring 1.5cm to 2.5cm in size in adults (age > 18) years where stone fragmentation resulted after ESWL. The average stone size in both groups was comparable ($p > 0.05$). Patients with urinary tract infections, pregnancy, radiolucent stones, bleeding disorders, larger or small stones, anatomical abnormality, nonfunctioning kidney and where ESWL was not successful after third session were excluded from study. The patients were randomized on basis of their choice for either procedure and majority 80 patients (66 %) refused stenting before ESWL due to fear of invasive procedure and socioeconomic reasons. Patient's pre-operative investigations like complete blood count, urea/creatinine, X-ray & ultrasound KUB and IVU were done. ESWL was done without anesthesia and after complete clearance of fragments stents were removed within three months. **Results:** Out of 120 patients 70 were male (58.33 %) and 50 were female (41.66 %). In group A (with ureteric stenting) there was no ureteric obstruction noticed after ESWL and fragments clearance resulted with mild pain or discomfort in 12(10%) patients. There was delayed clearance of the fragments in patients but that had no impact on patient daily activities. While in group B (without ureteric stenting) 30 (37.5%) patients developed complications like severe colicky pain for which they were hospitalized whereas remaining 50(62.5%) patients had mild to moderate pain with stein-strasse appearance which was managed using oral and systemic analgesics, increase oral fluids and reassurance to the patients. The time of stone fragments clearance was delayed in group A as compared to group B ($p < 0.05$). **Conclusion:** We conclude that double J stent should be passed prior to ESWL in cases of large renal and ureteric calculi to avoid severe colicky pain.

Key words: ESWL (Extra corporeal shockwave lithotripsy), KUB (kidney-ureter-bladder), IVU (intravenous urogram),

Article Citation: Akbar SA, Ali J, Shahzad T. Renal and ureteric calculi; Benefits of double j stents in management with ESWL. Professional Med J 2016;23(10):1198-1201. DOI: 10.17957/TPMJ/16.3352

INTRODUCTION

ESWL has been introduced for breaking of the renal and ureteric calculi since 1980.^{1,2,3} and is considered as 1st line of treatment for the management of small renal and ureteric calculi.⁴ In spite of the improvement in the endoscopic surgery, ESWL is still widely used for the small calculi because it is non-invasive, more effective with less complications⁵, can be performed without anesthesia as day case procedure and is cost effective as compared to endo-urology procedures like URS, PCNL and litholopaxy.⁶ The

success rate depends upon the size, site, number of calculi, nature of stone, function of kidneys and patient structural features.⁷ The insertion of the ureteric double J stent in management of renal calculi before ESWL is questionable. It is thought that stents are helpful in controlling severe colicky pain due to ureteric obstruction after ESWL.⁸ Also stein-strasse phenomenon is less likely to be encountered in cases where stenting was done before ESWL. Ureteric stenting has also well-established role in patients with solitary kidney.⁹ On other hand insertion of ureteric sent in small

calculi can be avoided as it is invasive procedure, done under anesthesia, and also needs removal in specified period of time so we have to keep an eye on cost effectiveness of these procedures as well. Ureteric stents also cause complications like abdominal discomfort, pain in urinary bladder, urinary tract infection, stent encrustation etc.¹⁰ ESWL is contra indicated in conditions like bleeding disorder, infection, nonfunctioning kidney, pregnancy, obesity, aortic and renal artery aneurysm. The aim of this current study was to find out the benefits of ureteral stents in terms of colicky pain after ESWL due to stone fragments.

PATIENTS AND METHODS

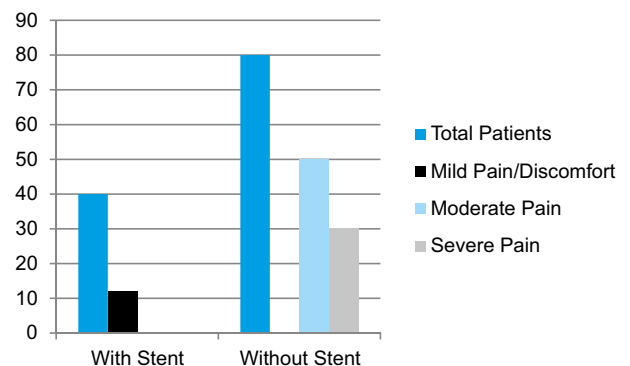
In this retrospective study total 120 patients were included and these patients were divided in two groups. In group A in 40 patients, double J stents were inserted while in group B, 80 patients had ESWL without stenting. The patient counseling was done regarding benefits and complications of ESWL with or without stenting. In this study we included patients of both sex having age > 18 years where the stone size was 1.5 cm to 2.5cm and stone was radio opaque. Those patients with solitary kidney were considered compulsory for ureteric stenting.

Patients with urinary tract infections, pregnancy, radiolucent stones, bleeding disorders and anatomical abnormality were excluded from our study. Patient's pre-operative investigations like complete blood count, urea, creatinine and ultrasound KUB, IVU were done. All those patients were excluded from this study where ESWL was not successful after third session. ESWL was done without anesthesia. Patients were counseled about pain and use of analgesic. Patients were asked to follow up on 3rd, 7th, 14th, 28th, 60th and 90th days and data collected regarding pain, hospitalization and passage of stones per urethra. X-Ray or ultrasound KUB was done as per requirement. After complete clearance of the fragments stents were removed within three months.

RESULTS

Out of 120 patients ureteric stenting was done in 40 patients under spinal anesthesia and

these were removed within three months after clearance of the ureteric stone fragments. In group A There was no colicky pain or ureteric obstruction noticed and fragments clearance was found within 6 weeks. In Group A Twelve patients (30 %) observed with mild pain/discomfort in lumbar or hypogastric region either due to stone passage or ureteric stent. Delayed clearance (5-6 weeks) of the fragments was observed in 30 patients but that did not require medical attention. While in group B, thirty patients (37.5 %) developed complications like severe colicky pain that needed hospitalization and injectable analgesics were given while 50 patients (62.5 %) had mild to moderate pain with stein-stresse appearance which was managed using oral or parenteral analgesics, increase in oral fluids and reassurance to the patients. In group A we observed delay (> 4 weeks) in stone fragments clearance in 30 patients as compared to group B ($p < 0.05$).



DISCUSSION

In urology practice there are dramatic changes by the introduction of ESWL in the treatment of renal and ureteric calculi. Ureteric stent which is hollow plastic tube having multiple opening in proximal and distal end along with the distal end tag for the removal of the stent. The stent is used for continuous drainage of urine when the cause of obstruction is intra luminal, in the ureteric wall or by external compression.^{11,12,13} Ureteric stenting prior to the ESWL is the operative procedure having known complications like mild pain to discomfort, need of anesthesia for insertion followed by removal in given period of time, delayed stone fragments passage and also cost effectiveness of procedure for which

few urologist do not recommend stenting.¹⁴ but those who favors prior stenting give reasons like no obstruction of ureter and also less pain which as a result is better tolerated by the patient and also reduces frequent visits to hospital.^{15,16} In our study we took 120 patients out of which majority 80 patients 66.66 % (group B) refused ureteric stenting despite of counseling either due to the fear of stenting procedure or socioeconomic reasons. They opted to undergo ESWL initially and if faced some complication will consider stenting later while in (group A) where 40 patients 33.33 % individuals opted for stenting before ESWL. Those patients with stenting had mild pain or discomfort either due to stent or stone passage which is comparable to previous studies.¹⁷


In group B data suggested that these patients had moderate to severe pain as compared to group A patients already mentioned in results but such pain scores were not seen in literature. Majority of patients without stenting (group B) in current study were able to pass stone fragments in 1-3 weeks' time after ESWL as compared to those with stenting (group A) where time of stone fragments passage was 5-6 weeks and this finding is again comparable to previous studies.¹⁸ In view of above findings we can say that positive aspect of prior stenting is pain free period of patient after lithotripsy and no tension to surgeon and ESWL technician. The negative aspect of stenting is delayed stone clearance but this has no impact on patient daily activities and higher cost (stenting followed by lithotripsy and then removal of stent). Limitation of our study is unequal patients in groups that may have affected results. Also ratio of male to female in groups can negatively affect pain scores because majority of females have low pain threshold, so we recommend a prospective study should be done on patients either male or female with equal number in both groups.

Copyright© 30 July, 2016.

REFERENCES

- Fábio C, Miranda T, Alexandre D, Fábio V, Giovanni S, Marchini. **Extracorporeal shock wave lithotripsy in the treatment of renal and ureteral stones.** Rev Assoc Med Bras 2015; 61(1):65-71.
- Mohammed S, Al-Marhoon, Omar S, Ismail S. Al-Habsi, Ataalrahman S. Al Balushi, Josephkunju M. **Extracorporeal Shock-wave Lithotripsy Success Rate and Complications: Initial Experience at Sultan Qaboos University Hospital.** Oman Med J. 2013 Jul; 28(4): 255–259.
- Michael Grasso, Bradley Fields Schwartz, **Extracorporeal Shockwave Lithotripsy Treatment & Management.** Jan, 2015.
- Türk C, Petřík A, Sarica K, Seitz C, Skolarikos A, Straub M, Knoll T. **EAU Guidelines on Interventional Treatment for Urolithiasis.** j.eururo.2015.07.041. [Epub].
- Alessandro D, Addressi, Matteo V, Marco R, Francesco P, Emilio Sacco, and Pier Francesco B. **Complications of Extracorporeal Shock Wave Lithotripsy for Urinary Stones: To know and to manage them—A Review** the Scientific World Journal Vol 2012 (2012), Article ID 619820.
- Vikash K, Jayesh V, Dhabalia. **Extracorporeal shock wave lithotripsy in impacted upper ureteral stones: Comparison between stented and non-stented technique.** UROSCAN 2011 | Volume: 27 | Issue: 1 | Page: 151-153.
- Toricelli FC¹, Danilovic A¹, Vicentini FC¹, Marchini GS¹, Srougi M², Mazzucchi E². **Extracorporeal shock wave lithotripsy in the treatment of renal and ureteral stones** Rev Assoc Med Bras 2015; 61(1):65-71.
- Vincent G. Bird & Philipp D. **Urinary tract obstruction: Ureteral stents-weighing up the risks and benefits.** Nature Reviews Urology 9; 13-14 (Jan 2012):10.1038/nrurol.
- Alejandra Mira Moreno, María Dolores Montoya Lirola, Pedro José García Tabar **Incidence of Infectious Complications after Extracorporeal Shock Wave Lithotripsy in Patients Without Associated Risk Factors.** the journal urology, November 2014 Volume 192, Issue 5, Pages 1446–144.
- Milicevic S¹, Bijelic R², Jakovljevic B³. **Encrustation of the Ureteral Double J Stent in Patients with a Solitary Functional Kidney - a Case Report.** Med Arch. 2015 Aug; 69(4):265-8. doi: 10.5455/medarh.2015.69.265-268. Epub 2015 Aug 4.
- IkramUllah* Khurshid Alam* Bakhtawar Gul Wazir** Faridullah Shah* Ahmad Nawaz* **Asif Malik Indications and Morbidity of Indwelling Ureteral Stenting** Ann. Pak. Inst. Med. Sci. 2011; 7(4): 173-175.
- Mudassar Saeed Pansota, Mumtaz Rasool, Muhammad Shahzad Saleem, Shafqat Ali Tabassum, **indications and complications of double J ureteral stenting our**

- experience** Gomal J Med Sci 2013; 11:8-12.(indications of DJ stent in ESWL).
13. Nourparvar P¹, Leung A¹, Shrewsbury AB¹, Weiss AD¹, Patil D¹, Atallah H², Ogan K¹, Carney KJ¹, Master VA³. **Safety and Efficacy of Ureteral Stent Placement at the Bedside Using Local Anesthesia.** J Urol. 2016 Jan 22. pii: S0022-5347(16)00091-4. doi: 10.1016/j.juro.2015.11.083.
 14. Kato Y¹, Yamaguchi S, Hori J, Okuyama M, Kaneko S, Yachiku S. **Utility of ureteral stent for stone street after extracorporeal shock wave lithotripsy Hinyokika Kyo.** 2005 May;51(5):309-14; discussion 314
 15. Shen Pengfei^a, Jiang Min^b, Yang Jie^a, Li Xiong^a, **Use of Ureteral Stent in Extracorporeal Shock Wave Lithotripsy for Upper Urinary Calculi: A Systematic Review and Meta-Analysis** Volume 186, Issue 4, October 2011, Pages 1328–1335.(significant advantages before ESWL).
 16. Mohammed Hassan, Ahmed R. El-Nahas,[□] Khaled Z. Percutaneous nephrolithotomy vs. **extracorporeal shockwave lithotripsy for treating a 20–30 mm single renal pelvic stone** Arab J Urol. 2015 Sep; 13(3): 212–216.(ESWL is associated with few complications and a low cost).
 17. Dudek P, Gołabek T, Jaskulski J, Orłowski P, Bukowczan J, Szopiński T, Chłosta P. **Prospective evaluation of pain associated with indwelling JJ stents following ureterorenoscopic lithotripsy** Przegł Lek. 2013; 70(11):936-8.
 18. Pengfei S¹, Yutao L, Jie Y, Wuran W, Yi D, Hao Z, Jia W. **The results of ureteral stenting after ureteroscopic lithotripsy for ureteral calculi: a systematic review and meta-analysis.** J Urol. 2011 Nov; 186(5):1904-9. doi: 10.1016/j.juro.2011.06.066. Epub 2011 Sep 23.



“You can never cross the ocean unless you have the courage to lose sight of the shore.”

Christopher Columbus

AUTHORSHIP AND CONTRIBUTION DECLARATION

Sr. #	Author-s Full Name	Contribution to the paper	Author=s Signature
1	Dr. Syed Ali Akbar	Write, Statistical and collection of cases	
2	Dr. Johar Ali	Research	
3	Dr. Talat Shahzad	Research	