



# CARCINOMA OF LARYNX; THE DIAGNOSTIC ACCURACY OF COMPUTED TOMOGRAPHY SCAN IN EVALUATION OF THYROID CARTILAGE INVASION

dr.saeedarain786@gmail.com

1. MBBS, FCPS  
Assistant Professor of Radiology  
department Liaquat University of  
Medical and Health Sciences  
Jamshoro (LUMHS)
2. MBBS, FCPS  
Assistant Professor of ENT  
department Liaquat University  
of Medical and Health Sciences  
Jamshoro (LUMHS)
3. MBBS, FCPS  
Associate Professor of Medicine  
department Liaquat University of  
Medical and Health Sciences  
Jamshoro (LUMHS)

#### Correspondence Address:

Dr. Adnan Ahmed  
MBBS, FCPS  
Assistant Professor of Radiology  
department  
Liaquat University of Medical and  
Health Sciences  
Jamshoro (LUMHS)  
Address: E 169 Gulistan e Sajjad,  
Jamshoro road Hyderabad.  
dr.saeedarain786@gmail.com

#### Article received on:

14/06/2016

#### Accepted for publication:

05/08/2016

#### Received after proof reading:

10/09/2016

## INTRODUCTION

Larynx carcinoma is a commonest cancer in the region of neck & head. It is responsible for 40% of overall neck & head cancers. An accepted correlation is observed amid the uses of alcohol & tobacco in emergence of tumor. Histologically a number of these tumors are SCC. The uppermost documented rate of larynx malignancy for men in Asian continent is observed into Karachi, men presenting six times greater risk as compare to females.<sup>2</sup>

Clinically when thyroid cartilage is involved by the tumor, the severity of the symptoms will be worse. Therapeutically the mod of treatment will be changed after thyroid cartilage invasion. The radiologist contributes vitally in staging the laryngeal malignancy and it influences directly on treatment forecast. The earliest revealing of the cartilage invasion in laryngeal carcinoma by means of imaging modality before surgery is important for oncologist as well as surgeon

Dr. Adnan Ahmed<sup>1</sup>, Dr. Mushtaque Ali Memon<sup>2</sup>, Dr. Muhammad Iqbal<sup>3</sup>

**ABSTRACT... Objectives:** The objective of this study was to determine the diagnostic accuracy of CT scan in detecting thyroid cartilage invasion by carcinoma of larynx keeping histopathological findings as a gold standard. **Study Design:** Cross sectional and descriptive study. **Setting:** Department of Radiology of LUMHS, And Karachi Institute of Radiotherapy & Nuclear Medicine. **Period:** February 2013 to August 2015. **Subjects and Methods:** Overall 86 patients were incorporated in this study. All these patients subsequently had their histopathology. The CT outcomes were then contrasted with histopathological results & measures of variables calculated, were based on the results. **Results:** Fifty patients were men & 36 patients were women. The ages varied from 31 to 65yrs with mean age of 50yrs. The specificity & sensitivity of CT in diagnosing thyroid cartilage invasion was 84.5% and 93.3% respectively. Accurateness of CT in diagnosing thyroid cartilage invasion was 86.05%. **Conclusion:** The study established the specificity, sensitivity, negative as well as positive predictive value and accuracy of CT scan for the detection of thyroid cartilage invasion as 84.5%, 93.3%, 98.4%, 56% and 86.05% respectively. Very low negative predictive value was found in patients of age more than 50 years.

**Key words:** Computed tomography, thyroid cartilage invasion, carcinoma larynx.

**Article Citation:** Ahmed A, Memon MA, Iqbal M. Carcinoma of larynx; the diagnostic accuracy of computed tomography scan in evaluation of thyroid cartilage invasion. Professional Med J 2016;23(9):1045-1051. DOI: 10.17957/TPMJ/16.3487

because if thyroid cartilage is invaded in laryngeal cancers patients it would be T4a according to TNM classification. Choice of treatment will be total laryngectomy rather than radiotherapy or partial laryngectomy.<sup>3</sup> Therefore, accurate information about the cartilage invasion is necessary for both oncologist as well as surgeon.

Preoperative evaluation of thyroid cartilage invasions by tumor have always been a difficult problem. Various methods have been used i.e., CT and MRI scans. However, none of the imaging system has the capability to demonstrate neoplastic cartilage invasion with 100% accurateness. MRI is a sensitive technique for the detection of cartilage modifications, with a higher negative predictive value. MRI, though, also bears a elevated false positive degree, that can possibly lead to over treatment of patient. Computed tomography is further specific, however less sensitive, in contrast to MRI. In general, the both methods accuracy is alike.<sup>5,6,7</sup>

Advantages of CT scan is the rapid acquisition time, less artifact, cost effective and easy availability of CT scanners as compare to MRI.<sup>8</sup> The introduction of multi slice spiral CT scanner has even enabled faster and superior evaluation of patient. The Computed Tomography has offered an chance for scanning the head & neck in holding a single breath. It blended with an enhanced resolution as well as eradication of breathing & miss-recording artifacts has taken part greatly to the effectiveness of CT scan. Appropriately carried out and accurately explained imaging study may considerably effect clinical administration and also cost effective.

Based upon the outcomes of this study we are capable of knowing that within our available resources how much CT scan is accurate in detecting thyroid cartilage invasion. It not only indicates upcoming result however also have local records on this problem, which may assist us to develop policies to screen each patient of larynx cancer at an early stage so that we can prevent, the consequences.

**MATERIALS AND METHODS**

This cross sectional descriptive study had performed at Department of Radiology of LUMHS, And Karachi Institute of Radiotherapy & Nuclear Medicine, from February 2013 to August 2015. All the patients of both sexes and of age group between 30 to 65 years were included in this study. All the cases with biopsy proven laryngeal cancer patients (Stage III and IV) having more than six months of duration, patients prior to laryngectomy. All the cases who did not go for laryngectomy after CT examination, patients with previous malignancy other than larynx and cases with known allergy to contrast media were excluded from the study. Cases with biopsy confirmed tumor of larynx fulfilling inclusion criteria upon history referred to computed tomography Scan Department at KIRAN to exclude thyroid cartilage invasion, were integrated in the study. A Concise history concerning disease interval and verbal approval were collected from patient. Every patient was underwent computed tomography scanner, which extended from skull

base to clavicle 5mm thick and 1.0 pitch and reconstruction interval of 5mm contiguous axial and coronal sections were taken after intravenous contrast enhancement. Images were analyzed by experience radiologist for presence or absence of cartilaginous invasion by tumor. After surgical procedure the specimen were reviewed by a competent histopathologist for histopathological findings. Histopathological reports of patients were collected. The involvement of cartilage by cancer was definitively determined by histopathological studies, that is Gold Standard. All the information was documented on proforma by the researcher.

**DATA ANALYSIS PROCEDURES**

The obtained data was analyzed, on SPSS V.16.0. Percentage & frequency were calculated for categorical variables such as gender, age groups, carcinoma of larynx, stages. Cross tabulation were presented for frequency of CT and Histopathology outcome like false negative & positive, true negative & positive. Mean, STD, 95% confidence interval were calculated for age and duration of disease.

**RESULTS**

A total of 86 patients with biopsy proven carcinoma of larynx were included in this study. The average age of the patients was 50.48 ± 8.26 years (95%CI: 48.71 to 52.25). Similarly the average duration of disease was 8.28 ± 1.54 months (95%CI: 7.95 to 8.61) as presented in table 1. Out of 86 patients, 50(58.1%) were male and 36(41.9%) were female with male to female ratio was 1.38:1 as shown in Table-I.

Variables	No. of patients / (%)
<b>AGE (mean+SD)</b>	50.48 ± 8.26
<b>Age groups</b>	
31-40	11
41-50	33
51-60	35
>60	07
<b>GENDER</b>	
Male	50(58.1%)
Female	36(41.9%)
<b>Disease duration (mean+SD)</b>	8.28 ± 1.54

Table-I. Demographic variables (n=86)

Squamous carcinoma was observed in 84(97.7%) cases and columnar was found in 2(2.3%) cases as shown in Figure-1.

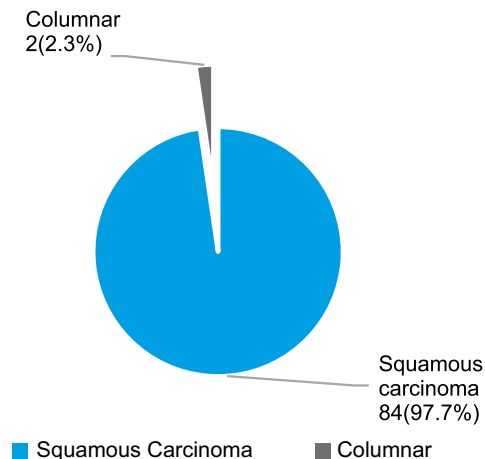


Figure-1. Carcinoma of larynx n=86

Regarding stage of carcinoma, 37(43%) was in stage III and 49(57%) cases were in stage IV (Figure-2).

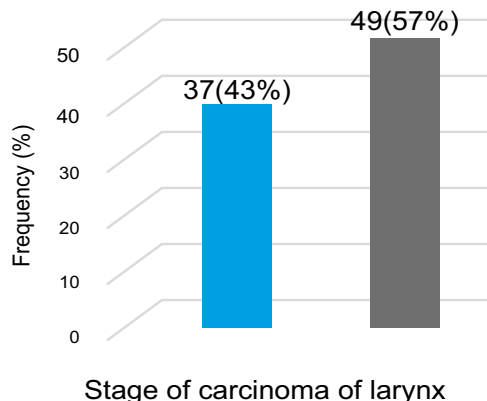


Figure-2. Stage of carcinoma of larynx n=86

Outcomes of CT scan in detecting thyroid cartilage invasion by carcinoma of larynx keeping histopathology. Thyroid cartilage invasion had observed in 82.6% patients with Sensitivity, specificity, positive predictive and negative predictive value of CT scan were 84.5%, 93.3%, 98.4% and 56% respectively as well as accuracy of CT scan was 86.05%.Table-II.

Thyroid Cartilage invasion on CT	Thyroid Cartilage invasion on Histopathology		Total n (%)
	Positive	Negative	
CT + ve	60	01	61
CT - ve	11	14	25
<b>Total</b>	<b>71(82.6%)</b>	<b>15(17.4%)</b>	<b>86</b>

Table-II. Diagnostic accuracy of CT scan in detecting thyroid cartilage invasion by carcinoma of larynx keeping histopathology

Sensitivity =  $60/71 \times 100 = 84.5\%$   
 Specificity =  $14/15 \times 100 = 93.3\%$   
 Positive predictive value =  $60/61 \times 100 = 98.4\%$   
 Negative predictive value =  $14/25 \times 100 = 56\%$   
 Accuracy =  $(60 + 14)/86 = 86.05\%$

**DISCUSSION**

To determine the specific clinical level of malignancy extent in larynx is the most significant aspect guiding management decisions among cases with localized laryngeal tumor. Histopathologic series using sections of complete organ, have recorded patterns of malignancy spread & obstacles to cancer growth within larynx, which offers anatomic basis for malignancy staging and function-cautious preservation laryngeal surgery.<sup>10,11</sup> Tomographic imaging, especially

CT, has been incorporated in clinical staging of additional clinical interpretation of extent of cancer and functions of vocal cord in establishing stage of malignancy. Clinical malignancy stage was applied regularly for decision making for either organ sparing energy emission or primary surgery as definitive treatment. Conventionally, cases with early-stage (I & II) malignancies were treated through primary radiation, and cases with further advanced stages malignancies (III&IV) were treated with overall laryngectomy, without/with adjuvant postoperative radiation. However, patients' care patterns with larynx malignancy keep on changing. The accomplishment of endoscopic laser-supported methods & partial laryngeal surgical technique, have resulted to a considerable spread in partial laryngeal,

function-sparing limitations for cases with initial or even rather advanced malignancies.<sup>12,13</sup> Additionally, with the induction of shared chemoradiotherapy as an option to overall laryngectomy, organ conserving methods have extensively been accepted for cases with stages III & IV malignancies.<sup>12,13</sup> Such chemo-radiotherapy methods have exhibited successful larynx conservation, which cured rates like primary surgery in most of cases. In cases with advanced (i.e. T4) malignancies, but reduced rates of organ conservation and greater complication rates are projected, encouraging several oncologists to suggest primary laryngectomy, especially when gross cartilage invasion by malignancy is obvious. Thus, cartilage invasion has turned out to be a considerable issue in tumor staging as well as in selection of treatment from total laryngectomy & larynx preservation. As indicated by 6<sup>th</sup> edition of AJCC staging criteria, minor thyroid cartilage invasion (for instance inner cortex) is adequate to categorize a malignancy as T3, & invasion via cartilage or into further laryngeal soft tissues will categorize the malignancy as T4. This remained unchanged in 2010 edition (ie, 7<sup>th</sup>.Ed.), excluding that stage IV malignancies are distinguished into IVa & IVb; IVb reflects "very advanced local/regional disease" characterized by contribution of carotid artery, mediastinal structures or prevertebral space.<sup>14</sup>

Beitler et al<sup>15</sup> projects a vigilant retrospective clinic pathologic analysis of accurateness of pre-treatment computed tomography scanning to forecast cartilage invasion & extra laryngeal cancer spread. Routine interpretation of preoperative CT scans and histopathology statements from 107 cases experiencing overall laryngectomy throughout a 10-yr period, were evaluated for existence of cartilage invasion (@ inner thyroid cortex) or penetration (@ both inner & outer cortex). Associations of CT indications & histopathologic outcomes were established. The study established that a higher rate (63%) of incidences had CT confirmation of penetration or cartilage invasion, as well as 80% had confirmation of invasion upon histopathology. When CT recommended extra laryngeal extension, there has

been 81% association with pathology outcomes. Remarkably, extra laryngeal spread lacking penetration of cartilage was observed in 18 (40%) of 45 incidences. Surgeons had long established the prognostic importance of extra laryngeal spread via cricothyroid membrane hurdles, even while cartilage invasion was not present. The authors appropriately warned that computed tomography scanning had not been greatly sensitive for additional laryngeal syndrome. If significant problem, though, is cartilage invasion, just 4 (7.4%) out of 54 incidences that were studied as regular thyroid cartilage possessed histopathologic confirmation of cartilage penetration of thyroid. While cartilage infiltration was observed on CT, histopathology confirmed it in 74%, & 87% of incidences possessed at least invasion of pathologic cartilage. However, in our study Thyroid cartilage invasion was observed in 82.6% cases with specificity, sensitivity, negative & positive predictive value of CT scan were 93.3%, 84.5%, 56% and 98.4% respectively as well as accuracy of CT scan was 86.05%. Careful serial sectioning of entire larynx can possibly have exhibited a yet higher association. At last, the pretreatment clinical stage of malignancy, cancer site, or criteria applied to select cases for overall laryngectomy were unreported in the above study, rendering it not possible to evaluate any bias concerning cartilage invasion or either T3 & T4 malignancy occurrence in the study cohort or variations among supraglottic or glottic primaries. Therefore, the worth of computed tomography staging in effecting the ending clinical malignancy stage can't be established in the aforementioned study.

Thus, how to read these findings and how CT findings must effect our selection of suitable prime treatment modality in cases having advanced laryngeal malignancy? Effectual cancer staging must integrate as much functional, radiographic, clinical, and biopsy data as possible for predicting prognosis following standardized treatment. Although, when application of clinical staging parameters are done for selecting varying treatments for alike staged malignancies, cautiously gathered prospective clinical result

information are required to encourage judgment.

Cartilage invasion is usually believed as contraindication of radiation treatment and voice preservation surgical techniques. Chemoradiotherapy was established as an organ-conservative therapy in advanced infection, as well as a reliable technique to detect intra cartilaginous malignancy spread can possibly help in selection of cases for this therapy. Accurate detection of cartilage invasion is significant, since a false positive explanation of malignancy involvement can possibly cause over-therapy, or in worst condition to a unnecessary total laryngectomy. Both CT & MRI are extensively applied in laryngeal cancer staging. CT is believed to be a moderately particular technique to detect intra cartilaginous malignancy spread, however it can possibly cause the level of cartilage invasion being undervalue miscalculated.<sup>15,16</sup> Several studies exhibited that MRI is further sensitive in contrast to CT in cancer spread evaluation into cartilage, however it can possibly cause an overvalue miscalculate of spread.<sup>16</sup>

A total of 139 cartilages were evaluated (37 thyroid, 37 cricoid and 65 arytenoid cartilages). Among these cartilages, 49 (16 thyroid, 11 cricoid and 22 arytenoid cartilages) had neoplastic invasion. In thyroid cartilage, the sensitivity of increased density was 0.81 and the specificity of chondrolysis was 0.91; the specificity of both findings together was 0.95. In cricoid cartilage, the sensitivity of increased density was 0.73; the specificity was 0.73; the specificity of chondrolysis was 0.96 and specificity of both findings was 1. In arytenoid cartilage, the specificity of increased density was 0.67; the specificity of chondrolysis was 0.98; and the specificity of both findings together was 1. Considering all 139 cartilages together, the sensitivity of increased density was 0.69 and the specificity of chondrolysis was 0.96. Setting all cartilages in a single group and considering both of these CT findings, the sensitivity was 0.89 and the specificity was 0.76.<sup>17</sup> The finding of the above study is similar to our study in terms of sensitivity and specificity. Most of the laryngeal neoplasm originate from true

vocal cords (especially, in anterior one-third of the cords) which are adjacent to thyroid cartilage. This fact could make the direct invasions of neoplasms to thyroid cartilage more frequently than is seen as increased density. Furthermore, this close relation could result in neoplastic irritation and thus thyroid cartilage reaction which could be resulted in higher sensitivity.<sup>18</sup> The variations in ability of CT to detect neoplastic laryngeal cartilage invasion in some part are due to different CT techniques used (e.g., applying scan times of 4–9 s/slice and slice thickness of 4–6 mm in earlier studies). Another important reason is considering variable diagnostic criteria for neoplastic invasion of the laryngeal cartilage. Erosion is a specific CT finding for diagnosis of neoplastic cartilage invasion, which could be due to the fact that erosion in the majority of cases develops in response to direct neoplastic involvement in contrary to some nonspecific findings such as increased density which could also happen in response to inflammatory reactions in addition to neoplastic involvement. This finding is similar to other reports which have shown specificities of 0.86–1 in detection of thyroid, cricoid and arytenoids neoplastic invasion.<sup>18-20</sup> The higher specificities of cartilage erosion in CT could mean the higher positive predictive value of this finding and makes it a suitable indicator for management and treatment planning. Thyroid cartilage can be physiologically ossified in an irregular pattern in comparison to arytenoid cartilages. This physiologic ossification may be mistaken with lysis due to neoplastic invasion. Therefore, the specificity of the erosion in CT is higher for neoplastic invasion of the arytenoid.<sup>21</sup> Otherwise; this finding has an acceptable specificity for detection of neoplastic cartilage invasion.


## CONCLUSION

The study observed the specificity, sensitivity, positive & negative predictive value and accuracy of CT scan to detect thyroid cartilage invasion was 84.5%, 93.3%, 98.4%, 56% and 86.05% respectively. Bigger sample size studies are required to more conformation of these results.

Copyright© 05 Aug, 2016.

## REFERENCE

1. Nikolaou AC, Markou CD, Petridis DG, Daniilidis IC. **Second primary neoplasms in patients with laryngeal carcinoma.** *Laryngoscope.* 2000; 110:58-64.
2. Bhurgri Y, Bhurgri A, Nishter S, Ahmed A, Usman A, Pervez S, et al. **Pakistan - Country profile of cancer and cancer control 1995-2004.** *J Pak Med Assoc.* 2006; 56(3):124-30.
3. Castelijns JA, Golding, RP, Schaik C, van Valk J, Snow GB. **MR findings of cartilage invasion by laryngeal cancer: value in predicting outcome of radiation therapy.** *Radiology.* 1990; 174:669-73.
4. Quinn FB. **Laryngeal carcinoma 2007: an overview.** [Online]. 2007 [cited 15 Jan 2011]; Available from: URL: <http://www.utmb.edu/otoref/grnds/Laryngeal-CA-070720/Laryngeal-CA-070720.mht>
5. Becker M, Zbaren P, Laeng H, Stoupis C, Porcellini B, Vock P. **Neoplastic invasion of the laryngeal cartilage: comparison of MR imaging and CT with histopathologic correlation.** *Radiology.* 1995; 194:661-9.
6. Castelijns JA, Becker M, Hermans R. **Impact of cartilage invasion on treatment and prognosis of laryngeal cancer.** *Eur Radiol.* 1996; 6:156-69.
7. Castelijns JA, Gerritsen GJ, Kaiser MC, Valk J, Van Zanten TE, Golding RG, et al. **Invasion of laryngeal cartilage by cancer: comparison of CT and MRI.** *Radiology.* 1988; 167:199-206
8. Mukherji SK, Weeks SM, Costillo M, Yankaskas BC, Krishnan LA, Schiro S. **Squamous cell carcinomas that arise in the oral cavity and tongue base: can CT help predict perineural or vascular invasion?** *Radiology.* 1996; 198:157-62.
9. Fernandes R, Gopalan P, Spyridakou C, Joseph G, Kumar M. **Predictive indicators for thyroid cartilage involvement in carcinoma of the larynx seen on spiral computed tomography scans.** *J Laryngol Otol.* 2006; 120(10):857-60.
10. Kirchner JA: Fifteenth Daniel C Baker Jr Memorial lecture: **What have whole organ sections contributed to the treatment of laryngeal cancer?** *Ann OtolRhinol Laryngol.* 1989; 98:661-7.
11. Kirchner JA: **Two hundred laryngeal cancers: Patterns of growth and spread as seen in serial section.** *Laryngoscope.* 1977; 87:474-82.
12. Hoffman HT, Porter K, Karnell LH, et al: **Laryngeal cancer in the United States: Changes in demographics, patterns of care and survival.** *Laryngoscope.* 2006; 116(suppl 11):1-13.
13. Chen AY, Halpern M: **Factors predictive of survival in advanced laryngeal cancer.** *Arch Otolaryngol Head Neck Surg.* 2007; 133:1270-6.
14. American Joint Committee on Cancer: **Larynx.** In: **Greene FL editors: American Joint Committee on Cancer: AJCC Cancer Staging Manual.** New York: Springer; 2010.p. 57-68
15. Beitler JJ, Muller S, Grist WJ, Corey A, Klein AM, Johns MM. **Prognostic accuracy of computed tomography findings for patients with laryngeal cancer undergoing laryngectomy.** *J Clin Oncol.* 2010 May 10; 28(14):2318-22
16. Zbaren P, Becker M, Läng H. **Staging of laryngeal cancer: endoscopy, computed tomography and magnetic resonance versus histopathology.** *Eur Arch Otorhinolaryngol.* 1997; 254 (Suppl. 1):117-22.
17. Kashany SS, Malek M, Mazaher H, Sharifian H. **The Diagnostic Accuracy of Computed Tomography in Neoplastic Invasion of the Laryngeal Cartilage.** *Iran. J. Radiol.* 2008; 5(1):11-7.
18. Becker M. **Neoplastic invasion of laryngeal cartilage: radiologic diagnosis and therapeutic implications.** *Eur J Radiol.* 2000; Mar; 33(3):216-29.
19. Becker M, Zbaren P, Delavelle J, Kurt AM, Egger C, Rufenacht DA. **Neoplastic invasion of the laryngeal cartilage: reassessment of criteria for diagnosis at CT.** *Radiology.* 1997 May; 203(2):521-32.
20. Sulfaro S, Barzan L, Querin F, Lutman M, Caruso G, Comoretto R, et al. **Staging of the laryngohypopharyngeal carcinoma. A 7-year multidisciplinary experience.** *Arch Otolaryngol Head Neck Surg.* 1989 May; 115(5):613-20.
21. Zbaren P, Becker M, Läng H. **Pretherapeutic staging of laryngeal carcinoma: clinical findings, computed tomography, and magnetic resonance imaging compared with histopathology.** *Cancer.* 1996 Apr 1; 77(7):1263-73.



*“Those who follow the crowd usually get lost in it.”*

Unknown

**AUTHORSHIP AND CONTRIBUTION DECLARATION**

Sr. #	Author-s Full Name	Contribution to the paper	Author=s Signature
1	Dr. Adnan Ahmed	1st Author	
2	Dr. Mushtaque Ali Memon	2nd Author	
3	Dr. Muhammad Iqbal	3rd Author	