

DCP WITH INTRAMEDULLARY INTERLOCKING NAILS;

Compare the outcome in closed diaphyseal humeral shaft fracture with type A1-2 , A2-2 and A3

Dr. Imran Khan, Prof. Dr. Muhammad Ayub Laghari, Dr. Shakeel Ahmed Memon, Dr. Muhammad Khan Pahore

ABSTRACT.. Objective: The objectives of the study are to compare the outcome of dynamic compression plates with intramedullary nails in closed diaphyseal humeral shaft fracture with type A1-2 , A2-2 and A3. **Study Design:** Comparative study. **Place and duration of study:** Study was carried out at the Orthopaedics Unit-I, Liaquat University Hospital Hyderabad / Jamshoro , from March 2007 to Feb 2009. **Methodology:** Study consisted of 40 patients of diagnosed cases of closed diaphyseal humeral shaft fracture with type A1-2 , A2-2 and A3. Patients were divided in two groups. Group A for dynamic compression plates and group B for intramedullary nails. Detailed Clinical examination of the patient was done and recorded in proforma. Systemic review was also done to see any major or minor head injury. All patients underwent for base line investigation. In Inclusion criteria; patients with type A1-2 , A2-2 and A3-2 closed diaphyseal humeral shaft fracture ,bilateral fractures, associated with minor head injuries, age between 20-40 years and fracture not more than two weeks old. In Exclusion criteria ; Open fracture, associated with severe chest or abdominal injuries, pathological fractures and malunited fractures with neurological deficit. Follow up of all these patients was done .1st four visit after every week , then alternet week upto 3rd month then monthly upto 6 month to assess any complication. Results were prepared with help of tables and graphs. Data was analyzed through SPSS software version 16.0. **Results:** In both groups male were 35(87.5%) and female 5(12.5%) with male: Female Ratio of 7:1. There was wide variation of age ranging from a minimum of 20 year to 40 year in both group. The mean age was 29.78+3.5 years. The most common cause of fracture shaft of humerus was road traffic accident (RTA). There were 23(57.5%) patients who sustained fractures of the humerus following road traffic accidents. Eight (20%) cases had fractures shaft of humerus after fall from height and 9 (22.5 %) cases had fractures shaft after assault. The Fracture pattern was Oblique in 22(55%) cases ,Transverse in 12(30%) and Spiral in 6(15 %). Severity of post operative pain in both groups was recorded. Mild pain was felt in 10(50%) patients of DCP group and 6 (30%) patients of IMN group, Moderate pain was seen in 7(35%) patients of DCP group and 10 (50%) patients of IMN group, severe pain was described by 3(15%) patients in DCP group and 4 (20%) patients in IMN group. The complications seen in this study were Infection (1(5%) patients in DCP VS 0(0%) patients in IMN group), Iatrogenic palsy of radial nerve (1(5%) patients in DCP VS 0 (0%) patients in IMN group), Non union (1(5%) patients in DCP VS 1 (5%) patients in IMN group),Severe impingement (0(0%) patients in DCP VS 3 (15%) patients in IMN group), Adhesive capsulitis (0(0%) patients in DCP VS 2 (10%) patients in IMN group) . However minimal loss of fixation in 1 (5%) cases and late fracture occurred in one case 5%. The duration of hospital stay varied from 1 to 20 days. It was longer about -10-20 days in 12(60%) of DCP patients as compared to IMN cases where majority 11(55%) were discharged within 1 to 10 days. The mean hospital stay in DCP group was 15 days and IMN group was 13.5 days. **Conclusions:** Dynamic compression plate is a safe and effective procedure for treatment of humeral shaft fractures. With low threshold of complications it has significant advantages over intramedullary nails procedure revealed with earlier mobilization, minimum hospitalization and fast recovery towards normal life.

Key words: Intramedullary nails, Dynamic compression plate

Article Citation

Khan I, Laghari MA, Memon SA, Pahore MK. Dynamic compression plates with intramedullary nails; compare the outcome in closed diaphyseal humeral shaft fracture with type A1-2, A2-2 and A3-2. Professional Med J 2013;20(6): 999-1005.

INTRODUCTION

Musculoskeletal injuries , including fractures and dislocations are foundation of the specialty of orthopedic surgery¹. The goal of any fracture treatment is to restore the function of injured limb early and completely but all circumstances may not precise reduction nor absolute stable fixation². Fractures of the humeral shaft are commonly accounting for approximately 3% of all fractures³. Simple humeral

shaft fractures can be treated non operatively with good results in most cases⁴. Non operative treatment requires a long period of immobilization, which carries a risk of prolonged shoulder joint stiffness. Furthermore , non union after conservative treatment of the these fractures does occur upto 10% of the cases and treatment of this condition can be very difficult⁵.There is growing interest in treating even simple humeral shaft fractures by dynamic

compression plate (DCP) fixation or intramedullary (IM) nailing in order to avoid these problems and to allow earlier mobilization and rapid return to work⁶. Compression plates and interlocking intramedullary nails are the two most popular devices for achieving fracture stabilization. Close intramedullary nailing of fractures of the humeral shaft is used in the treatment of multiple trauma patients, fractures with overlying burns, patients with osteopenic bones, pathological fractures and segmental fractures⁷. In transverse or short oblique fracture, AO compression plates can be used. Open reduction and internal fixation usually ensures high likelihood of anatomic reduction and union. However its disadvantages include the need for extensive dissection risk of infection, injury to radial nerve the possible mechanical failure in osteoporotic bone and possible need for plate removal at a later date. Intramedullary nailing requires less soft tissue disruption and preserve the fracture haematoma . However the use of intramedullary nail has been associated with post operative shoulder pain and stiffness due to impingement from prominent implants. Dabezies et al⁸ achieved a 97% union rate using a modern plate and screw fixation technique. Seidel reported 100% union in series of 80 of fractures treated with locked humeral nails inserted by closed techniques. Chapman³ concluded that plates and nails both provide predictable stabilization and ultimately healing of the fracture. A randomized controlled study carried out at King George Medical University ,Lucknow proved that intramedullary nail can be considered a better surgical option for the management of diaphyseal fracture of the humerus as it offers a short union time and lower incidence of serious complications like infection. However , there appears to be no difference between the two groups in terms of the rate of union and functional outcome⁹. Bhandari M et al states that plate fixation also reduced the risk of shoulder problems in comparison to intramedullary nails. Plate fixation of humeral shaft fractures may reduce the risk of re-operation and

shoulder impingement¹⁰.

MATERIAL & METHODS

This study was carried out in Orthopaedics Unit-I, Liaquat University Hospital Hyderabad / Jamshoro , from March 2007 to Feb 2009. Study consisted of 40 patients admitted through the outpatient department, as well as from casualty department of orthopaedic Unit-II Liaquat University Hospital Hyderabad / Jmashoro. All data was entered in a specified proforma designed for this purpose. Patients were divided in two groups. Group A for dynamic compression plates and group B for intramedullary nails. Detailed Clinical examination of the patient was done and recorded in proforma. Systemic review was also done to see any major or minor head injury. All patients underwent for base line investigation.

Inclusion Criteria

patients with type A1-2 , A2-2 and A3-2 closed diaphyseal humeral fracture, bilateral fractures, associated with minor head injuries, age between 20-40 years and fracture not more than two weeks old.

Exclusion Criteria

Open fracture, associated with severe chest or abdominal injuries, pathological fractures and malunited fractures with neurological deficit. Follow up of all these patients was done. 1st four visit after every week , then alternet week upto 3rd month then monthly upto 6 month to assess any complication. Results were prepared with help of tables and graphs. Data was analyzed through SPSS software version 16.0.

RESULTS

The 40 cases of closed diaphyseal humeral shaft fracture were operated. Group A for dynamic compression plates (DCP) while group B for intramedullary nails (IMN), each group comprising of 20 patients .In dynamic compression plates (DCP) group 17(85 %) were male and 3(15%) female. Ratio male: female ratio of 5.6:1 while In intramedullary nails

(IMN) group 18(90 %) were male and 2(10 %) female with male: female ratio of 9:1. There was wide variation of age ranging from a minimum of 20 year to 40 year in both group. The mean age was 29.78+3.5 years. The most common cause of fracture shaft of humerus was road traffic accident (RTA). There were 23(57.5%) patients who sustained fractures of the humerus following road traffic accidents. Eight (20%) cases had fractures shaft of humerus after fall from height and 9 (22.5 %) cases had fractures shaft after assault (Fig 1).

The Fracture pattern was Oblique in 22(55%) cases,

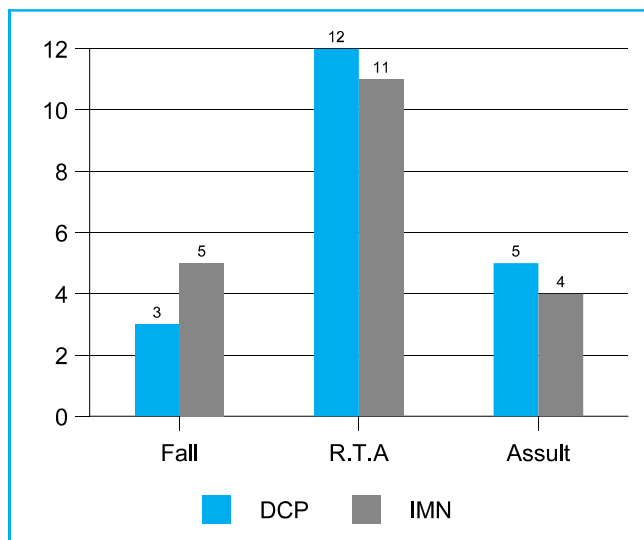


Fig-1. Mode of injury

Transverse in 12 (30%) and Spiral in 6(15%) . Severity of post operative pain in both groups was recorded. Mild pain was felt in 10(50%) patients of DCP group and 6 (30%) patients of IMN group, Moderate pain was seen in 7(35%) patients of DCP group and 10 (50%) patients of IMN group, severe pain was described by 3(15%) patients in DCP group and 4 (20%) patients in IMN group (Fig No.2).

The complications seen in this study were Infection (1(5%) patients in DCP VS 0(0%) patients in IMN group), latrogenic palsy of radial nerve (1(5%) patients in DCP VS 0 (0%) patients in IMN group), Non union (1(5%) patients in DCP VS 1 (5%) patients in IMN

group), Severe impingement (0(0%) patients in DCP VS 3 (15%) patients in IMN group), Adhesive capsulitis (0(0%) patients in DCP VS 2 (10%) patients in IMN group). However minimal loss of fixation in 1 (5%) cases and late fracture occurred in one case 5% (Fig No.3).

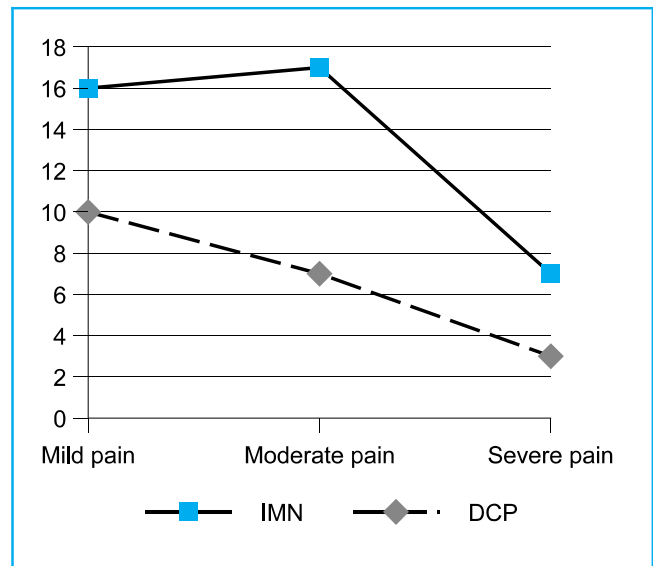


Fig-2. Postoperative pain

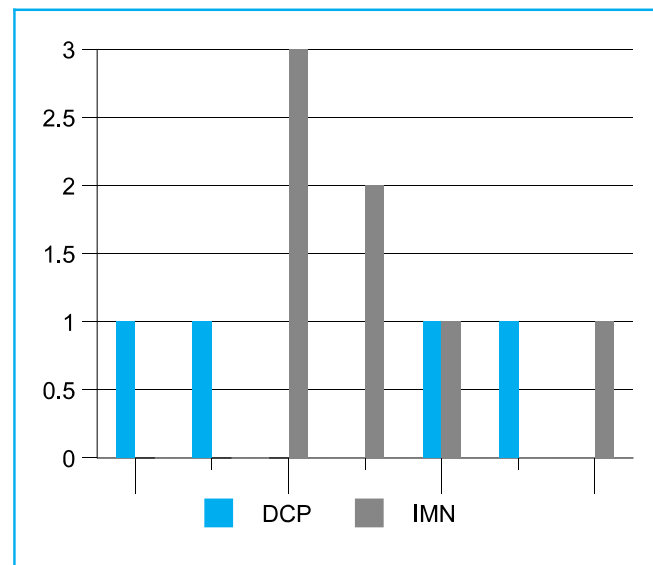


Fig-3. Postoperative complications

The duration of hospital stay varied from 1 to 20 days.

It was longer about -10-20 days in 12(60%) of DCP patients as compared to IMN cases where majority 11(55%) were discharged within 1 to 10 days. The mean hospital stay in DCP group was 15 days and IMN group was 13.5 days.

DISCUSSION

Diaphyseal fractures of the humerus are definitively not subjects for "golden standard therapies". Although there exists a huge amount of creativity in developing new techniques and implants for the fixation of these fractures, The variety of fracture patterns and situations make clinical studies difficult to be compared with and very often the decision of treatment is led mainly by personal experience, which is connected with very subjective bias¹¹.

On one side we find general reservations towards operative treatment of these fractures¹². On the other side, when accepting an indication for internal fixation, some authors prefer plating as a general procedure for humeral fractures, others vote for nailing. Analyzing literature each opinion finds support, which shows that there is no definitive answer. Chapman et al¹³ compared the clinical and radiographic results for locked intramedullary nails and plates used in the treatment of humeral diaphyseal fractures. They stated from their results that for patients requiring surgical treatment of a humeral shaft fracture, intramedullary nailing and compression plating both provide predictable methods for achieving fracture stabilization and ultimate healing.

Discussion concerning surgical treatment of humeral shaft fractures and Various methods have been introduced for the management of humeral shaft fracture with good results¹⁴. This study was carried out to compare the functional out come between dynamic plates and intramedullary nails. The male to female ratio seen in DCP group was 5.6:1 as compared to IMN group where it was 9:1. The higher rate of fracture in male clearly correlated with the life style of male,

especially, in our part of world. The males are more involved in outdoor activities and the young male are more enthusiastic about life and careless drivers. Female usually have sedentary life style and less involved in driving which is a common cause. However the male to female ratio given by Mirdad TM¹⁴ is 9.8:1, Reyes-Saravia GA¹⁵ is 3.4:1 and Akram R¹⁶ is 1.3:1. The age ranged from 21 to 40 years in both groups with mean age of 29.78 years. The fractures were most common in the 3rd and 4th decades in our study. The other series also show higher incidence of fractures in younger age groups. However Tsai CH showed age range from 9 to 82 year with the mean age for females was 50.8 years and for males 31.7 years¹⁷ and Gadegone WG¹⁸ showed mean age was 37 years.

The present study showed the most common mechanism of humeral shaft fractures as road traffic accidents with 23(57.5 %) patients followed by assault 9(22.5%) and fall from height included 8(20%). In the study of Memon FA¹⁹, thirty seven (63.7%) patients sustained their fractures and soft tissue injuries as a result of road traffic accident and 21 (36.2%) sustained the same problem as result of domestic fall. In the study conducted by Putti AB²⁰, out of 34 patients the cause of the injuries leading to admission was RTA in 28 (82.3%). In the study carried out by Sitati FC and Kingori J²¹, Out of 42 fractures shaft of humerus, 31(73.8%) were secondary to RTA while the remaining were due to fall from height 4(9.5%) and assault 2(4.7%) cases. The findings of present study matches these studies. The road traffic accident is the most common cause of fracture shaft of humerus. Due to limited sources of income, motorbile is the main conveyance of middle class in its accidents, humerus is commonly affected.

The clinical parameters were further supported by x-ray which revealed Oblique fracture in 22(55%) cases, Transverse fracture in 12(30%) and Spiral fracture in 6(15%). In our study postoperative was feel more pain in IMN as compare to DCP group. In this study

moderate to severe pain (IMN=35% VS DCP=25%) and mild to moderate pain was (IMN=40% VS DCP=42.5%). In our study majority of postoperative complications were found higher in IMN group as compared to DCP group. Infection is virtually confined to open fractures in which the wound is contaminated by organisms carried in from outside the body. Exceptionally, a closed fracture may become infected when it is converted into open fracture by operative intervention. Wound infection occasionally remains superficial and the bone escapes but more often the infection extends to the bone and gives rise to osteomyelitis²².

In the present study we had 1 (DCP=5% VS IMN=0%) case of infection. Staph. Aureus was isolated on culture which was sensitive to 1st generation cephalosporins, amoxycillin and clavulonic acid and fucidic acid. Although treatment was started but the wound needed several thorough debridements before the infection settled. However frequency of wound infection given by Bell et al,²³ in a series of 33 patients treated with dynamic compression plate, there was 1(3%) case of infection.

There was one case of radial nerve injury (DCP=5% VS IMN=0%). The radial nerve injury was associated with oblique in the middle third of humerus. When it was opened for plating the radial nerve was lacerated between two bony fragments. In the respective IMN and DCP groups rate have been reported of iatrogenic radial nerve palsy were 2.6 to 14.3%²⁴ and 2 to 5%^{25,26}. Reported rates of iatrogenic comminution during nail insertion were 7.7% to 10%,^{24,27} and the re-operation rate was higher in patients undergoing IMN fixation^{28,29}. In our study, both groups were comparable in terms of functional outcomes and rates of union. The complication rate was higher in the IMN group (mostly pertaining to shoulder pain).

In our study non-union was seen in one (5%) case in each groups, which were managed by freshening of

the bone ends and with bone grafting. The incidence of non union reported in the literature is between 0–8%³⁰⁻³⁷. Hems and Bhullar suggested that antegrade nailing affects fracture healing by distracting the fracture and soft tissues³⁰.

In our study restriction of shoulder abduction due to impingement of the nail was noted in 3(15%) cases, which were later managed by removal of the nail; implant failure was noted in one case due to breakage of the nail at the site of the distal locking screw; this was managed by DCP and bone grafting. It has been reported that antegrade nailing can cause damage to the rotator cuff, leading to problems with shoulder function and the range of movements. Our study resulted in three cases of shoulder impingement in the IMN group.

In our study adhesive capsulitis occurred in 2(10%) cases of IMN group. Seidel's interlocking nailing has yielded good results, but the shoulder function was not assessed. Persistent shoulder pain is common. The cause of pain could be disruption of the rotator cuff in its avascular zone (within 1 cm of its insertion to the greater tuberosity), leading to poor healing. Antegrade insertion may cause adhesive capsulitis and shoulder pain, but does not affect long-term function²⁰.

Longer the duration of hospital stay, greater the burden on the patient financially and psychologically. Ideal treatment should therefore minimize the duration of hospital stay. The hospital stay in this study ranged from 1 to 20 days in both groups with mean length of hospitalization as 12.46 days in DCP and 10.3 days in IMN group. It is comparable to other studies given by different authors like 5 days¹⁶ in IMN and 7.5 days (range, 5–14 days)¹³.

CONCLUSIONS

Dynamic compression plate is a safe and effective

procedure for treatment of humeral shaft fractures. With low threshold of complications it has significant advantages over intramedullary nails procedure revealed with earlier mobilization, minimum hospitalization and fast recovery towards normal life.

Copyright© 13 Jul, 2013.

REFERENCES

1. Wiss DA. **What's new in orthopaedic Trauma;** Am J Bone and joint Surg 2001;83:1762-72.
2. Persen SM, Cordey J. **The concept of interfragmentary strain.** In: Uthoff H.K. Current Heidelberg New York Springer 1980;63.
3. Chapman JR et al. **Randomized prospective study of humeral shaft fracture fixation: intramedullary nails versus plates.** J Ortho Trauma 2000;14:162-66.
4. Gregory PR. **Fractures of the shaft of the humerus.** In Rockwood and Green's Fracture in adults. Lippincott Williams & Wilkins, Philadelphia 2001;973-996.
5. Jupiter JB, Deck MV. **Ununited humeral diaphyses.** J shoulder Elbow Surg 1998;7:644-653.
6. Rommens PM, Verbruggen J, Broos PL. **Retrograde locked nailing of humeral shaft fractures. A review of 39 patients.** J bone joint Surg 1995;77:84-89.
7. Crenshaw AH. **Fractures of shoulder Girdle, Arm and forearm.** Campbell's Operative Orthopaedics 10 th ed. 2003;3:2296-98.
8. Dabiezies EJ, Banta CJ, Murphy CP, d'Ambrosia RD. **Plate fixation of the humeral shaft for acute fractures, with and without radial nerve injuries.** J Orthop Trauma. 1992;6(1):10-3.
9. Bhandari M et al. **Compression plating versus intramedullary nailing of humeral shaft fracture –A meta analysis.** Acta Orthop 2006;7(2):279-84.
10. Volkv MV, Lyuboshitz NA. **Traumatology and Orthopaedics in the USSR,** Moscow MIR Publishers 1988;14-19.
11. Sarmiento A, Kinman PB, Galvin EG, et al. **Functional bracing of fractures of the shaft of the humerus.** J Bone Joint Surg Am 1977;59:596–601.
12. Chapman JR, Henley MB, Agel J, et al. **Randomized prospective study of humeral shaft fracture fixation: intramedullary nails versus plates.** J Orthop Trauma 2000;14:162–6.
13. Hsu TL, Chiu FY, Chen CM, Chen TH. **Treatment of Nonunion of Humeral Shaft Fracture with Dynamic Compression Plate and Cancellous Bone Graft.** J Chin Med Assoc 2005;68(2):73–76.
14. Mirdad TM. **Neuro-vascular injuries associated with limb fractures.** East African Medical Journal 2000; 77(12):663-666.
15. Reyes-Saravia GA. **Complications of surgical treatment of humeral shaft fractures managed with a UHN pin: comparison of antegrade versus retrograde insertion.** Acta Ortopédica Mexicana 2005; 19(1):22-27.
16. Akram R, Ahmad N, Aziz A. **Outcome of intramedullary interlocking Nail in diaphysal fracture of humerus.** J Pak Ortho Asso 2008;20(1):11-19.
17. Tsai CH, Fong YC, Chen YH, Hsu CJ, Chang CH, Hsu HC. **The epidemiology of traumatic humeral shaftfractures in Taiwan.** International Orthopaedics (SICOT) 2009; 33:463–467.
18. Gadegone WG, Salphale Y. **Nailing for fractures of humeral shaft- an analysis of 200 cases with an average follow up of 1 year.** Indian J of Orthopedics 2006;40(3):180-182.
19. Memon FA, Saeed G, Fazal B, Bhutto I, Laghari M, Siddique KA, Shaikh AR. **Complications of fracture treatment by traditional Bone setters at Hyderabad.** J Pak Ortho Asso 2009;21(2):58-64.
20. Putti AB, Uppin RB, Putti BB. **Locked intramedullary nailing versus dynamic compression plating for humeral shaft fractures.** Journal of Orthopaedic Surgery 2009;17(2):139-41.
21. Sitati FC, Kingori J. **Outcome of Management of Humerus Diaphysis Non-union.** East and Central African Journal of Surgery 2009;14(2):13-17.
22. O'Donnell TMP, McKenna JV, Kenny P, Keogh P, O'Flanagan SJ. **Concomitant injuries to the ipsilateral**

- shoulder in patients with a fracture of the diaphysis of the humerus.** Br J Bone and Joint Surgery 2008; 90(1): 61-65.
23. Bell MJ, Beauchamp CG, Kellam JK, McMurtry RY. **The results of plating humeral shaft fractures in patients with multiple injuries. The sunny brook experience.** Br . Edi Society Bone Joint Surgery 1985.
24. Ruedi T, Moshfegh A, Pfeiffer KM, Allgower M. **Fresh fractures of the shaft of the humerus—conservative or operative treatment?** Reconstr Surg Traumatol 1974;14:65–74.
25. Dabezies EJ, Banta CJ 2nd, Murphy CP, d'Ambrosia RD. **Plate fixation of the humeral shaft for acute fractures, with and without radial nerve injuries.** J Orthop Trauma 1992;6:10–3.
26. Heim D, Herkert F, Hess P, Regazzoni P. **Surgical treatment of humeral shaft fractures—the Basel experience.** J Trauma 1993;35:226–32.
27. Rommens PM, Verbruggen J, Broos PL. **Retrograde locked nailing of humeral shaft fractures. A review of 39 patients.** J Bone Joint Surg Br 1995;77:84–9.
28. McCormack RG, Brien D, Buckley RE, McKee MD, Powell J, Schemitsch EH. **Fixation of fractures of the shaft of the humerus by dynamic compression plate or intramedullary nail. A prospective, randomised trial.** J Bone Joint Surg Br 2000;82:336–9.
29. Changulani M, Jain UK, Keswani T. **Comparison of the use of the humerus intramedullary nail and dynamic compression plate for the management of diaphyseal fractures of the humerus.** A randomised controlled study. Int Orthop 2007;31:391–5.
30. Hems TE, Bhullar TP . **Interlocking nailing of humeral shaft fractures. The Oxford experience.** 1991–1994. Injury 1996;27:485–489.
31. Ikpeme JO . **Inramedullary interlocked nailing for humeral fractures: experience with Russel-Taylor humeral nail.** Injury 1994; 25:447–455.
32. Ingman AM, Waters DA. **Locked intramedullary nailing of humeral shaft fractures.** JBJS 1994; 76:23–24.
33. Lin J, Shen PW, Hou SM. **Complications of locked nailing in humeral shaft fractures.** J Trauma 2003;54(5):943–949.
34. Changulani M, Jain UK, Keswani T. **Comparison of the use of the humerus intramedullary nail and dynamic compression plate for the management of diaphyseal fractures of the humerus. A randomized controlled study.** International Orthopaedics (SICOT) 2007; 31:391–395.

AUTHOR(S):**1. DR. IMRAN KHAN**

M.S (Orthopaedics)
 Consultant Orthopaedics
 Department of Orthopaedics Unit-I
 Liaquat University of Medical & Health Sciences Jamshoro

2. PROF. DR. MUHAMMAD AYUB LAGHARI

Consultant Orthopaedics
 Department of Orthopaedics Unit-I
 Liaquat University of Medical & Health Sciences Jamshoro

3. DR. SHAKEEL AHMED MEMON

M.S (Orthopaedics)
 Consultant Orthopaedics
 Department of Orthopaedics Unit-I
 Liaquat University of Medical & Health Sciences Jamshoro

4. Dr. Muhammad Khan Pahore

Assistant Professor
 Department of Orthopaedics Unit-I
 Liaquat University of Medical & Health Sciences Jamshoro

Correspondence Address:**Dr. Imran Khan**

M.S (Orthopaedics)
 Consultant Orthopaedics
 House No. A/53, 3rd Street Faraz Villas
 Phase III, Wadhu Wah Road,
 Qasimabad, Hyderabad.
 drikmaher@hotmail.com

Article received on: 13/03/2013
 Accepted for Publication: 13/07/2013
 Received after proof reading: 03/12/2013