



## ILIZAROV TECHNIQUES; TO STUDY THE RESULTS OF INFECTED NONUNION OF TIBIA

1. MS Orthopaedic Surgery  
Senior Medical Officer  
Shaheed Mohtrama Benazir Bhutto  
Medical College Lyari/ Sindh  
Government, Lyari General &  
Teaching Hospital, Karachi  
Lyari General Hospital, Karachi
2. MS Orthopaedic Surgery  
Assistant Professor
3. FCPS Orthopaedic Surgery  
Senior Registrar
4. FCPS Orthopaedic Surgery  
Professor & Head of Department
5. FCPS Orthopaedic Surgery  
Assistant Professor Orthopaedic  
Surgery  
DIMC/DUHS
6. Postgraduate trainee  
Orthopaedic Department

**Correspondence Address:**  
Dr. Muhammad Bux Chachar  
FCPS Orthopaedic Surgery  
Department of Orthopaedic surgery  
Sindh Government Lyari General  
and teaching hospital/  
SMBB Medical College Lyari,  
Karachi.  
muhammad\_113@hotmail.com

**Article received on:**  
29/12/2015

**Accepted for publication:**  
10/04/2016

**Received after proof reading:**  
26/05/2016

### INTRODUCTION

The high incidence of automobile and motor cycle accident has made the open tibial fractures a common injury. Infection of the tibia following open fracture or surgical treatment remains the most severe complication especially when associated with nonunion.<sup>1</sup>

Infected nonunion and gap nonunion are the challenges for Orthopaedic surgeons globally. Many procedures have been tried to treat this particular problem including radical debridement, flaps, bone grafting etc. None are satisfactory and the morbidity is high during treatment.<sup>2,3</sup> Debridement and sequestrectomy results in large gaps which are difficult to treat with conventional methods. Internal fixation with dynamic compression plate or interlocking nail is impossible due to gap at nonunion site,

**Dr. Mohammad Haroon Chohan<sup>1</sup>, Dr. Krishan Lal<sup>2</sup>, Dr. Muhammad Bux Chachar<sup>3</sup>, Dr. M Akhter Baig<sup>4</sup>, Dr. Sunil Kumar<sup>5</sup>, Dr. Jamil Ahmed Khoso<sup>6</sup>**

**ABSTRACT... Objectives:** 1. To assess the results of infected nonunion of tibia by Ilizarov techniques. 2. To ascertain the incidence of complications and advise methods to prevent them. 3. To determine various risk factors which contribute to these complications. **Study Design:** This descriptive case series. **Setting:** Department of Orthopaedic Surgery, Dow University of Health Sciences/ Civil Hospital Karachi. **Period:** 1<sup>st</sup> March 2010 to 28<sup>th</sup> Feb. 2013. **Methods:** A total of 30 patients with infected nonunion of tibia with or without shortening and bone loss was included in the study. Patients lying in supine position, after spinal anesthesia, radical debridement were done and all previous infected implants and necrotic bone removed, pre-assembled ilizarov frame was applied with the help of four or five rings, each ring was fixed with k-wires and schanz pins. Olive wires were used where interfragmentary compression, correction of axial deviation of fragment, in osteoporotic bones, transport of fibular fragment or more stability was required. **Results:** Results were divided into bony and functional parts by ASAMI. We achieve excellent to good bony result in 86.66% (26/30) of cases and excellent to good functional result in 76.66% (23/30) of cases. **Conclusion:** It is concluded that bony and functional outcome of infected nonunion of tibia treated with ilizarov ring fixator is satisfactory. Although its application is lengthy but once applied patients get benefits, they can start walking with full weight bearing, limb length equality and soft tissue coverage achieved, so we recommend its applications in such type of cases.

**Key words:** Infected nonunion, Tibia, Ilizarov Technique

**Article Citation:** Chohan MH, Lal K, Chachar MB, Baig MA, Kumar S, Khoso JA. Ilizarov techniques; to study the results of infected nonunion of tibia. Professional Med J 2016;23(6):709-714. DOI: 10.17957/TPMJ/16.3225

defective quality of bone, and above all presence of infection. In these conditions external fixator is the treatment of choice especially Ilizarov ring fixator.<sup>4,5</sup> With this apparatus intercalary bone transport is possible along with soft tissue transport, resulting in elimination of gap, soft tissue cover without any leg length discrepancy. Weight bearing during treatment with Ilizarov ring fixator is definitely an advantage which improves not only quality of bone but also improves quality of life.<sup>6</sup>

The methods of Ilizarov offers unique, comprehensive solutions to the problems associated with treating a large infected bone segment. Using the established techniques of stable external fixation, atraumatic corticotomy and appropriate delay before distraction, large skeletal defect can be spanned. This

reconstructive ability permits radical segmental debridement of infected region.<sup>7</sup>

Ilizarov ring Fixator gives us an option of compression, distraction and bone transport and it has proved its efficacy in treatment of infected nonunion of tibia where other types of treatment had failed.<sup>8</sup> Joint function and weight bearing while on treatment is an advantage which cannot be matched by another technique.

Ilizarov often said "Infection burns in the fire of the regenerate" this concept is important in the treatment of infection.<sup>9</sup>

According to Ilizarov, to eliminate infection and obtain union, vascularity must be increased. In his approach this is achieved by corticotomy and the application of his circular external fixator.<sup>10</sup>

The patient who has an infected tibial defect or nonunion including those that are so severe that an amputation might be considered Ilizarov method of treatment is a valid option for salvage of the limb.<sup>11</sup>

We at civil hospital Karachi have been using this technique since early 1993, in the treatment of fractures, nonunions, congenital and post-polio residual deformities. Other investigators have reported it to be a successful method, so we undertook this study.

The purpose of this study is to assess the results of Ilizarov ring fixator in treating the infected nonunion of tibia,

## METHODS

This descriptive case series was carried out in the department of Orthopaedic surgery, Dow University of Health Sciences/ Civil Hospital Karachi from 1<sup>st</sup> March 2010 to 28<sup>th</sup> Feb. 2013. A total of 30 patients with infected nonunion of tibia with or without shortening and bone loss was included in the study.

Following variety of patients were included in this study.

1. Infected nonunion with inoperable skin and

uncontrolled infection.

2. Persisting infection with loosening of metal.
3. Nonunion with segmental bone loss.

Patients with damage of the tibial nerve, mental disease, including Senile dementia and anticipated poorly co-operative were excluded.

All patients were informed about possible complications, expected results, the prolonged treatment, during which the fixator would be in place and was prepared psychologically to accept it.

Wound condition or discharging sinuses, type of discharge was also examined and pus sent for culture and sensitivity.

Orthoroentgenograms were taken to exclude any deformity of limb segment with the help of specially illuminated table top. Through the line diagrams, the position of rings and site of corticotomy for bone transport, for correction of deformity, placement of special hinges and distraction rods where indicated was planned. All the above data was noted in specially drafted proforma.

Under spinal anaesthesia and supine position, we use pre-assembled Ilizarov frame in all 30 patients because it saves 45-60 minutes of operating time. Routinely four and five ring fixator was constructed for group A and B (Paley's classification) respectively. Olive wires were used where interfragmentary compression, correction of axial deviation of fragment, in osteoporotic bones, transport of fibular fragment or more stability was required.

The corticotomy was performed in most of the patient with the help of 5 mm osteotome but in some cases we performed percutaneous gigli saw osteotomy.

Bony distractions were started after a latency period ranging from 5-12 days at a rate of 0.25 mm 4 times a day in equal increments Antibiotics were given according to culture and sensitivity. Physical therapy was started on first postoperative

day and encouraged to bear weight. Passive and active stretching knee and ankle muscle were continued to prevent the development of contractures. Special measures were taken for correct positioning of the limb both during day and night time.

If during distraction patient felt acute pain, the distraction was slowed down to 0.25 mm every 12 hourly or was stopped for one or two days. The fixator was not removed until union was achieved or the regenerate had formed complete cortex on three sides (as visible on AP and lateral views of radiological examination).

The final phase of ossification was stimulated by dynamization of the frame. Once the fixator was removed the wire sites were dressed with sterilized gauze pieces and P.O.P back slab was given for one to two weeks. The patients were not allowed full normal activity till the regenerate has formed cortex on all 4 sides with new marrow canal in multiple x-ray view. All these patients were divided in two groups according to Paley's classification.

## RESULTS

A total of 30 patients with infected nonunion of tibial shaft were included in this study. There were 24 males (80 %) and 6 (20 %) females and age ranged from 18-58 years, lower 1/3<sup>rd</sup> tibia was involved in 18 (60%), middle 1/3<sup>rd</sup> in 7 (23.33%) cases and 5 (16.67 %) cases proximal 1/3<sup>rd</sup> tibia

was involved. Right side was predominantly involved in 18 (60%) of cases.

Apart from the primary procedure some secondary procedure were also required during their follow up. The most common secondary procedures were, readjustment of ring fixator 5 (16.66%) cases, repetition of corticotomy in 1 (3.33 %) case and bone grafting was done 5 times in 4 (13.33%) cases.

The results were divided into bone results and functional results according to the criteria laid down by A.S.A.M.I. According to this criteria I) bone results, were excellent in 20 patients (66.66%), good in 6 patients (20%) and poor in 4 patients (13.33%). Poor graded 3 patients after getting union achieved good bony results. II) Functional results, were excellent in 11 (36.66%) cases, good in 12 (40%) fair in 4 (13.33%) and poor in 3 (10%).

## DISCUSSION

It is often difficult to achieve union and eradicate an infection at the same site. A diagnosis of nonunion can be made when at least six months have elapsed after the time of the fracture and when there is evidence that the fracture will not unite. An infection at that point tends to be chronic, because it is associated with an organism that is resistant to most antibiotics<sup>12,13</sup> and because many patients who have an infection at the site of a non-union have additional scarring after

### Bony Results

	Group A	Group B1	Group B2	Group B3	Total No. of Patients %
Excellent	13	3	3	1	20 - 66.66
Good	2	2	2	Nil	6 - 20
Fair	Nil	Nil	Nil	Nil	0 - 0
Poor	1	1	1	1	4 - 13.33
Total	16	6	6	2	30 - 100%

### Functional Results

	Group A	Group B1	Group B2	Group B3	Total No. of Patients %
Excellent	6	2	2	1	11 - 36.66
Good	7	2	3	Nil	12 - 40
Fair	2	1	1	Nil	4 - 13.33
Poor	1	1	Nil	1	3 - 10
Total	16	6	6	2	30 - 100

unsuccessful operative attempts to eradicate the infection or treat the nonunion. The infection is more likely to be eradicated if all of the necrotic bone is resected completely. However, such extensive resection makes the bridging of the bone ends more difficult to achieve. Furthermore, a nonunion that is associated with an infection is almost always also associated with deformity, leg length discrepancy, joint stiffness, disuse osteoporosis and soft tissue atrophy. Sometimes there is neurovascular damage as well. Distraction osteogenesis is done in an attempt to address all of these problems simultaneously.

In this study 30 cases with infected nonunion of tibia were evaluated. The mean time for union (between the application of fixator and radiologic and clinical union) was 8.23 months. In a study performed by Tranquilli et al in Italy on 20 patients with nonunion of tibia the mean time of union was 4.5 months and the result was always union.<sup>14</sup> M.N. Tahmasebi et al in his study in Iran on 14 patients of infected nonunion of tibia out of whom 2 were associated with tibial bone defects, the mean time of union was 8 months in tibial infected non-union and 12 months in cases with bone defects.<sup>15</sup>

Our success in the eradication of chronic infection, with no recurrences after a median follow-up of 9.27 months, is very impressive. We believe that this was because we were able to apply the basic surgical principle of the treatment of infection by the excision of all unhealthy tissue. This was achieved by local debridement and removal of infected metalwork in 5 of the 30 infections.

Consolidation of the nonunion in our patients was generally satisfactory but was not as successful as the eradication of infection. In three patients, it became apparent, at six months, that union was unlikely, and one patient had a re-fracture. However, the three patients who had delayed union had bone grafting. Two Patients had united after bone graft but unfortunately one's bone graft site get infected and this patient was re-grafted after the six months when infection settled, and still awaiting for union. Green<sup>16</sup> noted delayed

union at the point where the intercalary fragment docks with the target fragment. For this reason, he found it necessary to pack a small cancellous bone graft around the docking site in six of his fourteen patients who had a bone defect. Ilizarov, who experienced the same difficulty, freshen the bone ends with a curette and osteotome when the intercalary segment was about one centimeter from contact with the target segment.<sup>17</sup>

We had 57 superficial and 10 deep pin tract infections [67/694 Pins (9.6%)] and 1 pin rupture in 30 patients. Staphylococcus aureus was reported to be the most commonly isolated organism. Polyzois et al reported 38 Pins infected out of 442 Pins (9%).<sup>18</sup> Marsh, in series of 56 consecutive patients treated with the Ilizarov circular fixator, reported a total of 138 episodes of pin tract infection in 49 patients.<sup>19</sup> In our series higher pin tract infection is due to poor educational status and insufficient pin care of most of the patients.

No direct neurovascular injury occurred preoperatively. In 1 patient transient neuropraxia occurred during distraction phase, which was relieved by decreasing the rate for a few days. This was most probably due to indirect stretching of nerves because of too rapid distraction rate for that patient. Transient knee and ankle stiffness was occurred in 5 patients which improved by vigorous physiotherapy either during the fixator phase or after the removal of fixator.

Among the bone results, we had excellent and good results in 26 patients (86.66 %), and 4 (13.33%) had poor results ,out of which one has refracture due to fall which was later applied bone graft and cast because patient refused for reapplication of Ilizarov ring fixator.

As for as the functional results were concerned, we were able to achieve excellent and good results in 23 (76.66 %) of our patients, fair results in 4 (13.33 %) cases and 3 (10 %) in poor results

## CONCLUSION

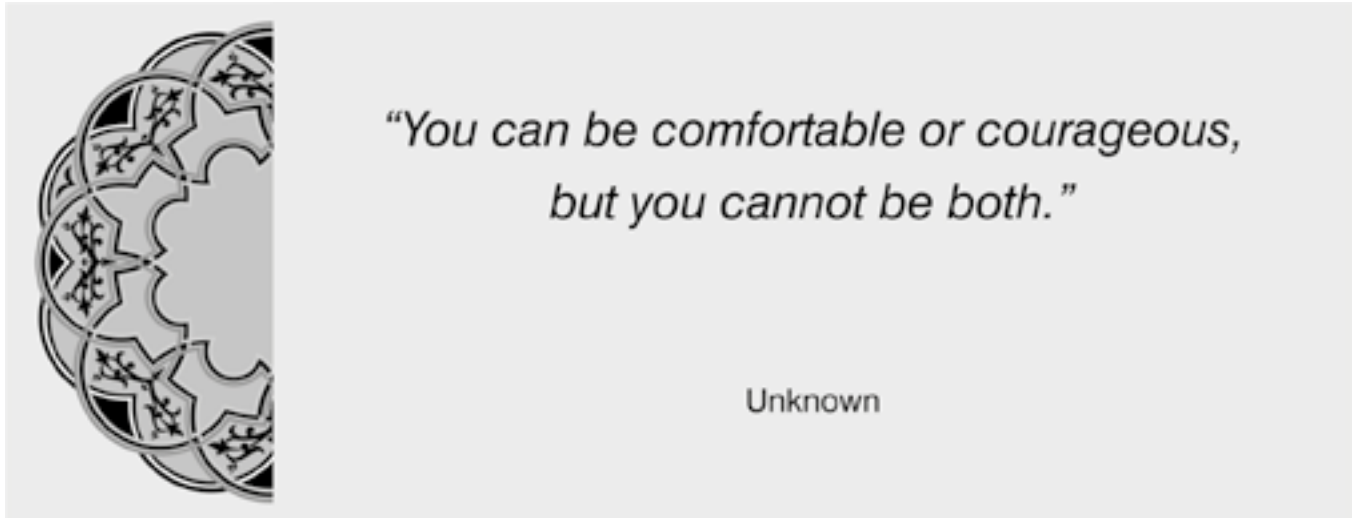
It is concluded that bony and functional outcome of infected nonunion of tibia treated with ilizarov

ring fixator is satisfactory. By the help of this method limb can be salvaged. Although its application is lengthy but once applied patients get benefits, they can start walking with full weight bearing, limb length equality and soft tissue coverage achieved, so we recommend its applications in such type of cases.

Copyright© 10 Apr, 2016.

## REFERENCES

1. Harry B. Skinner, Edward Diao, Richard Gosselin & David W. Lowenberg **“Musculoskeletal Trauma Surgery”** Current Diagnosis & Treatment in Orthopaedics Second Edition 2000, P.105.
2. Dinesh-Shankar AN, Anoop A. **Short term follow up and results of gap nonunion tibia (including infected) with Ilizarov technique.** J Orthop 2004; 1(1): 5.
3. Paley FB, Christianson D. **A Biomechanical analysis of Ilizarov and external fixators.** Clin Orthop Rel Res 1989; 241: 195.
4. Ilizarov GA, Lediaev VI, Degtiarev VE. **Operative and bloodless methods of repairing defects of the long tubular bones in osteomyelitis.** [In Russian] Vestn Khir Im I I Grek 1973; 110: 55-9.
5. Ilizarov GA, Lediaev VI. **Replacement of defects of long tubular bones by means of one of their fragments [in Russian].** Vestn Khir Im I I Grek 1969; 102: 77-84.
6. Nicoll, E.A: **closed and open management of tibial fractures.** Clin. Orthop, 105: 144 - 153, 1974.
7. Vincent D. Pellegrini, Jr., J. Spence Reid, C. **Mc Collister Evarts “Complication” Rockwood & Green’s Fracture in Adults,** Vol: 1- 1996, P. 475.
8. M.N. Tahmasebi and Sh. Jalali Mazlouman **“Ilizarov method in treatment of tibial and femoral infected nonunions in patients with high energy trauma and battle field wounds”.** Acta Medica Iranica Vol. 42, No5 2004, P. 348.
9. M.A.Catagni, **Nonunions of the tibia – Principles of treatment “Treatment of fractures, Nonunions & Bone loss of the tibia with the Ilizarov method”**, P 94 –98, 1998.
10. David G. Lavelle **“Delayed union and non-union of fractures of long bones”** Campbell’s operative orthopedic vol: 3, 10<sup>th</sup> edition P:3136, 2003.
11. Gordon L, Chiu E J. **“Treatment of infected Nonunions & segmental defects of the tibia with staged microvascular muscle transplantation and bone grafting”.** JBJS (A) 1988 Mar 70 (3), 377–86.
12. Ilizarov G.A; **Transosseous osteosynthesis.** Heidelberg springer verleg 1991. PP 495 – 96.
13. Vladimir Schwartsman, Sang H. choi and roman schwartsman. **Tibial Nonunions, Treatment tactics with the Ilizarov method.** The Orthopedic clinics of North America 1990; 21(4): P.651-652.
14. Paley, D., Catagni, M., Argnani, F., Villa, A., Benedetti, G. B., and Cattaneo, R. **(1989) Ilizarov treatment of tibial non-unions with bone loss.** Clin. Orthop. 241, 146–165.
15. Gristina, A. G.; Naylor, P. T.; and Myrvik, Q. N.: **Mechanisms of musculoskeletal sepsis.** Orthop. Clin. North America, 22: 363-371, 1991.
16. Towers, A. G.: **Wound infection in an orthopaedic hospital.** Lancet, 2: 379-381. 1965.
17. Tranquilli Leali P, Merolli A, Perrone V, Caruso L, Giannotta L. **The effectiveness of the circular external fixator in the treatment of post-traumatic of the tibia nonunion.** Chir Organi Mov. 2000 Jul-Sep; 85 (3):235-242.
18. M.N. Tahmasebi and Sh. Jalali Mazlouman **“Ilizarov method in treatment of tibial and femoral infected nonunions in patients with high energy trauma and battle field wounds”.** Acta Medica Iranica Vol. 42, No5 2004, P. 344-345.
19. Green, S. A.: **Osteomyelitis. The Ilizarov perspective.** Orthop. Clin, North America, 22: 515-521, 1991.



### AUTHORSHIP AND CONTRIBUTION DECLARATION

Sr. #	Author-s Full Name	Contribution to the paper	Author=s Signature
1	Dr. M. Haroon Chohan	Manuscript writing, Data Collecting	
2	Dr. Krishan Lal	Reference Collection	
3	Dr. Muhammad Bux Chachar	SPSS Analysis	
4	Dr. M Akhter Baig	Manuscript and data formulating	
5	Dr. Sunil Kumar	Reference and Data collection	
6	Dr. Jamil Ahmed Khoso	Reference collection	