



POLYORCHIDISM; AN UNUSUAL SCROTAL LUMP

1. MBBS, MCPS, FCPS
Consultant Radiologist
Head of Radiology Dept
Fauji Foundation Hospital
Lahore Cantt.
2. MBBS, DMRD
Radiologist
Fauji Foundation Hospital
Lahore Cantt.
3. MBBS
House Officer
CMH Lahore Cantt.
4. Medical Student
KEMU Lahore.

Correspondence Address:
Lt Col Muhammad Arshad, Retd,
Dept of Diagnostic Radiology
Fauji Foundation Hospital,
Bedian Road, Lahore Cantt.
arshad746@gmail.com

Article received on:
14/11/2017
Accepted for publication:
25/03/2018
Received after proof reading:
00/00/2018

Muhammad Arshad¹, Muhammad Arshad Manzoor², Zimar Arshad³, Talia Arshad⁴

ABSTRACT... Polyorchidism is a very rare anomaly that is defined by the presence of more than two testes. Knowledge about the condition and accurate imaging diagnosis and characterization is important to decide the optimal line of management and avoid unnecessary surgery. A 14-year-old male reported for Scrotal Color Doppler Ultrasound with complaint of a painless mass in the left scrotum with no history of trauma. On physical examination, there were two palpable, ovoid, mobile, non-tender masses in the left hemiscrotum. Scrotal Color Doppler Ultrasonography (USG) revealed a well circumscribed supernumerary testicle in the left scrotum adjacent to superior pole of left testis with parenchymal echogenicity and doppler vascularity like that of normal testis parenchyma. In conclusion, diagnosis was polyorchidism with duplication of the left testicle. The patient was advised follow-up after one-year. USG is the modality of choice to assist in the diagnosis.

Key words: Color Doppler Ultrasound, Magnetic Resonance Imaging, Polyorchidism.

Article Citation: Arshad M, Manzoor MA, Arshad Z, Arshad T. Polyorchidism; polyorchidism-an unusual scrotal lump. Professional Med J 2018; 25(9):1447-1449.
DOI:10.29309/TPMJ/18.4510

INTRODUCTION

Polyorchidism or supernumerary testicles are defined by the presence of more than two testicles and is an extremely rare congenital anomaly.^{1,2} Only about 200 cases have been reported in the literature so far.³

CASE REPORT

A 14-year- unmarried boy reported to our radiology clinic for Scrotal Color Doppler USG with a complaint of a palpable, painless mass in the left scrotum for at least three years, with no history of trauma. There was no other remarkable genitourological history. The urological physical examination was unremarkable, except for the ovoid non-tender mass. The tests including the serum levels of alpha-Fetoprotein, B-human Chorionic Gonadotropin, Follicle Stimulating Hormone, Luteinizing Hormone and Testosterone were within normal range. Semen analysis showed no abnormality.

Scrotal Color Doppler USG revealed a well circumscribed accessory tissue in the left scrotum adjacent to superior pole of left testis, measuring

18.5 x 16.9 x 12.2 mm (Figure-1). The parenchymal echogenicity and doppler vascular flow pattern of that lesion was like that of normal testis parenchyma (Figure-2). Epididymis was detected along the superior aspect of supernumerary testicle in left scrotal sac. There was no focal abnormal echogenicity suggesting malignancy. Concomitant small hydrocele was also noted in left scrotal sac. No additional findings such as hernia or lymphadenopathy was visualized. In conclusion, diagnosis was polyorchidism with duplication of the left testicle.

The patient was advised follow-up after one-year.

DISCUSSION

Polyorchidism was first described by Blasisus in 1670 in an autopsy while Lane was the one who performed the first histological description of a supernumerary testis in 1895.⁴

The possible etiologic mechanism is a defect of genital ridge before 8 weeks of fetal development, such as a longitudinal or transverse division or duplication of genital ridge with or without the

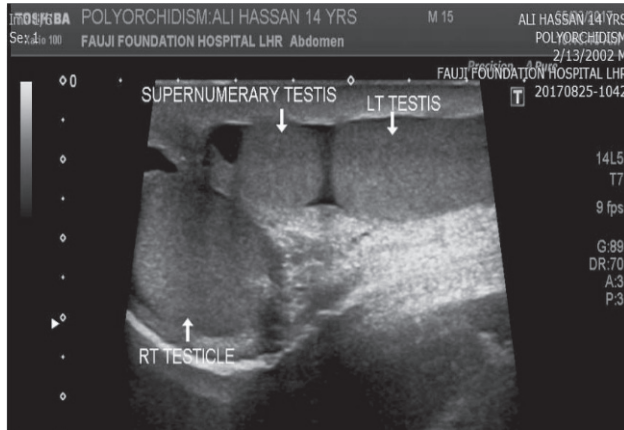
Wolffian duct division.⁵

Figure-1. 14- years-old boy with polyorchidism. Ultrasound showing a side view of Type A3 polyorchidism, showing right testicle, two testicles in left scrotal sac with epididymal head superior to supernumerary testis.

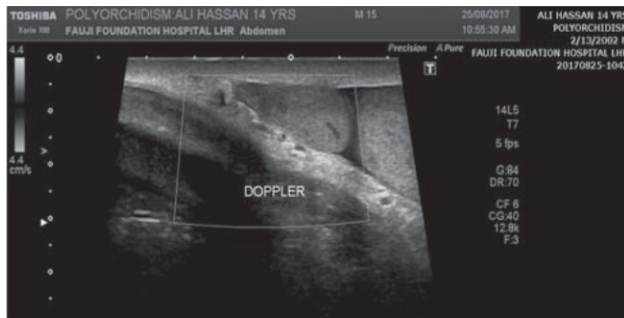


Figure-2. 14-year-old boy with polyorchidism. Left Scrotal Color Doppler ultrasonography image of an extra left testis shows similar vascularity pattern with normal testis parenchyma.

Polyorchidism occurs in two primary forms: Type A and Type B.⁶

Type A: The supernumerary testicle is connected to a vas deferens. These testicles are usually reproductively functional. Type A is further subdivided into:

- Type A1: Complete duplication of the testicle, epididymis and vas deferens.
- Type A2: The supernumerary testicle has its own epididymis and shares a vas deferens.
- Type A3: The supernumerary testicle shares the epididymis and the vas deferens of the other testicles.

Type B: The supernumerary testicle is not connected to a vas deferens and is therefore not reproductively functional. Type B is further subdivided into:

- Type B1: The supernumerary testicle has its own epididymis but is not connected to a vas deferens.
- Type B2: The supernumerary testicle consists only of testicular tissue.

Type A3 is the most common form of polyorchidism, and types A2 and A3 together account for more than 90% of cases. In 65% of cases, the supernumerary testicle is found in the left scrotal sac.

Its most common presentation is triorchidism² but cases such as four testicles (four cases) and five testicles (one case) were also defined in the literature.⁷ Approximately 50% of the cases are detected between 15 and 25 years of age.³ Most patients are asymptomatic or present with painless inguinal or scrotal masses, undescended testis, and rarely, torsion of the supernumerary testis.⁷

Color Doppler USG is a quick, noninvasive, cheap and easily available method to evaluate the mass pathologies. In our case, the Color Doppler USG revealed the parenchymal echogenicity and vascular flow like that of normal testicle. MRI may provide confirmation when the results of sonography are inconclusive. The supernumerary testicle has the same MRI features as a normal testicle: intermediate signal intensity on T1-weighted images and high signal intensity on T2-weighted images.⁸ There is much controversy about the necessity of MRI in polyorchidism. Some papers report that MRI is not required in the absence of suspicion such as intra-abdominal polyorchidism or malignancy.^{8,9} In the meta-analysis of Bergholz, USG was the most common radiological modality and only a few of polyorchidism lesions underwent MRI. In those lesions, MRI did not give any additional information to USG.³

Spermatogenesis in the supernumerary testicle is normal in about 50% of cases. Hormone determination of β -hCG, AFP and LDH could be requested in case of doubt of testicular cancer. The differential diagnosis of polyorchidism includes an extra-testicular or para-testicular mass, such as scrotal hernia, bilobed testicle,

crossed testicular ectopia, testicular tumor, hydroceles and varicoceles.

Since the improvement in imaging techniques, most reports propose a close follow-up and decline an early invasive management.¹⁰ Our patient did not have scrotal pain and has been instructed follow-up every year.

CONCLUSION




Polyorchidism is a very rare anomaly. Color Doppler USG is the preferred method for evaluation, diagnosis and follow-up. MRI might not present additional information to Color Doppler USG, if there is no complication or suspicion of malignancy, torsion, hernia or cryptorchidism.

Copyright© 25 Mar, 2018.

REFERENCES

1. Aykan S, Temiz MZ, Tuken M, Yuruk E. **Polyorchidism presenting with testicular pain and scrotal mass.** J Clinic Res Bioeth 2014; 6: 214.
2. Jakhere SG, Saifi SA, Ranwaka AA. **Supernumerary testis: Imaging appearance of a rare entity.** Indian J Urol 2014; 30: 233-4.
3. Bergholz, R.; Wenke, K. **Polyorchidism: A Meta-Analysis.** The Journal of Urology 2009; 182 (5): 2422-2427.
4. Olano Grasa I, Llarena Ibarguren R, García-Olaverrí Rodríguez J, Azurmendi Arin I, Cantón Aller E, Pertusa Peña C. **Polyorchidism.** Arch Esp Urol. 2009; 62: 59-62.
5. Serdar Aykan, Mustafa Zafer Temiz, Murat Tuken and Emrah Yuruk. **Polyorchidism presenting with testicular pain and scrotal mass.** J Clinic Res Bioeth 2015; 6: 2.
6. Alamsahebpour A, Hidas G, Kaplan A, McAleer I.M. **Bilateral polyorchidism with diffuse microlithiasis: a case report of an adolescent with 4 testes.** Urology. 2013; 82 (6): 1421-3.
7. Abdul Jabbar AH. **A case report: Triorchidism; is a rare mistaken cause for extra testicular neoplasm.** Urol Case Rep 2015; 3: 89-91.
8. *Kharrazi SM, Rahmani MR, Sakipour M, Khoob S. **Polyorchidism: A case report and review of literature.** Urol J. 2006; 3: 180-183.*
9. Repetto P, Ceccarelli P, Bianchini A, Durante V, Biondini D, Cacciari A. **Three small testes in left hemiscrotum: A rarer case of polyorchidism.** J Pediatr Surg. 2010; 45: 21-23.
10. Shahid Khan, George John, Jonathan L Richenberg. **An unusual scrotal lump.** J Pak Med Assoc. Apr 2005; 55(4):172-3.

AUTHORSHIP AND CONTRIBUTION DECLARATION

Sr. #	Author-s Full Name	Contribution to the paper	Author=s Signature
1	Muhammad Arshad	Cheif Author	
2	M. Arshad Manzoor	Verified the case findings	
3	Zimar Arshad	Review of literature, References & Formatting of article.	
4	Talia Arshad	Review of literature, References & Formatting of article.	