



ISONIAZID INDUCED LIVER DAMAGE; HEALTHY EFFECTS OF SILYMARIN ON LIVER HISTOPATHOLOGY AGAINST ISONIAZID INDUCED LIVER DAMAGE IN RABBITS

Sarwat Jahan¹, Sana Imran², Naveed Ahsan³

1. MBBS, M.Phil (Pharmacology)
Assistant Professor
Department of Pharmacology
United Medical and Dental College,
Karachi.
2. MBBS, M.Phil (Pharmacology)
Assistant Professor
Department of Pharmacology
Jinnah Sindh Medical University,
Karachi.
3. MBBS, M.Phil (Biochemistry)
Assistant Professor
Department of Biochemistry
United Medical and Dental College,
Karachi.

Correspondence Address:

Dr. Sarwat Jahan
Department of Pharmacology
United Medical and Dental College,
Karachi.
drsarwat78@hotmail.com

Article received on:

03/10/2017

Accepted for publication:

15/04/2018

Received after proof reading:

00/00/2018

ABSTRACT... Objectives: To observe healthy effects of silymarin on liver histopathology against liver damage, caused by isoniazid in rabbits. **Study Design:** Interventional study. **Setting:** Animal House of Jinnah Postgraduate Medical Centre, Karachi. **Period:** April to September 2013. **Methods:** Total 28 rabbits of weight 1-1.5kg of either sex were used in this study. Which were divided randomly into four equal groups: Group I was control group. In group II silymarin (50mg/kg/day orally) was administered, in group III isoniazid (50mg/kg/day orally) was given; and in group IV, effects of combination therapy of isoniazid and silymarin were observed. Before starting the drug therapy, at day 0 and one day after the end of study period i.e., at day 19, body weight of each animal was recorded. Rabbits were sacrificed on 19th day and the required liver sample was taken for histopathological examination. The data feeding and analysis at the end of study was done on computer package SPSS (Statistical packages of social science) version 16. **Results:** No mortality was recorded in any group. In group II (silymarin treated) animals in this group exhibited no any histological changes in the hepatic lobule except few inflammatory cells 28.5% were seen in the portal tract. The liver microscopic examination in group III (Isoniazid treated), animals showed the disturbed architecture of the lobule. There were no fatty changes, whereas ballooning degeneration was 42.9%, hepatocytes necrosis was 71% and portal inflammation was 71.4% which was very severe. Animals in group IV, given combination of silymarin and isoniazid showed the intact architecture of the hepatic lobule, in which 14.29% ballooning degeneration, whereas necrosis of hepatocytes and portal inflammation was mild in nature which may be due to hepatoprotective role of silymarin. **Conclusion:** Silymarin has hepatoprotective effects when given in combination with isoniazid.

Key words: INH-induced Hepatotoxicity, Drug Induced Liver Injury, Ballooning Degeneration, Necrosis, Portal Inflammation and Isoniazid.

Article Citation: Jahan S, Imran S, Ahsan N. Isoniazid induced liver damage; healthy effects of silymarin on liver histopathology against isoniazid induced liver damage in rabbits. Professional Med J 2018; 25(7):1124-1128.
DOI:10.29309/TPMJ/18.4377

INTRODUCTION

Liver is the first place where various types of oral therapeutic drugs and other xenobiotic come in contact from intestinal absorption and thus causing this organ more prone to chemical-induced injury.¹ Hepatotoxicity is one of the most important adverse drug reaction associated with anti tuberculous drugs that may limit their use. It may involve metabolism of drugs to toxic, reactive intermediates and covalent binding with cellular components, interference, with membrane transport or with cellular biochemistry such as protein synthesis, or immunological mechanisms.² One of the isoniazid metabolite named hydrazine cause hepatotoxicity. It is an important product of cytochrome P450

enzyme metabolizing activity which mainly causes oxidative stress.³ One pathway of oxidative stress is lipid peroxidation, as established in animal models treated with anti-tuberculosis drugs such as isoniazid or hydrazine.⁴ Further more hydrazine inhibits mitochondrial complex II and reduce the function of electron transport chain and ATP production in hepatocytes. In case of combination therapy of hydrazine and a complex I inhibitor, hepatocyte death can occur.⁵ According to recent studies, isoniazid bind to liver proteins and cause immune-mediated hepatotoxicity.^{6,7} Silymarin is a complex mixture of four flavonolignan isomers, namely silybin, isosilybin, silydianin and silychristin. The antioxidant property and cell regenerating functions due to increased protein

synthesis are main hepatoprotective action.⁸ In this study we observe healthy effects of silymarin on liver histopathology against liver damage, caused by isoniazid in rabbits.

MATERIAL AND METHODS

This study was conducted in the Department of Pharmacology and Therapeutics, BMSI, JPMC, Karachi in collaboration with Department of Pathology, Biochemistry and BMSI Animal House from April 2013 to September 2013. This animal study protocol was approved by JPMC's Ethical Committee. In this interventional study, 28 locally bred sexually mature *Oryctolagus cuniculus* rabbits of both sexes were taken. Their body weight was ranging from 1-1.5 kg. The animals were kept in the BMSI animal House. General examination was done to evaluate their general health condition. All the animals were kept on standard laboratory diet (containing wheat, floor, vitamin etc.) and water. The rabbits were given identification by labeling them with permanent marker on ear of each rabbit and housed in labeled stainless steel cages with holed steel top in well-ventilated room under the acceptable 12 hours day/night light-cycle of the animal house. The animals were kept a week for attaining acclimatization to the environment before starting the treatment.

These animals were divided randomly into four equal groups: Group I was control group without any drug; in group II, silymarin (50mg/kg/day orally) was given. In group III, Isoniazid (INH) (50mg/kg/day orally) was administered; and in group IV combination of isoniazid and silymarin were given. The animals were sacrificed on 19th day that is one day after the end of treatment period after recording their final weight. A midline incision extending from manubrium sterni to the lower abdomen was made with the help of a scalpel. The skin flaps and muscles of abdomen retracted by pair of sharp scissor and blunt forcep and liver was expose by incising the diaphragm. The liver was removed from abdomen by dissecting the omental bursa, blood vessels and ligaments attached to it. The required liver sample was taken for histopathological examination. All the sections were studied under light microscope

at low and high magnification and oil immersion objective. The architecture of the liver lobule and hepatocytes were studied.

Sample size was calculated according to the previous study¹⁵ as a reference by using computer program open Epi version 16. Data was analyzed using SPSS 16. In all statistical analysis, only $p < 0.05$ was considered significant.

RESULTS

Present study was aimed to observe healthy effects of silymarin on liver histopathology against liver damage, caused by isoniazid in rabbits. No mortality was recorded in any group. Animals of group-I (control group) showed normal histological appearance of hepatic lobules when seen under the light microscope (Table-I, Figure-1). In group II (silymarin treated) there was non-significant histopathological findings in this group when compared to control group except few inflammatory cells 28.5% (n=2) were seen in the portal tract as depicted in Table-I, Figur-2. The liver microscopic examination in group III (Isoniazid treated) animals showed the disturbed architecture of the lobule. The hepatic lobules showed degenerative changes and focal necrosis. There was no fatty changes 0% (n=0), whereas ballooning degeneration was 42.9% (n=3), hepatocytes necrosis was 71% (n=5) and portal inflammation was 71.4% (n=5), as depicted in Table-I and Figure-3. In Group IV (Silymarin + Isoniazid), combination of silymarin and isoniazid exhibited the intact architecture of the hepatic lobule. Other histological findings were 14.29% (n=1) ballooning degeneration, necrosis of hepatocytes and portal inflammation as depicted in Table-I and Figures-4 (A,B).

DISCUSSION

According to the recent data from the Drug-Induced Liver Injury Network (DILI), the occurrence of Isoniazid-induced liver injury is high in the United States and it is the second most frequent drug that causes liver injury.⁹ Hydrazine one of the important metabolite is responsible for hepatic necrosis, macrovesicular degeneration, and steatosis in mice and rabbits.¹⁰

Parameters	Group I (Control) (n=7)	Group II (Silymarin) (n=7)	Group III (Isoniazid) (n=7)	Group IV (Combination) (n=7)
Fatty changes	No	No	No	No
Ballooning degeneration	No	No	3/7(42.9%)	1/7(14.29%)
Necrosis	No	No	5/7(71.42%)	1/7(14.29%)
Portal inflammation	No	2/7(28.5%)	5/7(71.42%)	1/7(14.29%)

Table-I. Histopathological changes in liver tissue among different groups of rabbits

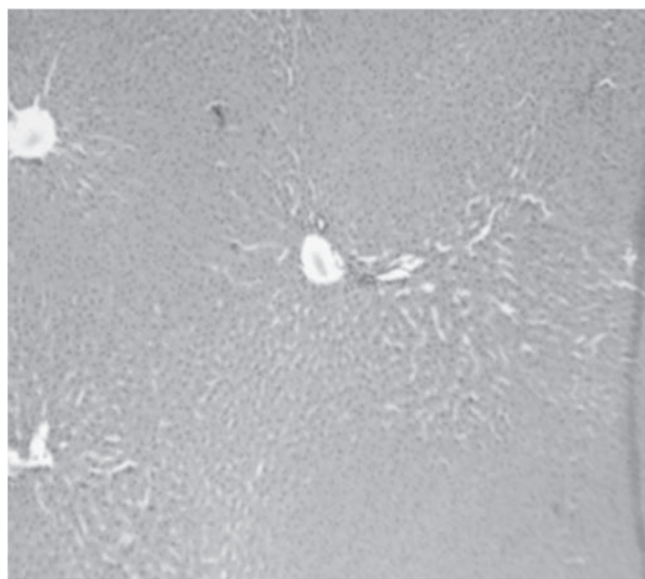


Figure-I. Control group 10x hepatic parenchyma showing normal portal tract with no balloon ingeneration

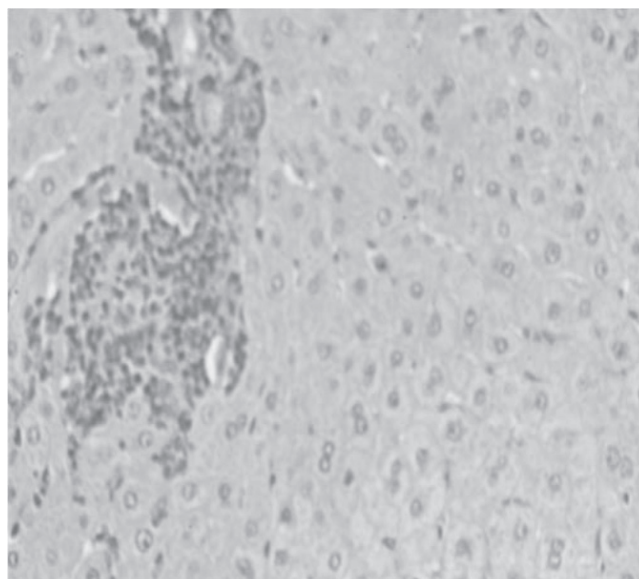


Figure-II. Effect of silymarin 10x hepatic parenchyma Showing near normal morphology with focal mild portal inflammatory infiltrate

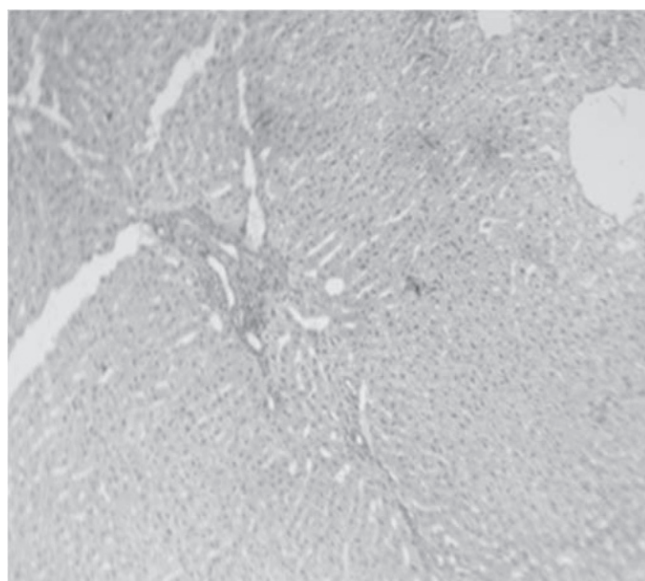


Figure-III. Effect of isoniazid 40x hepatic parenchyma showing portal inflammation and ballooning degeneration

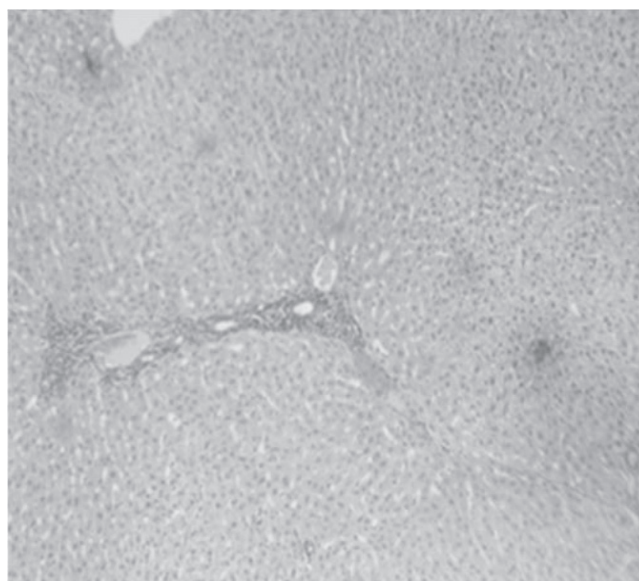


Figure-IV (A) Effect of combination of drugs 10x hepatic parenchyma showing mild portal inflammations

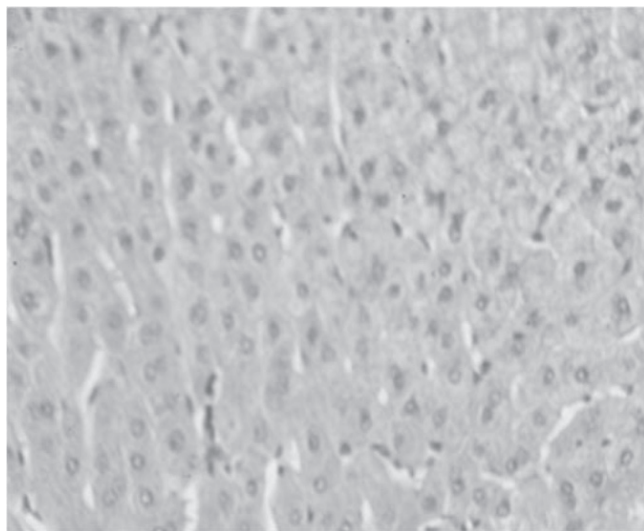


Figure-IV (B) Effect of combination of drugs 40x hepatic parenchyma showing focal necrosis

Isoniazid has an inhibiting effect on CYP1A2, 2A6, 2C19 and 3A4 activity, which is involved in hydrazine detoxification.¹¹ Isoniazid is also found to bind itself with liver proteins and cause immune-mediated hepatotoxicity.^{6,7} The use of natural herbs like silymarin may cause protective effects on the liver and thus can prevent from such adverse drug reactions due to their dual pharmacological properties including hepatoprotective and antioxidant activity.^{12,13} Silymarin has also been found to have immunomodulatory, anti-fibrotic, anti-proliferative, and antiviral properties.¹³

Animal studies have proven that isoniazid (INH) toxicity results in the induction of liver apoptosis with associated disruption of mitochondrial membrane potential and DNA strand breaks.¹⁴ In this study Isoniazid induced liver toxicity was manifested by changes in the liver histopathological architecture. Thus, we also used histological markers in study. Animals in group II (silymarin treated animals), showed minimal reversible changes in the hepatic lobule and only 28.5% (n=2) portal inflammation was observed.

When we compared this group with the control group, there was no significant difference observed in histopathological findings except few inflammatory cells in the portal tract. These effects of silymarin indicate the protective effects

on liver tissue. Group-III (isoniazid treated animals showed 42.9% (n=3) ballooning degeneration and 71.4% (n=5) portal inflammation and hepatic necrosis. According to the previous study¹⁵, isoniazid treated animals showed multifocal and centrilobular mononuclear cell infiltration in hepatocytes, the same histopathological findings observed in isoniazid treated group in this study. In group IV, combination of isoniazid and silymarin was administered, 14.3% (n=1) ballooning degeneration, necrosis and portal inflammation was observed. Our findings match with the results of previous studies^{15,16} who reported that the effect of combination therapy of isoniazid and silymarin results in decreased incidence and severity of liver histopathological changes.

CONCLUSION

Silymarin has healthy effects on liver, when given in combination with the drug causing hepatotoxicity like isoniazid. It prevents isoniazid induced liver damage which was proven by histopathological evidence.

Acknowledgements

We are grateful to the departments of Pharmacology, Biochemistry and Pathology and animal house BMSI, JPMC, Karachi, for providing manpower, laboratory facilities, high technological equipment and chemicals.

Copyright© 15 Apr, 2018.

REFERENCES

1. XinshengGu and Jose E. Manautou*. **Molecular mechanisms underlying chemical liver injury**. Expert Rev Mol Med. 2012 Feb 3; 14: e4.
2. Kshisagar A, Vetal Y, Ashoke P, Bhosle P, Ingawala D. **Drug Induced Hepatotoxicity**. Internet J Pharmacol 2008; 7:1-19.
3. Vuilleumier N., Rossier M.F., Chiappe A., Degoumois F., Dayer P., Mermillod B. **CYP2E1 genotype and isoniazid-induced hepatotoxicity in patients treated for latent tuberculosis**. Eur J ClinPharmacol. 2006; 62:423-429.
4. Rana SV, Pal R, Vaiphei K, Ola RP, Singh K. **Hepatoprotection by carotenoids in isoniazid-rifampicin induced hepatic injury in rats**. Biochem Cell Biol 2010; 88:819-34.

5. Lee K.K., Fujimoto K., Zhang C., Schwall C.T., Alder N.N., Pinkert C.A. **Isoniazid-induced cell death is precipitated by underlying mitochondrial complex I dysfunction in mouse hepatocytes.** Free Radic Biol Med. 2013; 65:584–594.
6. Metushi I.G., Nakagawa T., Uetrecht J. **Direct oxidation and covalent binding of isoniazid to rodent liver and human hepatic microsomes: Humans are more like mice than rats.** Chem Res Toxicol. 2012; 25:2567–2576.
7. Metushi I.G., Sanders C., Lee W.M., Uetrecht J. **Detection of anti-isoniazid and anti-cytochrome P450 antibodies in patients with isoniazid-induced liver failure.** Hepatology. 2014; 59:1084–1093.
8. Norris W, Paredes AH, Lewis JH. **Drug-induced liver injury in 2007.** Curr Opin Gastroenterol 2008; 24:287.
9. Hayashi PH, Fontana RJ, Chalasani NP, Stolz AA, Talwalkar JA, Navarro VJ, et al. **Under-reporting and poor adherence to monitoring guidelines for severe cases of isoniazid hepatotoxicity.** Clin Gastro- enterol Hepatol 2015; 13(1676-82).
10. Richards VE, Chau B, White MR, Mc Queen CA. **Hepatic gene expression and lipid homeostasis in C57BL/6 mice exposed to hydrazine or acetyl hydrazine.** Toxicol Sci 2004; 82:318–32.
11. Aashish Pandit, Tarun Sachdeva and Pallavi Bafna. **Drug-Induced Hepatotoxicity** Journal of Applied Pharmaceutical Science 02 (05); 2012: 233-243.
12. Zodape GV. **Effect of Aloe vera juice on the hepatotoxicity induced by isoniazid.** Drug Journal of Applied and Natural Science 2011; 3:238-241.
13. Vargas-Mendoza N et al. **Hepatoprotective effect of silymarin** World J Hepatol 2014 March 27; 6(3): 144-149.
14. Schwab CE and Tuschl H. **In vitro studies on the toxicity of isoniazid in different cell lines.** Hum Exp Toxicol 2003; 22:607-15.
15. Maryam S, Bhatti ASA, Shahzad AW. **Protective effects of silymarin in isoniazid induced hepatotoxicity in rabbits.** Annals 2010; 16:44-46.
16. Sude Eminzade, Fikriye Uras and Fikret V Izzettin. **Silymarin protects liver against toxic effects of anti-tuberculosis drugs in experimental animals.** Nutrition & Metabolism 2008, 5:18.



“

*He who opens a school door,
closes a prison.*

– Victor Hugo –

”

AUTHORSHIP AND CONTRIBUTION DECLARATION

Sr. #	Author-s Full Name	Contribution to the paper	Author=s Signature
1	Sarwat Jahan	First Author	
2	Sana Imran	2nd Author	
3	Naveed Ahsan	3rd Author	