



## SYNOVIAL OSTEOCHONDROMATOSIS; SECONDARY SYNOVIAL OSTEOCHONDROMATOSIS (SOC) OF SHOULDER JOINT

1. Doctor of Medical Imaging  
Department of Radiology  
The University of Lahore.
2. Doctor of Medical Imaging  
Department of Radiology  
The University of Lahore.
3. Doctor of Medical Imaging  
Department of Radiology  
The University of Lahore.
4. Doctor of Medical Imaging  
Department of Radiology  
The University of Lahore.
5. Doctor of Medical Imaging  
Department of Radiology  
The University of Lahore.
6. MBBS (Pb.), Ph.D Ultrasound  
(Sudan, Lugano, Switzerland etc).  
Dean of Allied Health Sciences &  
Head of Radiology Department UOL.
7. MBBS (Pb), M.Phil Anatomy (Pb),  
Ph.D Anatomy (GCU, Lhr).  
Professor & HOD Anatomy/  
Research cell Islam Medical College,  
Pasarur Road, Sialkot.

### Correspondence Address:

M. Zakir  
Department of Radiology  
The University of Lahore  
drtauqirjaved70@gmail.com

### Article received on:

14/05/2018

### Accepted for publication:

25/08/2018

### Received after proof reading:

00/00/2018

## INTRODUCTION

The mechanics secondary Synovial osteochondromatosis of the shoulder joint can be clarified on basis of alteration in its typical structure. This multiaxial, ball-socket synovial joint allows abduction / adduction, flexion / extension, circumduction and rotation of arm.<sup>1</sup> This joint is between the articular cartilages of scapular glenoid cavity and of humerus' head. The peripheral margins of these cartilages are connected by synovial membrane in form of gleno-humeral bursa.<sup>2</sup> The synovial membrane secretes synovial fluid or grease up and lessens rubbing between its articular surfaces amid movement.<sup>3</sup> The tendons of supraspinatus, infraspinatus, teres minor and subscapularis make collar around shoulder joint to keep close intact of ends of the joint.<sup>4</sup> The subacromial bursa lies above the tendon of rotator cuff and below the acromial process and deltoid muscle which

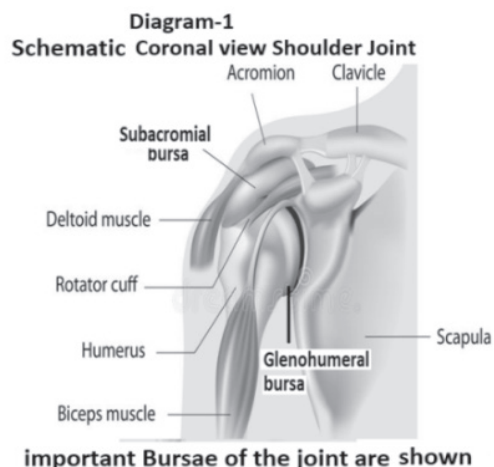
**M. Zakir<sup>1</sup>, Javed Tauqir<sup>2</sup>, Faiza Munawar<sup>3</sup>, Saman Munawar<sup>4</sup>, Nadir Rasool<sup>5</sup>, Syed Amir Gilani<sup>6</sup>, Tauqir Ahmad<sup>7</sup>**

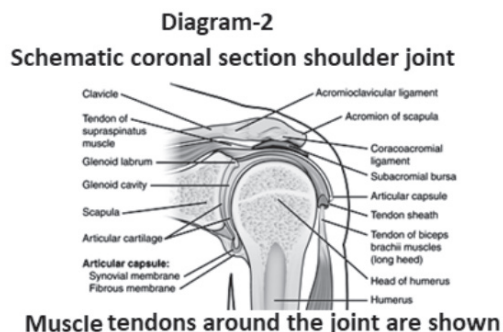
**ABSTRACT...** The shoulder joint trauma after one to two years usually induces growth of its traumatic separated articular cartilage pieces, which sometime further deteriorates into an uncommon condition termed as SOC (Secondary synovial osteo-chondromatosis). **Objectives:** Is to determine the secondary osteochondromatosis of shoulder joint by its specific differentiating features in history, skiagram, sonogram, MRI and microscopic findings of tissue of the affected joint. **Methods:** A male of 34 years with complaint of pain, stiffness and decreased range of movement in left shoulder joint came to an adult orthopedic outdoor unit, Shalimar Hospital, Lahore, Pakistan and admitted in the orthopedic unit 3 for treatment. After physical /clinical examination, Skiagram, sonogram and MRI of the patient's affected shoulder joint were performed by the Radiology department and diagnosed as secondary variety of osteochondromatosis of the shoulder joint. Its nodules excised through arthroscopy were examined histopathologically and found to contain fragments of articular cartilage with ring of calcification. **Conclusion:** MRI imaging as compared to other medical imaging modalities is more precise in estimating diagnosis of secondary osteochondromatosis. However the diagnosis of this disorder is counter confirmed by presence of loose bodies of hyaline cartilage encircled by calcification lamellae on histopathological examination.

**Key words:** Synovial Chondromatosis, Loose Bodies, Multiple Cartilaginous Nodules Shoulder Joint; MRI, Ultrasonogram Image Findings.

**Article Citation:** Zakir M, Tauqir J, Munawar F, Munawar S, Rasool N, Gilani SA, Ahmad T. Synovial osteochondromatosis; secondary synovial osteochondromatosis (SOC) of shoulder joint. Professional Med J 2018; 25(9):1442-1446. DOI:10.29309/TPMJ/18.5058

lessens the resistance amid these coverings during activities of this joint.<sup>5</sup> The capsule of the joint is also reinforced anteriorly by the tendon of long head of biceps brachii piercing its capsule and pass down through bicipital sulcus (Diagram-1&2).





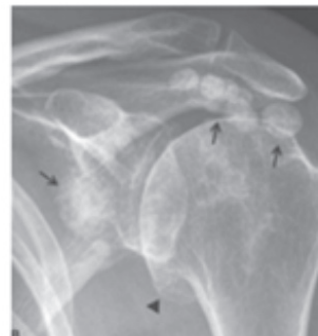
Synovial osteochondromatosis is caused by multiplication and metaplasia of synovial layer, with advancement of different cartilaginous or osteocartilaginous lumps within the joint, bursa or tendinous sheath. The primary Synovial osteochondromatosis is exceptionally unprecedented and has obscure etiology.<sup>6</sup> While the degenerative, necrotic, neuropathetic and inflammatory changes related articular cartilages, bones and bursae of the joint in the event of synovial auxiliary osteochondromatosis have been induced by one to two years of age harm of intra-articular cartilage of the joint. The aim of this case study is to discuss specific identifying features in the history, skiagram, sonogram, MRI and histo-pathological examination of shoulder joint's synovial secondary osteochondromatosis.<sup>7</sup>

**CASE REPORT**

A 34 years male patient with complaint of pain, stiffness and limited range of movement in the left shoulder joint came to the adult orthopedic outdoor, Shalimar Hospital, Lahore, Pakistan and admitted in the orthopedic unit 3 for treatment, on March 3, 2016. These complaints commenced one week before admission, after morning juggling and not relieved by rest or intake of anti-inflammatory and pain killer drugs.<sup>4</sup> However he gave past history of left shoulder joint accidental fracture, more than twelve months back. Hard 3 × 7 mm moveable lump without reddish skin was palpated on his affected shoulder joint during clinical examination. On asking to perform different movements of this shoulder joint, the patient lifted the limb forward upto 30 degree and abduction upto 40 degree. No defect was detected in central nervous, cardiovascular, respiratory, genitourinary, or gastrointestinal systems of this

patient. The patient blood reports of CBC, ESR, Hepatitis B,C, adrenal function tests of this patient were non contributory in diagnosis of this disease Rheumatoid factor was also negative.

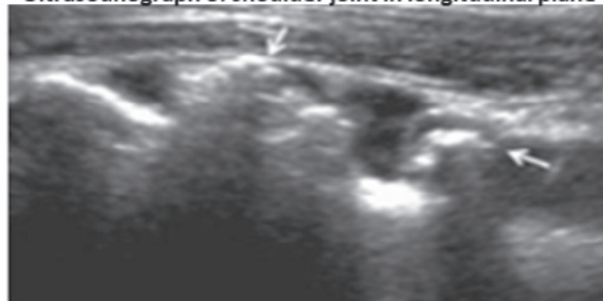
**Image No.1**  
**Anteroposterior view**



• \* Osteophyte shown by Arrow head  
 • Rounded calcification of various size shown by arrows

**Image.2**

**Ultrasounograph of shoulder joint in longitudinal plane**



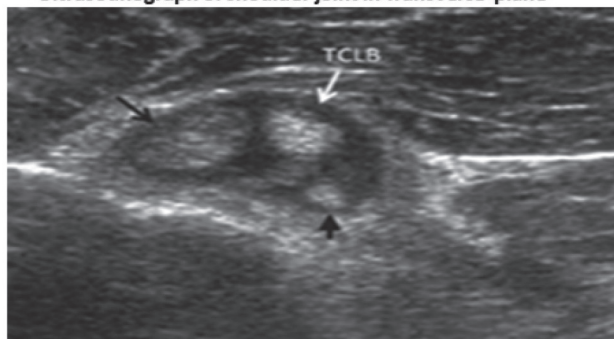
Calcified heterogeneous nodules with posterior acoustic shadow shown by arrows

The plain skiagram of antero-posterior view of the affected shoulder joint demonstrated osteophytes in the inferior articular margin of the humeral head (marked by arrowhead in Image-1) and multiple juxtarticular rounded-shaped calcifications with varied sizes (Indicated by arrows in Image-1).

The Shoulder joint Sonographic study of this case on the longitudinal plane, indicated the tendon sheath of the biceps long head filled by fluid, and calcified heterogeneous nodules with posterior acoustic shadow (marked by arrows in Image-2) While on tranverse plane, the long head tendon of biceps (TBLH) showed hyperechogenic nodules confirmed calcified nodules and hypoechoic nodules diagnosed as non calcified chondromas in the interior of the tendinous sheath. (Image-3)

Image.3

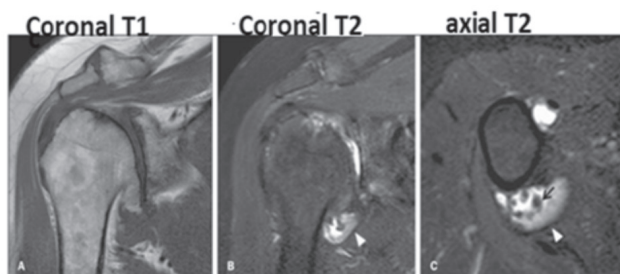
Ultrasounograph of shoulder joint in Transverse plane



Hyperechogenic and Hypoechoic nodules are shown

Coronal T1 weighted magnetic resonance imaging (MRI) of the affected shoulder joint demonstrated osteophytic irregularity of humeral head with its synovial thickening (Image-4).The coronal and axial T2 weighted MRI of the affected shoulder joint exhibited osteophytes by black arrow & synovial thickening as white arrow head (Image-4).

Image.4

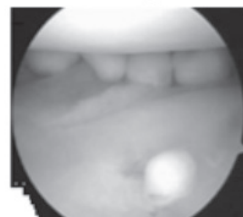


✦White arrows show synovial thickening  
✦Black arrows show osteophytes

On March 10, 2016, the left shoulder joint of admitted patient was exposed by arthroscopy. A large number about 150 and of variable size (5mm to largest 34 mm) intra-articular ossified loose bodies (Image-5) were observed in the shoulder joint and subscapularis bursa and removed using an anterior operative portal and interchanging portals and suction cannula in different joint spaces. Biopsy reported histological features of non-specific synovitis and loose bodies contained fragments of articular cartilage with ring like calcification surrounded by fibroblast rich connective tissue (Figure-1).

Image No5

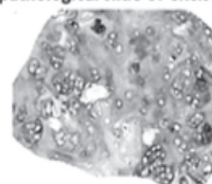
The arthroscopic view



Large number of cartilaginous loose bodies in the subscapularis tendon

Fig.No.1

Histopathological slide of excised nodule



Fragments of articular cartilage with ring like calcification surrounded by fibroblast rich connective tissue

After surgery, the patient was placed in a shoulder immobilizer for 48 hours days. Then movement and strengthening exercises of the joint were commenced.

At his 2-year (dated March11, 2018) follow-up examination, he was found remained asymptomatic and there was no clinical or radiographic evidence of recurrence.

**DISCUSSIONS**

Chondromatoplasia of synovial membrane is the characterization of the Primary synovial osteochondromatosis.<sup>8</sup> It has unknown etiology. Anyway the reason of cartilaginous free bodies inside the joint found in this condition is because of the creation of chondroid foci in the synovium. While the secondary variety synovial osteochondromatosis is a condition that outcomes from the enlargement of cut off particles from the articular ligament or osteophyte in the joint, for example, osteoarthritis, osteochondritis dissecans and osteochondral breaks.<sup>9,10</sup>

Multiple (even hundreds) cartilaginous nodules are commonly formed and most of the nodules of these ailments float in the joint remain viable and increase in size by accepting supplements from



the synovial liquid.<sup>11</sup> These masses are obvious on plain skiagram when the bodies are calcified or hardened.<sup>12</sup> Air or two fold differentiation arthrography might be important to imagine the non-ossified chondromatous bodies.<sup>13</sup> However every single such body may be imagined with MRI. These bodies don't resolve unexpectedly and cause complexities like degenerative osteoarthritis joint subluxation and bursitis.<sup>14</sup>

Numerous surgeons support evacuation of every single free body with subtotal synovectomy.<sup>15</sup> However, it is preferable to perform total synovectomy along with extraction of all imparting bursae, because chances of reappearance of this disorder are common irrespective of the amount of the excision. The finding of present case study contradicts the chances of re-occurrence because after a two- year follow-up examination of this case, no symptomatic, clinical or radiographic evidence of recurrence was found.<sup>16</sup>

## CONCLUSION

One of the uncommon disorders, which are used to be faced in the hospitals and private clinics is Synovial osteochondromatosis of shoulder joint. MRI imaging as compared to x-Rays, ultrasound and C.T is more accurate in estimating diagnosis of this disorder. However the diagnosis of this disorder can also be counter confirmed by presence of loose bodies of hyaline cartilage encircled with calcification lamellae on histopathological examination.

Copyright© 25 Aug, 2018.

## REFERENCES

1. Wittkop B, Davies AM, Mangham DC. **Primary synovial chondromatosis and synovial chondrosarcoma: A pictorial review.** *EurRadiol* 2002;12(8):2112–2119.
2. Sugimoto K, Iwai M, Kawate K, Yajima H, Takakura Y. **Tenosynovial osteochondromatosis of the tarsal tunnel.** *Skeletal Radiol* 2003;32(2):99–102.
3. Mohr W. **Is synovial osteo-chondromatosis a proliferative disease?** *Pathol Res Pract* 2002;198(9):585–588.
4. McGrory JE, Rock MG. **Synovial chondromatosis of the shoulder.** *Am J Orthop* 2000;29(10):793–795.
5. Holmlund AB, Eriksson L, Reinholt FP. **Synovial chondromatosis of the temporomandibular joint: Clinical, surgical and histological aspects.** *Int J Oral MaxillofacSurg* 2003;32(2):143–147.
6. David T, Drez DJ Jr. **Synovial chondromatosis of the shoulder and biceps tendon.** *Orthopedics* 2000; 23(6):611–613.
7. Claudio Chillemi, Mario Marinelli, Vincenzo de Cupis. **Primary synovial chondromatosis of the shoulder: clinical, arthroscopic and histopathological aspects.** 2005.
8. Sah, Alexander P. MD; Geller, David S. MD; Mankin, Henry J. MD; Rosenberg, Andrew E. MD; DeLaney, Thomas F. MD; **Malignant Transformation of Synovial Chondromatosis of the Shoulder to Chondrosarcoma: A Case Report** 2007.
9. Fowble, V. A., Levy, H.J. **Arthroscopic treatment for synovial chondromatosis of the shoulder.** *Arthroscopy.* 2003;19:E2.
10. Richtte, P., Corvol, M., Bardin, T. **Estrogen, cartilage, and osteoarthritis.** *Joint Bone Spine.* 2003;70:257–262.
11. Jun'ichiro Hamada, MD, PhD' Kazuya Tamai, MD, PhD, YasumoriKoguchi, MD, PhD, Wataru Ono, MD, PhD, Koichi Saotome, MD, PhD. **Case report: A rare condition of secondary synovial osteochondromatosis of the shoulder joint in a young female patient,** 2005.
12. Murphey MD, Vidal JA, Fanburg-Smith JC, et al. **Imaging of synovial chondromatosis with radiologic-pathologic correlation.** *Radiographics.* 2007;27:1465–88.
13. Walker EA, Murphey MD, Fetsch JF. **Imaging characteristics of tenosynovial and bursal chondromatosis.** *Skeletal Radiol.* 2011; 40:317–25.
14. Trajkovski T, Mayne IP, Deheshi BM, et al. **Synovial chondromatosis of the shoulder: open synovectomy and insertion of osteoarticular allograft with internal fixation to repair intraoperative glenohumeral joint instability.** *Am J Orthop (Belle Mead NJ).* 2011; 40:E154–8.
15. Lunn JV, Castellanos-Rosas J, Walch G. **Arthroscopic synovectomy, removal of loose bodies and selective biceps tenodesis for synovial chondromatosis of the shoulder.** *J Bone Joint Surg Br.* 2007;89:1329–35.
16. Lasmar NP, Vieira RB, Rosa JO, et al. **Condromatosesinovial.** *Rev Bras Ortop.* 2010; 45:490–2.

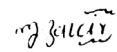





“

*Practice like you're never won.  
Perform like you're never lost.*

– Unknown –

”

#### AUTHORSHIP AND CONTRIBUTION DECLARATION

Sr. #	Author-s Full Name	Contribution to the paper	Author=s Signature
1	M. Zakir	Acquisition, Analysis and Interpretation fo data.	
2	Javed Tauqir	Acquisition, Analysis and Interpretation fo data.	
3	Faiza Munawar	Acquisition, Analysis and Interpretation fo data.	
4	Saman Munawar	Acquisition, Analysis and Interpretation fo data.	
5	Nadir Rasool	Acquisition, Analysis and Interpretation fo data.	
6	Syed Amir Gilani	Conception and design.	
7	Tauqir Ahmad	Rectification and reviewing.	