



CURCUMA LONGA;

CURCUMA LONGA AGAINST CARBON TETRACHLORIDE INDUCED LIVER INJURY: A BIOCHEMICAL AND HISTOPATHOLOGICAL EXPERIMENTAL STUDY

1. MBBS, M.Phil
Associate Professor
Department of Anatomy
Suleman Roshan Medical College,
Tando Adam, Sindh, Pakistan
2. MBBS, M.Phil
Assistant Professor
Department of Pathology
Bhitai Dental and Medical College
Mirpurkhas, Sindh, Pakistan
3. MBBS, M.Phil
Assistant Professor
Department of Anatomy
Indus Medical College
Tando Muhammad Khan,
Sindh, Pakistan

Correspondence Address:

Dr. Sana Naz
Associate Professor
Department of Anatomy,
Suleman Roshan Medical College
Tando Adam, Sindh, Pakistan.
drsanaarain@gmail.com

Article received on:

28/09/2017

Accepted for publication:

15/04/2018

Received after proof reading:

00/00/2018

INTRODUCTION

Curcuma longa (CL) is a perennial herb. Botanically, it is a rhizome which belongs to the botany family "Zingiberaceae". The CL rhizome is a native South Asian herb. Common people call it as the turmeric.¹ Naturally; the CL has a unique culinary odor and taste, hence widely used in the cooking. People know the benefits of this unique rhizome since centuries hence it is termed as one of the "herbal remedy". Its medicinal properties are publicly valued like any other herb in the folk medicine. It is used as tonic which increases vigor and vitality through relieving the fatigue. It is used for the digestive problems because it increases the digestive juices and exerts carminative effects.^{1,2} CL protects the gastric mucosa and exerts gastroprokinetic activity.³ A previous study² reported its efficacy against the helminthes, sex disorders, bronchial asthma and urinary diseases. Its novel effects reported include; anti-cancer potential,³ antimicrobial activity,⁴ anti-inflammatory effects⁵ and anti-oxidant activity.⁶ A previous study

Sana Naz¹, Faisal Irshad², Hina Mawani³

ABSTRACT... Objectives: To analyze the hepatoprotective effects of Curcuma longa (CL) against carbon tetrachloride (CCl₄) induced chemical injury in experimental rats. **Study Design:** Experimental study. **Setting:** Indus Medical College in collaboration with Animal house of Sindh Agriculture University Tando Jam. **Period:** March 2016 to August 2016. **Methodology:** Sixty adult male rats were selected according to inclusion and exclusion criteria. Rats were divided randomly into 3 groups – as group A. controls, group B – received CCl₄ and group C- received CCl₄ + CL orally. Blood samples were taken after 4 weeks of therapy by cardiac puncture. 5μ thick liver tissue sections were stained for light microscopy examination. Analysis of data was performed on Statistix 9.0 (USA) at statistical significance of p-value ≤ 0.5. **Results:** Liver cell biochemical markers of injury and histopathological examination show the Curcuma longa is effective against carbon tetrachloride induced liver injury (P <0.05). Liver histology was improved by the curcuma longa therapy. **Conclusion:** Liver aminotransferase and histology were improved significantly by the curcuma longa therapy in carbon tetrachloride induced liver injury.

Key words: Carbon Tetrachloride, Liver Injury, Curcuma Longa, Rat.

Article Citation: Naz S, Irshad F, Mawani H. Curcuma longa; curcuma longa against carbon tetrachloride induced liver injury: a biochemical and histopathological experimental study. Professional Med J 2018; 25(7):1112-1116.
DOI:10.29309/TPMJ/18.4363

reported its wound healing potential.⁷ Various experimental studies have witnessed its efficacy against the induced liver cirrhosis, chronic liver affections and chemical induced injuries in animal model studies.⁸⁻¹⁰ Carbon tetrachloride (CCl₄) is a notorious liver toxicant. It has been used for testing the pharmacological efficacy of many herbs in animal models. Its mechanism of injury lies in its induction of free radical reactive oxygen species (ROS). The experimental animal model studies are conducted so that these agents may be used in human disease, because human beings cannot be directly intoxicated with highly toxic agents such as the CCl₄.^{11,12} The CCl₄ damages the hepatocyte cell membrane through ROS formation. It increase the blood levels of hepatocyte injury biomarkers and tissue architecture is destroyed.^{13,14} Liver aminotransferase, released from hepatocyte cytoplasm and mitochondria, are of diagnostic value clinically.^{11,15} Previous studies^{7,8} evaluated the CL potential against CCl₄ induce cell injury,

but underlying mechanism of how CL protects is not studied in detail. The present research hypothesized that the Curcuma longa has no free radical scavenging activity and no hepatocyte cell membrane effects. The present study was conducted to analyze the underlying mechanisms of Curcuma longa experimental rat model of carbon tetrachloride induced liver injury.

MATERIALS AND METHODS

The present experimental research study was conducted at the Indus Medical College in collaboration with Animal house of Sindh Agriculture University Tando Jam from March 2016 to August 2016.

Sixty adult male rats were selected according to inclusion and exclusion criteria. Non probability purposive sampling was chosen for animal selection. Male rats of adult age, weight 200-250 g and feeding and moving actively within the cages were included. Sick male rats not feeding well and female rats was exclusion criterion exercised strictly. Animal house is well equipped. A caretaker person was assigned to look after the experimental animals and to inform for any problem of feeding and movement within the cages. Caretaker was asked to keep the cages clean, ensure chow, pure water, optimal temperature (23- 25 °C) and 12/12 hours dark and light cycle.

The study researchers were assigned to supervise how the animals are being handled. Strict supervision by each researcher was mandatory. Rats were divided randomly into 3 groups – as group A. controls (0.9% isotonic saline orally daily), group B – received CCl₄ and group C- received CCl₄ + CL (250 mg/kg) orally on alternate days. The treatment period was 4 weeks. Experimental protocols were followed strictly. The CCl₄ was mixed in Olive oil as vehicle in 1:1 ratio. Given dose was 1.9 ml/kg orally.¹⁵ Also 250 mg/kg of CL was given orally. This therapy was used on alternate days for 4 weeks consecutively as described.¹⁶ After 4 weeks, 24 hours were elapsed for blood sampling by cardiac puncture. Blood was centrifuged at 4000 rpm (15 minutes), sera were separated for estimation of liver aminotransferase

(alanine transaminase (ALT), aspartate transaminase (AST), alkaline phosphatase (ALP) and Gamma glutamyl transferase (γ-GT), serum bilirubin, and Prothrombin time. Serum anti-oxidant enzymes - superoxide dismutase (SOD), glutathione peroxidase (GPX) and catalase (CAT) were analyzed by ELISA assay kit (Fortress diagnostics). Chemistry Analyzer (Hitachi Roche) was used for biochemical estimation. Sacrifice of rats was done as described.¹⁷ Liver was freed from peritoneum after laparotomy, and tissue shifted to formaldehyde containing containers. Paraffin blocks were used for embedding of tissues. 5μ thick tissue sections were cut by microtome and stained with H & E stain for light microscopy examination. Analysis of data was performed on Statistix 9.0 (USA). One way- ANOVA and post Hoc Bonferroni's were used for continuous variables and results were presented as mean +/-SD. Probability (P)-value ≤ 0.5 was considered statistically significant.

RESULT

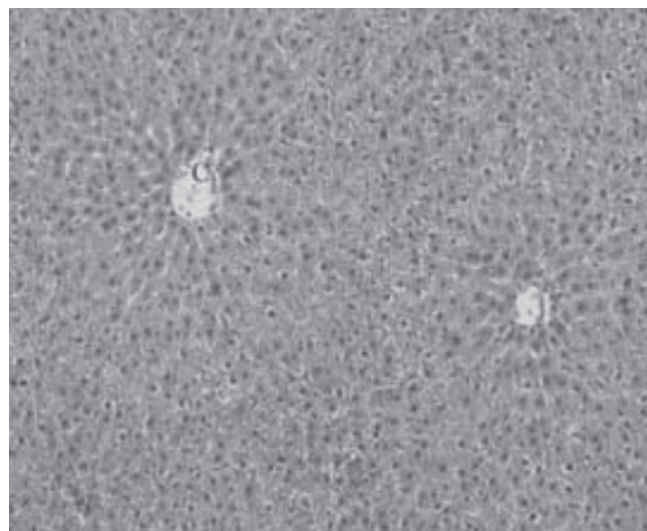
Carbon tetrachloride induced liver injury was mitigated by the Curcuma longa (CL) in the present experimental rat model study. Liver aminotransferase, serum bilirubin and Prothrombin time (Table-I). CL treated animals (group C) showed significant improvement of liver aminotransferase, serum bilirubin and Prothrombin time compared to CCl₄ group (group B) (P=0.0001). Histological examination of liver tissues is expressed in the Photomicrographs 1-4. CL treated liver tissue shows reduction of carbon tetrachloride induced injury. CCl₄ caused damage of liver as characterized by necrosis, fatty change and vacuolar degeneration.

DISCUSSION

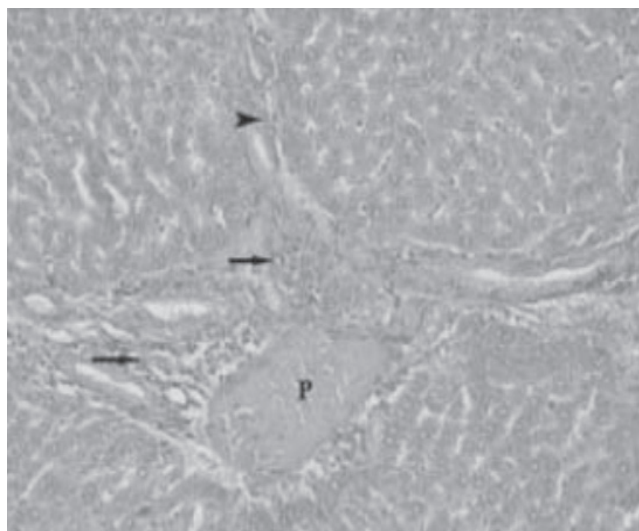
The present experimental study proved the ameliorating effects of CL by liver aminotransferases and histopathological examination. Liver aminotransferases were improved significantly (P<0.05) by CL compared to CCl₄ treated rats; hence the null hypothesis was rejected. CL is a food additive used as taste enhancer in food cooking. CL protected the hepatocytes at the cellular level as shown by microscopy.

	Group A (Controls)	Group B (CCl ₄)	Group C (CCl ₄ + CL)	P-value
ALT (U/L)	37.8±8.8	69.5±13.2	63.6±11.0	0.0001
AST (U/L)	26.7±4.1	51.1±5	39.5±11.5	0.009
ALP (U/L)	73.8±13.0	143.5±29.5	115.5±37.5	0.029
LDH (U/L)	110.5±17.3	170.5±25.3	153.5±31.1	0.002
Y-GT (U/L)	34.6±5.12	77.8±6.0	56.5±21.8	0.021
Bilirubin (mg/dl)	0.5±0.15	1.51±0.31	1.43±0.12	0.041
Creatinine (mg/dl)	0.7±0.11	1.5±0.13	1.2±0.31	0.001
Prothrombin time (sec)	0.5±0.15	1.51±0.31	1.43±0.12	0.041

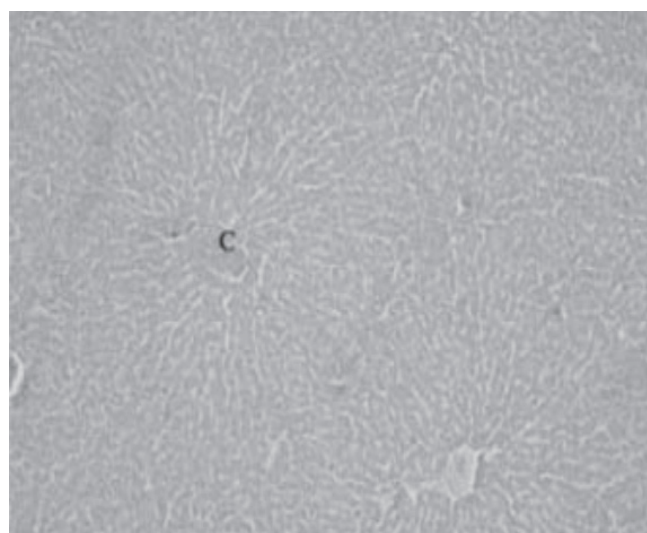
Table-I. Liver function tests and cellular anti oxidant enzymes in control and experimental animal groups (n=60)



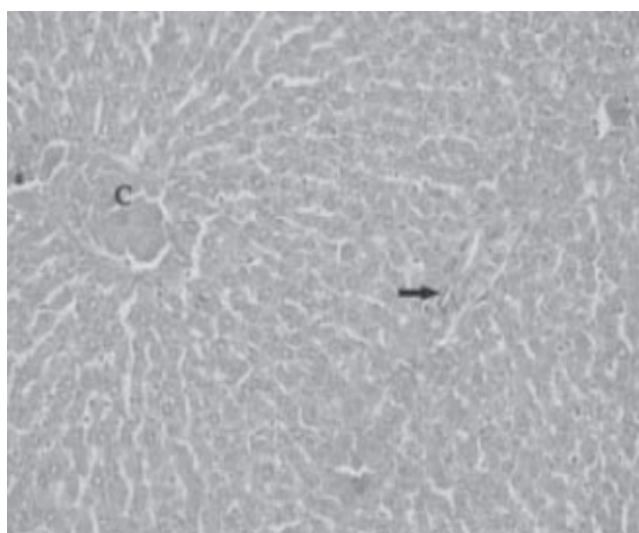
Photomicrograph-1. Control- Normal liver histology (hepatocytes cords)



Photomicrograph-2. CCl₄ group- Liver shows severe injury (inflammatory infiltrates, necrosis, vacuolar degeneration fibrosis and collagen fibers)



Photomicrograph-3. Liver injury is decreased (Central venule (c) is normal. Fibrosis is minimized at the corners of liver specimen)



Photomicrograph-4. Liver injury is decreased (Central venule (c) is normal. Fibrosis is minimized at the corners of liver specimen)

These events of CL occur by reduced inflammation, cell injury and fibrogenesis.¹⁸ CL treatment minimized the liver injury compared to the CCl₄ treated rats as evidenced by a rise in liver enzymes and histological examination. Our findings are in agreement with previous studies.¹⁸⁻²⁰ Rise in liver aminotransferases is a biomarker of hepatocyte cell membrane injury,²⁰ which were improved by CL at dose of 250 mg/kg body weight in our present experimental study. Hepatoprotective effects of CL are exerted by its flavonoids and volatile oils (atlantone, zingiberene and tumerone) contained in it.²¹ CL exerts free radical annihilating activity has also been proposed as a one of its mechanism.²² CL elevates the natural anti oxidant enzymes, has been reported.^{7,8} Hepatoprotective effects of CL are consistent with previous studies.²¹⁻²³

A previous study reported the volatile oils (atlantone, zingiberene and tumerone) of CL possess anti inflammatory activity.²³ These effects are proved by the present study. Severe rise in liver aminotransferases was noted in the CCl₄ treated animals is in keeping with previous studies.^{24,25} Also the microscopy showed severe distortion and injury of liver tissue in CCl₄ treated liver specimens which correlated with a concomitant rise in liver aminotransferases. Our these findings are supported by previous studies.^{25,26} Excellent results of hepatoprotection by CL has been noted in the present study. CL improved the histological architecture of liver. The portal triad congestion, inflammatory infiltrate, necrosis, collagen content and fibrosis were highly mitigated by the CL treatment. Central venule and sinusoids were found near normal by the CL action. Hydropic changes and necrosis were minimized by CL therapy. Carbon tetrachloride injury was ameliorated by CL as shown in the photomicrograph 3 and 4.

These findings are supported by previous studies.²⁰⁻²⁵ Singh et al²⁶ also reported similar histological findings. The present study has a few limitations such as the; inflammatory markers and antioxidant enzymes were not analyzed due to funding issues. However, study strength lies in its experimental design, random sampling and

histological examination is one of most reliable finding to conclude the hepatoprotective effects of curcuma longa.

CONCLUSION

The present study concludes the curcuma longa exerts hepatocellular protection. Liver aminotransferase and histology were protected significantly by the curcuma longa therapy against the carbon tetrachloride induced liver injury. Further research studies are warranted and role of curcuma longa should be realized for chemical induced liver injury in clinical practice.



Copyright© 15 Apr, 2018.

REFERENCES

1. Zaman SU, Akhtar N. **Effect of Turmeric (Curcuma longa Zingiberaceae) Extract Cream on Human Skin Sebum Secretion.** Trop J Pharm Res 2013; 12 (5): 665-669.
2. Krup V, Prakash LH, Harini A. **Pharmacological Activities of Turmeric (Curcuma longa linn): A Review.** J Homeop Ayurv Med 2013; 2:133.
3. Shahiq UZ, Naveed A, Barkat AK, Tariq M, Akhtar R, Arshad M, Muhammad NA, Atif A. **Development of a sebum control cream from a local desert plant Capparis decidua.** J Med Plant Res 2012; 6: 744-78.
4. Rasul, A, Akhtar N, Khan BA, Mahmood T, Zaman SU, Khan HMS. **Formulation development of a cream containing fennel extract: in vivo evaluation for anti-aging effects.** Pharmazie 2012; 67: 54-58.
5. Kohli K, Ali J, Ansari M, Raheman Z: **Curcumin: a natural anti-inflammatory agent.** Indian J Pharmacol 2005, 37(3):141-147.
6. Shiyou L, Wei Y, Guangrui D, Ping W, Peiying Y, Bharat BA. **Chemical Composition and Product Quality Control of Turmeric (Curcuma longa L).** Pharmaceut Crops 2011; 2: 28-54.
7. Panchatcharam M, Miriyala S, Gayathri VS, Suguna L. **Curcumin improves wound healing by modulating collagen and decreasing reactive oxygen species.** Mol Cell Biochem 2006, 290(1):87-96.
8. Miriyala S, Panchatcharam M, Rengarajulu P: **Cardioprotective effects of curcumin. In: The molecular targets and therapeutic uses of curcumin in health and disease** 2007, 595:359-377.
9. Alshawsh MA, Abdulla MA, Ismail S, Amin ZA. **Hepatoprotective effects of Orthosiphon stamineus extract on thioacetamide induced liver cirrhosis in rats.** Evid Based Complement Alternat Med 2011; 2011: 1-6.

10. Kadir FA, Othman F, Abdulla MA, Hussan F, Hassandarvish P. **Effect of *Tinospora crispa* on thioacetamide-induced liver cirrhosis in rats.** Indian J Pharmacol 2011, 43(1):64.
11. Obi FO, Omogbal LA, Orlafo OS and Ovat OD. **Effect of a Short Time Post Carbon Tetrachloride Treatment Interval on Rat Plasma Enzyme Levels and Percentage Mortality.** J Applied Sci Environ Mgt 2001; 5: 5-8.
12. Muriel P, Albo N and Perez-Alvarez VM. **Kupffer cells inhibition prevents hepatic lipid peroxidation and damage induced by carbon tetrachloride.** Comp Biochem Physiol C Toxicol Pharmacol 2001; 130: 219-26.
13. Rasha SA, Ashraf AA and Aly R. **Carbon tetrachloride-induced liver disease in rats: the potential effect of supplement oils with vitamins E and C on the nutritional status.** German Med Sci 2009; 7: 1612-3174.
14. Rost DA, Welker DA, Welker J, Millonig G, Berger I, Autschbach F, et al. **Liver-homing of purified glucose oxidase: A novel in vivo model of physiological hepatic oxidative stress (H₂O₂).** J Hepatol 2007; 46: 482-91.
15. Essawy AE, Abdel-Moneim AM, Khayyat LI and Elzergy AA. **Nigella sativa seeds protect against hepatotoxicity and dyslipidemia induced by carbon tetrachloride in mice.** J Appl Pharm Sci 2012; 2 (10):021-5.
16. Movssaghi S, Sharifi ZN, Mohammadzadeh F, Soleimani M. **Pentoxifylline protects the rat liver against fibrosis and apoptosis induced by acute administration of 3,4-Methyleneoxymethamphetamine (MDMA or Ecstasy).** Ir J Basic Med Sci 2013; 16: 922-27.
17. Nayak S, Nalabothu P, Sandiford S, Bhogadi V, and Adogwa A. **Evaluation of wound healing activity of *Allamanda cathartica* L. and *Laurus nobilis* L.** Extracts on rats. BMC Compl Alt Med 2006; 6: 12.
18. Wang ME, Chen YC, Chen IS, Hsieh SC, Chen SS, Chiu CH. **Curcumin protects against thioacetamide-induced hepatic fibrosis by attenuating the inflammatory response and inducing apoptosis of damaged hepatocytes.** J Nutr Biochem 2012; 11: 120-8.
19. Hurkkeri VI, Jaiparkash B, Lavhale RV, Karadi RV and Kuppast IJ. **Hepatoprotective activity of *Anthus Excelsa* Roxb leaf extract on experimental liver damage in rats.** J Pharmacogn 2002; 11: 120-28.
20. Shaarawy SM, Tohamy AA, Elgendy SM Elmageed ZY, Bahnasy A, Mohamed MS, et al. **Protective effects of garlic and silymarin on NDEA-induced rats hepatotoxicity.** Int J Biol Sci 2009; 5(6): 549-57.
21. Salma SM, Abdulla MA, AlRashdi AS, Ismail S, Alkiyumi SS, Gulbabapour S. **Hepatoprotective effect of ethanolic extract of *Curcuma long* on thiocetamide induced liver cirrhosis in rats.** BMC Compl Alt Med 2013; 13 :56.
22. Girish C, Koner BC, Jayanthi S, Ramachandra Rao K, Rajesh B, Pradhan SC. **Hepatoprotective activity of picroliv, curcumin and ellagic acid compared to silymarin on paracetamol induced liver toxicity in mice.** Fundam Clin Pharmacol 2009, 23(6):735-45.
23. Lee GH, Lee HY, Choi MK, Chung HW, Kim SW, Chae HJ. **Protective effect of *Curcuma longa* L. extract on CCl₄-induced acute hepatic stress.** BMC Res Notes 2017; 10:77.
24. Rajesh M and Latha M. **Preliminary evaluation of anti-hepatotoxic activity of Kamilari, a polyherbal formulation.** J. Ethnopharmacol 2004; 91: 99-104.
25. Rezaei-Moghadam A, Mohajeri D, Rafiei B, Dizaji R, Azhdari A, Yeganehzad M, Shahidi M, Mazani M. **Effect of turmeric and carrot seed extracts on serum liver biomarkers and hepatic lipid peroxidation, antioxidant enzymes and total antioxidant status in rats.** Bioimpacts 2012; 2(3):151-157.
26. Singh H, Sidhu S, Chopra K, Khan MU. **The novel role of β-aescin in attenuating CCl₄-induced hepatotoxicity in rats.** Pharmac Biol 2017; 55 (1):749-757.

AUTHORSHIP AND CONTRIBUTION DECLARATION

Sr. #	Author-s Full Name	Contribution to the paper	Author=s Signature
1	Sana Naz	Literature review, Materials handling, Collection of compilation of results, statistical analysis, Manuscript write up, Proof reading, Drug literature, Drug dose, drug toxicity, dose calculation.	
2	Faisal Irshad	Statistical analysis, Manuscript write up, Proof reading, Correspondence Drug dose, drug toxicity, dose calculation, Manuscript write up, Proof reading.	
3	Hina Mawani	Concept, Materials handling, Collection of Biopsy materials, Staining, microscopy, compilation of results, statistical analysis, manuscript write up, Biochemical analysis and laboratory testing, compilation of results , Proof reading.	