



# VISUAL OUTCOME IN DIABETIC MACULAR EDEMA AFTER GRID LASER TREATMENT

Dr. Muhmmad Jameel Shahid<sup>1</sup>, Dr. Faheem Ahmad<sup>2</sup>, DR. Muhammad Asif<sup>3</sup>,  
Muhmmad Nabeel Sultan<sup>4</sup>

1. MBBS.FCPS  
Assistant Professor Ophthalmology  
Independent Medical College,  
Faisalabad
2. MBBS.MCPS.FCPS  
Associate Professor Ophthalmology  
Independent Medical College  
Faisalabad
3. MBBS. Medical Officer THQ  
Samundari
4. Medical Student  
Independent Medical College,  
Faisalabad

**Correspondence Address:**  
Dr. Faheem Ahmad  
Associate Professor Ophthalmology  
Independent Medical College  
Faisalabad  
doctorfaheem2000@yahoo.com  
P-79 Officer Block, Muslim Town,  
Faisalabad  
doctorfaheem2000@yahoo.com

**Article received on:**

17/11/2015

**Accepted for publication:**

24/02/2016

**Received after proof reading:**

12/04/2016

**ABSTRACT:** Regarding the causes of blindness, Diabetic retinopathy is a one the major cause of blindness in all types persons from both industrialized and developing countries. Due to inadequate eating habits, prevalence of diabetic retinopathy is increasing. Both focal and diffuse leakage from retinal capillaries can cause Diabetic macular edema. Various treatment modalities for macular photocoagulation are focal laser, Grid laser and modified grid used in patients having diabetic macular edema **Study Design:** Prospective, interventional, noncompetitive case series. **Setting:** Department of Ophthalmology, Allied Hospital and Department of Ophthalmology, Divisional Headquarter Hospital Faisalabad. **Period:** One year from April 2012 to April 2013. **Materials and Methods:** A total of 200 eyes of 200 patients with clinical significant macular edema that met the inclusion criteria were enrolled. **Results:** In this study, 200 patients with diabetic macular edema were studied. Of these 121 (60.5%) were males and 79 (39.5%) females with mean age of 38.52 years (SD 7.512, Range 25-50 years). All patients had diffuse, clinically significant macular edema at baseline for which they had received grid laser photocoagulation. **Discussion:** In recent past number of diabetic patients all over the world has increased that has caused increase incident of diabetic retinopathy .So in patients having diabetic retinopathy, macular edema can cause deterioration in visual acuity during any stage of diabetic retinopathy. The pathogenesis of Diabetic macular edema (DME) is the disruption of inner blood – retinal barrier that is known to be associated with metabolic alteration affecting the retinal pigment epithelium or retinal vascular endothelium. Focal and/or grid laser photocoagulation is being considered as the treatment of DME. **Conclusion:** Macular photocoagulation was found to be an effective method of treatment for CSME among diabetic patients, which has resulted in a positive visual outcome in 87% of the patients (stable and improved vision).

**Key words:** Clinical Significant Macular Edema (Csme), Grid Laser Photo Coagulation

**Article Citation:** Shahid MJ, Ahmad F, Asif M, Sultan MN. Visual outcome in diabetic macular edema after grid laser treatment. Professional Med J 2016;23(4):478-483.  
**DOI:** 10.17957/TPMJ/16.2856

## INTRODUCTION

Regarding the causes of blindness, retinal complication of diabetes are one of the commonest causes leading to blindness in all types persons all over the world. Due to inadequate eating habits, prevalence of diabetic retinopathy is increasing.<sup>1</sup> All patients who are diagnosed as case diabetes mellitus are at risk of developing Diabetic macular edema that cause severe visual loss in any stage of diabetic retinopathy. In diabetic macular edema patient develop painless loss of central vision and vision loss may range from mild vision loss to severe vision loss.<sup>2</sup> Regarding mechanism of visual loss in diabetic retinopathy Diabetic macular edema (DME) is the most common

cause of loss of vision in patients suffering from diabetes that can produced in any stage during the course of disease (diabetic retinopathy).<sup>3,4</sup> Both focal and diffuse leakage from retinal capillaries can cause Diabetic macular edema. Early treatment diabetic retinopathy study (ETDRS) group had recommended Macular photocoagulation treatment in diabetic patients having clinically significant macular edema (CSME).<sup>5</sup>

Various treatment modalities for macular photocoagulation are focal laser, Grid laser and modified grid used in patients having diabetic macular edema. In focal LASER treatment, Laser

is applied directly on micro aneurysm causing macular edema while in grid Laser treatment, Laser is applied in GRID pattern around the area of diffuse capillary leakage. For patients who have focal and diffuse leakage on Fundus Fluorescein Angiography (FFA) then modified grid that is a combination of focal and grid treatments is applied.<sup>6,7</sup> In case of clinical significant macular edema grid pattern laser is used for areas of diffuse thickening located more than 500 micron from the center of macula and 500 micron from temporal margin of optic disc. Spot size should be 100 to 200 micron, duration of laser 0.10 second. Burns should be gentle and light in intensity which only cause blanching and one burn width apart.

Regarding the mechanism by which LASER works in diabetic macular edema is still not explored. However it is considered that the laser is absorbed through melanin pigments present in the epithelium of retina and choroid and in the micro aneurysm by hemoglobin. All these factors lead to increase in oxygen permeability from choroid to inner retina, subsequently hampering the process of neovascularization of retina. Similarly, thrombosis of the micro aneurysm of retinal vessels also decreases the vascular leakage.<sup>9</sup>

After laser treatment patient notices the benefit after 3-4 months because initially there is decrease in visual acuity before the treatment becomes effective. In patients having persistent macular edema after macular photocoagulation then in such cases a Additional treatment can be required. Our objective in this article was to study the impact of Grid laser (Argon LASER) treatment on diabetic patients with CSME, in terms of effect on visual acuity.

## OBJECTIVE

To determine the frequency of improvement in the visual acuity and its stability in patients undergoing Laser photocoagulation for diabetic macular edema (GRID PATTERN).

## MATERIALS AND METHODS

This was an interventional, noncompetitive

case series carried out at the Department of Ophthalmology, Allied Hospital and Department of Ophthalmology, Divisional Headquarter Hospital Faisalabad. The study was carried out over a period of one year from April 2012 to April 2013. A total of 200 eyes of 200 patients with clinical significant macular edema that met the inclusion criteria were enrolled. We included diabetic patients of all ages and both sexes having non-proliferative diabetic retinopathy with diffuse, clinically significant diabetic macular edema.

In these patients, who were selected for our study received Grid laser treatment by Argon Laser in Allied Hospital, Faisalabad. The Green laser photocoagulation is also treatment modality for Clinical significant macular edema in diabetic retinopathy as it is relatively safe and an outdoor procedure. All these patients had clinical significant macular edema due to diabetic retinopathy in any stage of diabetic retinopathy. Before to start this study permission was granted from the institutional Ethical Committee. In all the patients complete History was taken from the patients. After that complete ocular examination done in which anterior segment examination done by slit lamp and posterior segment examination by slit lamp bio microscopy using Volk +90 D or Goldman,s –mirror contact lens. Best corrected visual acuity (BCVA) using Snellen.s visual acuity chart was recorded before every session of laser photocoagulation and on each follow-up. Fundus fluorescein angiography was done in patients having decrease in visual acuity in the absence of obvious pathology to rule ischemic maculopathy. Indication for treatment was CSME, i.e CSME exists if Any retinal thickening within 500 micron of the foveal center or Hard exudates within 500  $\mu$ m of the foveal center that are associated with adjacent retinal thickening or An area of retinal thickening at least 1 disc area in size, any part of which is located within 1 disc area of the foveal center. Treatment of all cases of CSME were done according to recommendations of ETDRS study group. Consent was taken from all patients on prescribed written form. Before to Treatment topical anesthesia eye drops was used in patient eyes. Argon laser machine having green light was

used to apply Laser. Follow-up examination was done initially on monthly basis followed by 03 monthly visits and subsequently depending on the resolution of macular edema.

During the last follow-up BCVA after laser was measured using Snellen,s VA chart. Improvement in vision on the snellen, VA chart by one line or no change in visual acuity was recorded as a positive visual outcome while decrease vision of more than two lines of Snellen,s VA chart was recorded as negative visual outcome. Complete ocular examination were carried out at each follow-up visit. For statistical analysis software SPSS-19 was used and Chi-square test was applied. P value of  $\leq 0.05$  was considered significant.

## RESULTS

In this study, 200 patients with diabetic macular edema were studied. Of these 121 (60.5%) were males and 79 (39.5%) females with mean age of 38.52 years (SD 7.512, Range 25-50 years).All patients had diffuse, clinically significant macular edema at baseline for which they had received grid laser photocoagulation. All the patients were observed for four months. Patient selected for

the study were divided into three groups after photocoagulation. Rate of changes in visual acuity was evaluated between three groups.

### Group A (improvement in visual acuity)

This group included those cases with visual acuity improved after Grid laser photocoagulation. 22 eyes of patients (male 72.7%, female 27.3%) out of 200 eyes having improvement after Grid laser photocoagulation.

### Group B (stable visual acuity)

The patients in this group were included those having stable visual acuity after Grid laser photocoagulation. 152 eyes of patients (male 57.9%, female 42.1%) out of 200 eyes having stable visual acuity after laser.

### Group C (decrease visual acuity)

All the patients who have decrease in visual acuity after application of laser in CSME. 26 eyes of patients (male 65.4%, female 34.6%) out of 200 eyes having decreased in visual acuity after application of laser.

	Frequency	Percent	Valid Percent	Cumulative Percent
Male	121	60.5	60.5	60.5
Female	79	39.5	39.5	100.0
Total	200	100.0	100.0	

Table-II. Sex wise Distribution of Patients

	Frequency	Percent	Valid Percent	Cumulative Percent
Valid <30	71	35.5	35.5	35.5
36-45	85	42.5	42.5	78.0
46>	44	22.0	22.0	100.0
Total	200	100.0	100.0	

Table-III. Age wise Distribution of Patients

	Frequency	Percent	Valid Percent	Cumulative Percent
Valid Improved	22	11.0	11.0	11.0
Stable	152	76.0	76.0	87.0
Decreased	26	13.0	13.0	100.0
Total	200	100.0	100.0	

Table-IV. Visual Outcome

	N	Mean	Std. Deviation	95% Confidence Interval for Mean	
				Lower Bound	Upper Bound
Improved	22	32.59	6.609	29.66	35.52
Stable	152	39.09	7.308	37.91	40.26
Decreased	26	40.19	7.359	37.22	43.16
Total	200	38.52	7.512	37.47	39.56

Table-V. Descriptive Outcome

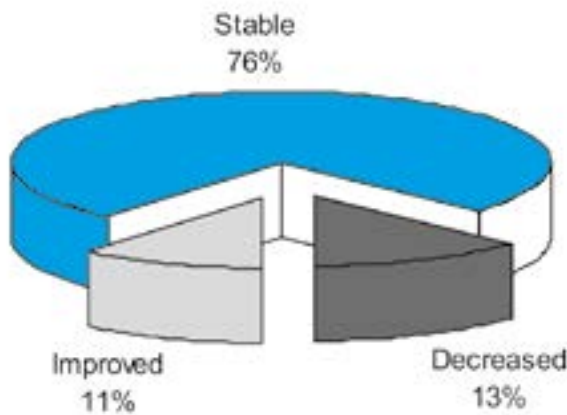


Figure-1. Distribution of respondents according to improvement of visual acuity

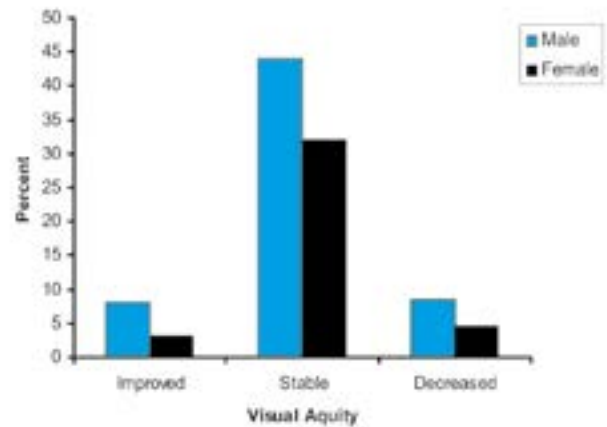


Figure-2. Improvement in visual acuity regarding gender.

M: F ratio:	60.5% : 39.5% (Table II)
Age group: (Table III)	Range 25-50 years
Follow up (Outcome):	03 Months
Improved visual acuity (group A):	11% (table IV)
Stable visual acuity (group B):	76 % (table IV)
Decrease visual acuity (group C):	13 % (table IV)
Outcome M : F ratio:	60.5% : 39.5%
Age group (Outcome):	35.5%, 42.5%, 22%
Actual result:	(Table V)

Table-I.

the treatment of CSME. Grid laser treatment for CSME is believed to reduce permeability of leaky blood retinal barrier but several reports indicate that photocoagulation itself may induce blood retinal barrier.

In patients with CSME laser treatment is applied to prevent further loss of vision. Because Laser treatment usually does not improve vision once it has decreased due macular edema.<sup>10</sup>

**DISCUSSION**

In recent past number of diabetic patients all over the world has increased that has caused increase incident of diabetic retinopathy. So in patients having diabetic retinopathy, macular edema can cause deterioration in visual acuity during any stage of diabetic retinopathy. The pathogenesis of Diabetic macular edema (DME) is the disruption of inner blood – retinal barrier that is known to be associated with metabolic alteration affecting the retinal pigment epithelium or retinal vascular endothelium. Focal and/or grid laser photocoagulation is being considered as

The recommendation regarding timing of laser treatment is that it should be performed prior to occurrence of visual loss because the risk of visual loss due to macular edema justifies the adverse effect of laser treatment. Numerous studies reveal that treatment of macular edema at early stage before significant loss of vision has better outcome. Photocoagulation studies in CSME such as Olk et al. and the study conducted at multiple centres of UK has shown that laser photocoagulation of maculae has positive outcome in treating macular edema and keeping the vision stable.<sup>11,12</sup>

In our study, Grid laser photocoagulation was performed on all patients who developed clinical significant macular edema in diabetic retinopathy. These includes 200 eyes of diabetic patients with clinical significant macular edema between 25 to 50 years of age. Patients are followed up after 3 months post laser treatment and visual acuity noted and results were 11% improved in visual acuity, 76% having stable in visual acuity and 13% deteriorates in vision.

Lee CM, and Olk RJ have records of 302 eyes of 185 patients with diffuse diabetic macular edema with or without cystoid macular edema. Between the years 1981 and 1990 Lee CM, and Olk RJ treated all such cases with modified grid laser photocoagulation.<sup>13</sup> The result of their study was visual acuity improved in 14.5%, unchanged in 60.9%, and worse in 24.6% after modified Grid Laser treatment. These results showed that in eyes with diffuse diabetic macular edema for assessing long-term visual outcome, modified grid laser photocoagulation is good treatment in maintaining or improving visual acuity. The study conducted by United Kingdom Prospective Diabetes Study (UKPDS) showed that the 40.5% patients noticed decrease in VA and only 3% had significant visual loss even after receiving in spite of laser treatment.

Some studies also reported the adverse effects of laser photocoagulation that include scotomas, field constriction, decrease in dark adaptation, development of choroidal neovascularization and persistence of macular edema. So when laser is deemed necessary, the patient should be informed of the risks and benefits of the procedures.

As an adjunct to laser coagulation some latest modes of treatment for diabetic macular edema consist of intraocular steroids, antivascular endothelial growth factor and protein kinase c-beta inhibition. A study conducted by Michael SI et al compared long-term visual outcome, following intravitreal steroids and photocoagulation, they showed superiority of photocoagulation over the intravitreal steroids.<sup>14</sup>

The guidelines of ETDRS for laser photocoagulation are to use it as first line treatment. Also, good control of other risk metabolic factors like hypertension and hyperlipidemia etc should be the main stay of treatment along with laser at any phase of the disease.

A limitation of the present investigation is the short follow-up, due to which the long-term safety and efficacy of the treatment could not be assessed. The limitation of the study is due to lack of important investigation that was optical coherence tomography (OCT). Because OCT helpful in monitoring and quantifying macular edema.

## CONCLUSION

Macular photocoagulation was found to be an effective method of treatment for CSME among diabetic patients, which has resulted in a positive visual outcome in 87% of the patients (stable and improved vision). Effective control of diabetes, duration of diabetes, and timely treatment are the factors which influence the post-laser visual outcome.

Copyright © 24 Feb, 2016.

## REFERENCES

1. Guan K, Hudson C, Wong T, Kisilevsky M, Nrusimhadevara RK, Lam WC, et al. **Retinal hemodynamic in early macular edema.** *Diabetes* 2006; 55:813-8.
2. Meyer CH. **Current treatment approaches in diabetic macular edema.** *Ophthalmologica* 2007; 221:118-31.
3. Deborah Pavan – Langston – *Manual of Ocular diagnosis and therapy - 4<sup>th</sup> ed.* **Little Brown and Company;** 1996. p. 162-5
4. Yanof M, Duker JS. **Diabetic Retinopathy, Ophthalmology, 2nd ed, Mosby; 2004.** p. 877-85.
5. Early Treatment Diabetic Retinopathy study Research group. **Early Photocoagulation for diabetic retinopathy: ETDRS report number 9.** *Ophthalmology* 1991; 98:766-85.
6. Bloom SM, Brucker AJ. **Laser surgery of the posterior segment, 2nd ed, Lippincott Williams and Wilkins;** 1997. p. 78-99.
7. Early Treatment Diabetic Retinopathy Research group. **Photocoagulation for diabetic macular edema:**



**ETDRS report No 1.** Arch Ophthalmol 1985; 103:1796-806.

8. Dorner M, Pinget M, Brogard JM. **Essential labile diabetes.** MMW Munch Med Wochenschr 2009; 119: 671-4.

9. Henkind P, Hansen RI, Szalay J. Ocular circulation. **Physiology of the human eye and visual system.** Harper & Row 1979; 98-155.

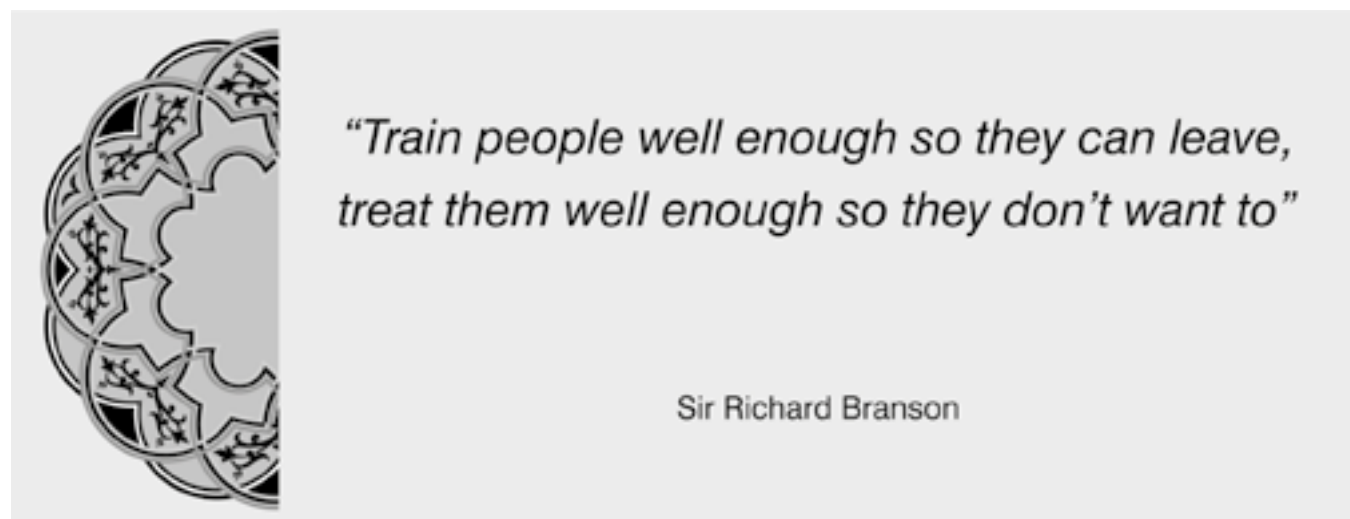
10. Bloom SM, Brucker AJ. **Laser surgery of the posterior segment, 2nd ed,** Lippincott Williams and Wilkins; 1997. p. 78-99. 8.

11. Olk RJ. **Modified grid argon laser photocoagulation for diffuse diabetic macular edema.** Ophthalmology 1986; 93:938-50.

12. The British multicenter study. Townsend C, Bailey J, Kohner E. **Xenon arc Photocoagulation for the treatment of diabetic maculopathy: Interim report of a multicentre controlled clinical study.** Br J Ophthalmol 1980; 64:385-91.

13. Lee CM, Olk RJ. **Modified grid laser photocoagulation for diffuse diabetic macular edema, long term visual results.** Ophthalmology 1991; 98: 1594-602.

14. Michael SI, Allison R, Edwards, Roy W, Beck, Neil M, Bressler. **A randomized trial comparing intravitreal triamcinolone acetonide and focal / grid photocoagulation for diabetic macular edema.** Ophthalmology 2008; 115:



**AUTHORSHIP AND CONTRIBUTION DECLARATION**

Sr. #	Author-s Full Name	Contribution to the paper	Author=s Signature
1	Dr. Muhmmad Jameel Shahid	Concept & data collection	
2	Dr. Faheem Ahmad	Concept & design, Critical expertise & writing, final approval	
3	Dr. Muhammad Asif	Concept & data collection	
4	Muhmmad Nabeel Sultan	Help in data collection	