



# CHOLEDOCHOLITHIASIS; FREQUENCY OF CHOLEDUCHOLETHIASIS AND EVALUATION OF PRIMARY CLOSURE OF COMMON BILE DUCT AFTER OPEN EXPLORATION AS A TREATMENT MODALITY IN ITS MANAGEMENT

Dr. Shabab Hussain<sup>1</sup>, Dr. Viqar Aslam<sup>2</sup>, Dr. Sajjad Muhammad Khan<sup>3</sup>, Dr. Waqar Alam Jan<sup>4</sup>

1. Registrar,  
Department of General Surgery,  
Lady Reading Hospital, Peshawar
2. Assistant Professor,  
Department of General Surgery,  
Lady Reading Hospital, Peshawar
3. Professor,  
Department of General Surgery,  
Lady Reading Hospital, Peshawar
4. Associate Professor,  
Department of General Surgery,  
Lady Reading Hospital, Peshawar

#### Correspondence Address:

Dr. Shabab Hussain,  
Registrar, Department of General  
Surgery,  
Lady Reading Hospital, Peshawar  
rashidmalik\_62@hotmail.com

#### Article received on:

24/08/2015

#### Accepted for publication:

22/01/2016

#### Received after proof reading:

10/03/2016

**ABSTRACT... Objectives:** To determine the frequency of choleducholethiasis in patients with symptomatic gall stone disease and evaluation of primary closure of common bile duct without T-Tube placement after open exploration as a treatment modality in its management. **Study Design:** Prospective (descriptive) study. **Setting:** Surgical Unit of Postgraduate Medical Institute, Lady Reading Hospital, Peshawar. **Period:** One year from 15-03-2013 to 15-03-2014. **Subjects and methods:** Total Of 206 patients of symptomatic gallstones disease were included in the study to find out frequency of choledcholithias and patients with common bile duct (CBD) stones were subjected to open choledochotomy and primary choledochorrhaphy, and follow up of patients was done to find out any post operative complication. **Results:** A total of 206 patients underwent open cholecystectomy during the study period. The age of the patients ranged from 17 to 70 years with mean of  $44.24 \pm 1.23$  years. Most of the patients with symptomatic gall stones disease were female in the age range of 41-50 years. Frequency of choleducholethiasis was 24 out of 206 constituting 11.65%. Among the patients with CBD stones 4 were male constituting 16.6% and 20 were female that is 83.33% with male to female ratio of 1:4 respectively. Mean hospital stay of the patients in which open CBD exploration and primary repair was performed was  $7.25 \pm 1.45$  days. Complications developed in only 4 patients constituting 16.66%. Complications were wound infection in 2 (8.33%) patients, intra-abdominal pus collection in 1 (4.16%) patient and bile leak in 1 (4.16%). One patient lost from follow up. In none of the patients retained CBD stones and stricture observed. **Conclusions:** There should be low threshold for suspecting CBD stones in cases of symptomatic gallbladder stones disease.

**Key words:** CBDexploration (Choleduchotomy), PrimaryCBDrepair (Choledochorrhaphy), T-Tube, CBD stones (choleducholethiasis)

Article Citation: Hussain S, Aslam V, Khan SM, Jan WA. Choledocholithiasis; Frequency of choleducholethiasis and evaluation of primary closure of common bile duct after open exploration as a treatment modality in its management. Professional Med J 2016;23(3):257-261. DOI: 10.17957/TPMJ/16.3066

## INTRODUCTION

Gallbladder stones disease is a common with a prevalence of 10-15% in the USA and about 16% in Pakistan.<sup>1,2</sup> Patients mostly remain asymptomatic but symptoms appear when any complication develops.<sup>3</sup> Choleducholethiasis that is presence of stones in CBD is one of the complications of symptomatic gall stones disease. About 8 to 18% of patients with gallbladder stones disease also have CBD stones that's why CBD stones are most commonly suspected in this scenario.<sup>4,5</sup> The CBD stones are dealt with two treatment options, either these are management endoscopically through ERCP and by open or laparoscopic surgery.<sup>5</sup>

Traditionally, common bile duct is closed over

T-tube after stones extraction because it is thought that T- tube placement causes decompression of CBD and improves healing of the repair moreover T-tube and its tract can be used later on for visualization of retained stones if any and their removal. But this method of treatment is not devoid of complications, these include bacteremia, dislodgement of tube, obstruction and or fracture of tube, leakage of bile after removal of the tube. Patient may have to carry it for several weeks before removal. All of these lead to prolong length of hospital stay.<sup>6-10</sup> Currently, primary closure of CBD has been described in literature to overcome these adverse consequences of T-tube.<sup>11-14</sup> and it is now becoming an attractive option for the surgeon.

This study was design to find out the magnitude of problem that is frequency of choledocholithiasis in symptomatic gall stones disease patients and to evaluate the outcome of primary repair of CBD in terms of hospital stay and post operative complications.

## PATIENTS AND METHODS

This study was conducted at Surgical B Unit of Postgraduate Medical Institute, Lady Reading Hospital, Peshawar, for one year, from 15-03-2013 to 15-03-2014. A written consent was taken from all patients included in the study. Twenty four patients having choledocholithiasis suggested by ultrasound, or the presence of stones in the duct palpated per operatively were included in the study. Patients with pancreatitis, cholangitis or malignancy and primary CBD stones were excluded from the study. All patients included in the study had undergone preoperative investigations including complete blood count (CBC), Renal function test (RFT), Liver function test (LFT), Chest X-ray, ECH, Coagulation Profile before surgery. All the patients were admitted in the ward and those who were jaundiced received vitamin K injections and i/v fluids and antibiotics therapy before surgery. After admission and thorough work up these patients were put on elective list for surgery. And written informed consent was taken for the procedure and anesthesia. All patients were given antibiotic 1 hour before induction of anaesthesia. Abdominal explorations were performed through Kocher's incision. Following cholecystectomy, CBD was opened through a supra-duodenal vertical incision between stay sutures after kocherization of duodenum and palpation of CBD. Stones were taken out and saline flushing followed to ensure patency. After that the patients CBD was primarily closed with interrupted Vicryl 3/0. At the end of procedure before wound closure nelaton drain was placed in subhepatic space in every case. Patients were closely monitored post operatively and follow up was done with 2 weeks 1, 3 and 6 months interval after discharge for any complication to develop and duration of hospital stay was also recorded. Ultrasound and liver function test and MRCP were performed after surgery when needed.. Data was

recorded on predesigned proforma and were analysed using SPSS-16.

## RESULTS

Total Of 206 patients of symptomatic gallstones disease were included in the study to find out frequency of choledocholithias among these patient and those patients with CBD stones were subjected to open choledochotomy and primary choledochorrhaphy. The age of the patients ranged from 17 to 70 years with mean of  $44.24 \pm 1.23$  years. Most of the patients with symptomatic gall stones disease were female in the age range of 41-50 years followed by age range of 51-60 years. Frequency of choledocholithiasis was 24 out of 206 constituting 11.65%. Among these, 32 (15.5%) were males and 174 (84.5%) were females with male to female ratio of 1:4 respectively (Table-I).

Mean hospital stay of the patients in which open CBD exploration was performed was  $7.25 \pm 1.45$  days and range of 5 to 10 days. Most of the patients showed uneventful recovery complications developed in only 4 patients constituting 16.66%. except for one of the patients who developed right subphrenic collection of bile whose hospital stay was prolong upto 10 days but get stabled as subhepatic drain was kept there for relatively longer time and one other patient who developed subphrenic abscess diagnosed 2weeks after surgery during follow up period managed with surgical exploration and drainage followed by appropriate antibiotics therapy, rest of the complications were minor because of the fact that they were managed conservatively for example there were 2 cases of superficial wound infection. One patient lost to follow up (Table-II).

## DISCUSSIONS

A considerable proportion of patients having symptomatic cholelithiasis also have stones in common bile duct. In this study the frequency of choledocholithiasis is 11.65% which corresponds to the literature.<sup>4,5</sup>

Variable	No.	%
<b>Age (years)</b>		
11 – 20	3	1.5
21 – 30	32	15.5
31 – 40	50	24.3
41 – 50	61	29.6
51 – 60	45	21.8
61 – 70	15	7.3
<b>Gender</b>		
Male	32	15.5
Female	174	84.5

**Table-I. Frequency and percentage of age and genders**

Complication	No.	%
Bile leak	1	4.2
Wound infection	2	8.4
Intra-abdominal pus collection	1	4.2
Retained stones	-	-
Stricture bile duct	-	-

**Table-II. Frequency of complications (n = 24)**

Although this is the era of minimally invasive surgery, so the current standard treatment modality for managing cholelithiasis and choledocholithiasis is either laparoscopic cholecystectomy followed by ERCP and vice versa or laparoscopic CBD exploration where facilities and expertise are available. This minimally invasive treatment modality is not possible to practice in most centers where equipments, trained endoscopists and trained laparoscopic surgeons are not available.<sup>6</sup> Because of these limitations even in this modern era the trend is towards open surgical intervention that is open choledochotomy.

Conventionally after CBD exploration T tube is placed after bile duct exploration and the logic behind this technique is that it allows spasm or edema of sphincter to settle after the trauma of the exploration and T-tube drainage has been used to prevent bile stasis, decompress the biliary tree, and minimize the risk of bile leakage moreover it also provides an easy percutaneous access for cholangiography and extraction of retained

stones.<sup>15</sup>

However studies<sup>16-22</sup> are available in literature that now favor choledochotomy and primary choledochorrhaphy instead of conventional T tube placement method in order avoid its associated complications. Our study showed no major morbidity and no mortality after primary repair of common bile duct after supraduodenal choledochotomy followed by its closure without placement of T tube. Moreover, with this technique duration of hospital stay was short. Mean hospital stay of the patients in our study was 7.25±SD 1.45 days which is comparable to other studies.<sup>6,8,23</sup> over all complications rate in our study is 16.66% that falls within the range mentioned by different studies.<sup>24,25</sup> In the patients in which T-Tube placed hospital stay is prolong as well as rate of complications is high.<sup>16-21</sup>

In this study one of the patients who developed right subphrenic collection of bile whose hospital stay was prolong upto 10 days but get stabled as subhepatic drain was kept there for relatively longer time and one other patient who developed Subphrenic abscess diagnosed 2weeks after surgery during follow up period managed with surgical exploration and drainage followed by appropriate antibiotics therapy , rest of the complications were minor because of the fact that they were managed conservatively for example there were 2 cases of superficial wound infection these findings are comparable to those mentioned by other studies.<sup>6,8,26</sup> The complication rate is quite high in patients in which conventional T-tube technique is done, according to one study the complications rate as high as 28.6%.<sup>24</sup>

**CONCLUSION**

There should be low threshold for suspecting CBD stones in cases of symptomatic gallbladder stones disease. Moreover primary CBD repair without T-Tube placement after open CBD exploration can be considered as an attractive and cost effective alternative treatment modality in management of such cases in our setup where facilities and expertise are still limited as for as minimally invasive treatment options are

concerned.

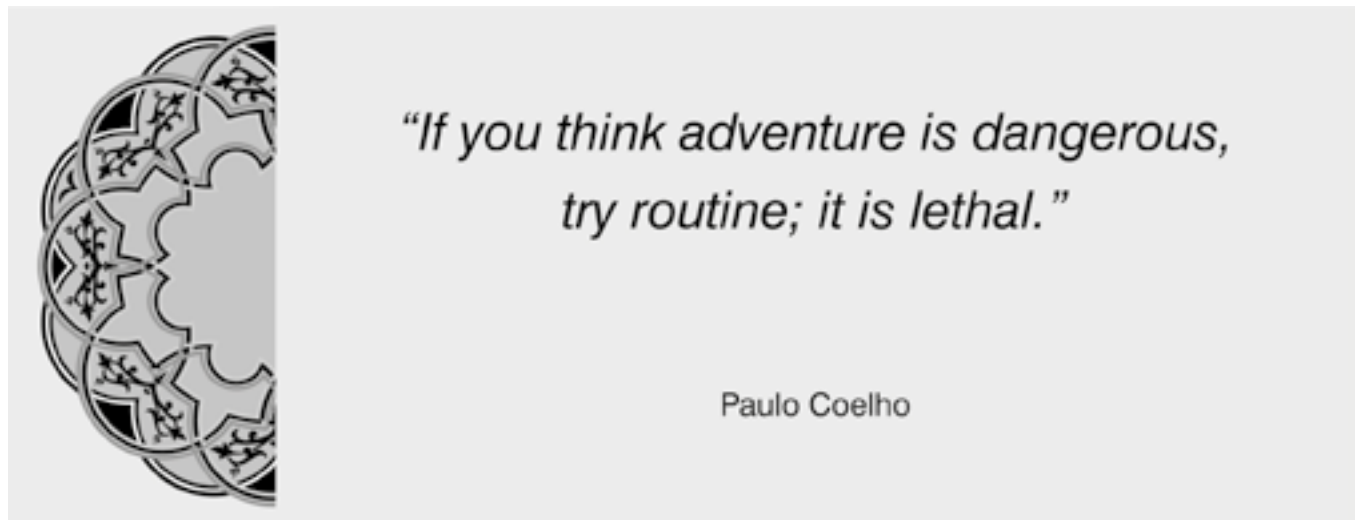
Copyright© 22 Jan, 2016.

## REFERENCES

1. Schirmer BD, Winters XL, Edlich RF. **Cholelithiasis and cholecystitis.** J Longterm Eff Med Implants 2005; 15(3):329-38.
2. Alam SN, Rehman S, Raza SM, Manzir SM. **Audit of general surgical unit: need for self evaluation.** Pak J Surg 2007; 23(2):141-4.
3. Rosing DK, De Virgilio C, Yaghoubian A. **Early Cholecystectomy for mild to moderate gallstone pancreatitis shortens hospital stay.** J Am Coll Surg 2007; 205(6):762-6.
4. Ko C, Lee S. **Role of ERCP in gallstone disease.** Gastrointestinal Endoscopy. 2002; 56(6):165-9
5. Perez G, Escalona A, Jarufe N, Ibáñez L, Viviani P, García C, et al. **Prospective randomized study of T-tube versus biliary stent for common bile duct decompression after open choledochotomy.** World J Surg 2005; 29:869-72.
6. Ahmed I, Pradhan C, Beckingham IJ, Brooks AJ, Rowlands BJ, Lobo DN. **Is a T-tube necessary after common bile duct exploration?** World J Surg 2008; 32:1485-8.
7. Alhamdani A, Mahmud S, Jameel M, Baker A. **Primary closure of choledochotomy after emergency laparoscopic common bile duct exploration.** Surg Endosc 2011; 22:2190-5.
8. Ambreen M, Shaikh AR, Jamal A, Qureishi JN, Dalwani AG, Memon MM. **Primary closure versus t-tube drainage after open choledochotomy.** Asian J Surg 2009; 32:21-5.
9. Boerma D, Schwartz MP. **Gallstone disease. management of common bile-duct stones and associated gallbladder stones: surgical aspects.** Best Pract Res Clin Gastroenterol 2009; 20:1103-16.
10. Cuschieri A, Lezoche E, Mornino M, Croce E, Lacy A, Tooulo J, et al. **Multicenter prospective randomized trial comparing two stage vs single-stage management of patients with gallstone disease and ductal calculi.** Surg Endosc 2009; 13(10):952.
11. Thornton JK. **Observation on additional cases illustrating hepatic surgery.** Lancet 1891; 137:763-4.
12. Halstead WS. **Contributions to surgery of the bile passages, especially of the common bile duct.** Bull John Hopkins Hosp 1900; 106:1-11.
13. Gurusamy KS, Samraj K. **Primary closure versus T-tube drainage after laparoscopic common bile duct exploration.** Cochrane Database Syst Rev 2010; CD005641
14. Isla AM, Griniatsos J, Karvounis E, Arbuckle JD. **Advantages of laparoscopic stented choledochorrhaphy over T-tube placement.** Br J Surg 2009; 91(7):862-6.
15. Hoque et al. **Choledocholithotomy without T tube drainage: our initial experience.** Med Coll Journ 2013; 12(2):41-4.
16. Seale AK, Ledet WP. **Primary common bile duct closure.** Arch Surg 1999; 134:22-4.
17. Collin PG, Redwood C, Wynne-Jones J. **Common bile duct without intra ductal drainage following choledochotomy.** Br J Surg. 1960; 47:661-66711.
18. Sawyers JL, Herrington JL, Edwards WH. **Primary closure of the CBD.** Am J Surg 1965; 09:107-12.
19. Collin PG. **Further experience with common bile duct suture without intra ductal drainage following choledochotomy.** Br J Surg 1967; 54:854-6.
20. Keighley MBR, Burdon DW, Baddeley RM, et al. **Complication of supraduodenal choledochotomy: a comparison of three methods of management.** Br J Surg 1976; 63:754-8.
21. Vassilakis JS, Chattopadhyay DK, Irvin TT, Duthie HL. **Primary closure of common bile duct after elective choledochotomy.** J R Coll Surg Edinb. 1979; 24:156-8.
22. Mirizzi PL. **Primary suture of the common bile duct in choledocholithiasis.** Arch Surg 1942; 44: 44-54.
23. Saeed N, Nasir MT, Khan MI, Channa GA. **Choledochorrhaphy (primary repair) versus t-tube drainage after open choledochotomy.** J Ayub Med Coll Abbottabad 2012; 24(1):18-20.
24. Leida Z, Ping B, Shuguang W, Yu H. **A randomized comparison of primary closure and T-tube drainage of the common bile duct after laparoscopic choledochotomy.** Surg Endosc 2008; 22:1595-600.
25. Haider J, Aziz A, Khan LUZ, Alam SN. **Primary closure of common bile duct after open choledochotomy.** J Surg Pak 2009; 14 (4) :173-5.
26. Ha JP, Tang CN, Siu WT, Chau CH, Li MK. **Primary closure versus T-tube drainage after laparoscopic choledochotomy for common bile duct stones.** Epatogastroenterology 2004; 51:1605-8.

27, Zhang LD, Bie P, Chen P, Wang SG, Ma KS, Dong JH. **Primary duct closure versus T-tube drainage**

**following laparoscopic choledochotomy.** Zhonghua Wai Ke Za Zhi 2004;42:520-3.



**AUTHORSHIP AND CONTRIBUTION DECLARATION**

Sr. #	Author-s Full Name	Contribution to the paper	Author=s Signature
1	Dr. Shabab Hussain	Writing of manuscript and compiling results	
2	Dr. Viqar Aslam	Data collection & writing of manuscript	
3	Dr. Sajjad M. Khan	Stitistical analysis & guidance in writing the manuscript	
4	Dr. Waqar Alam Jan	Designing of project & guidance in writing the manuscript	