



1. Department of Pathology, Pathologist and Senior Lecturer Muhimbili University of Health and Allied Science, Tanzania.
2. Department of Pathology, First People's Hospital of Jining City.
3. Department of Paediatric, First People's Hospital of Jining City China.

**Correspondence Address:**

Dr. Henry Mwakyoma  
Pathologist and Senior Lecturer  
Muhimbili University of Health and Allied Science,  
P.O. Box 65001, Dar es Salaam,  
Tanzania,  
hwmwakyoma@yahoo.com  
xianlongquan@126.com

**Article received on:**

00/00/2014

**Accepted for publication:**

18/11/2014

**Received after proof reading:**

21/02/2015

## MALIGNANT TERATOID MEDULLOEPITHELIOMA OF RIGHT EYE IN A CHILD; A CASE REPORT FROM FIRST PEOPLE'S HOSPITAL OF JINING CITY, CHINA

Dr. Henry Mwakyoma<sup>1</sup>, Dr. Xiang Longquan<sup>2</sup>, Dr. Cong Shan<sup>3</sup>

**ABSTRACT... Objective:** Medulloepithelioma is a rare intraocular tumor, and it is also one of the most common congenital tumors originated in the epithelium of ciliary body. Since its onset hidden, it is often discovered after the invalid treatment of glaucoma, cataracts or strabismus. This paper will show you one case of malignant teratoid medulloepithelioma and combine with relevant literature review.

**Key words:** Ciliary body; Malignant teratoid medulloepithelioma - Last light preception lens dislocation, Vitreous opacities

**Article Citation:** Mwakyoma H, Longquan X, Shan C. Malignant teratoid medulloepithelioma of right eye in a child; a case report from first people's hospital of jining city, china. Professional Med J 2015;22(2):273-275.

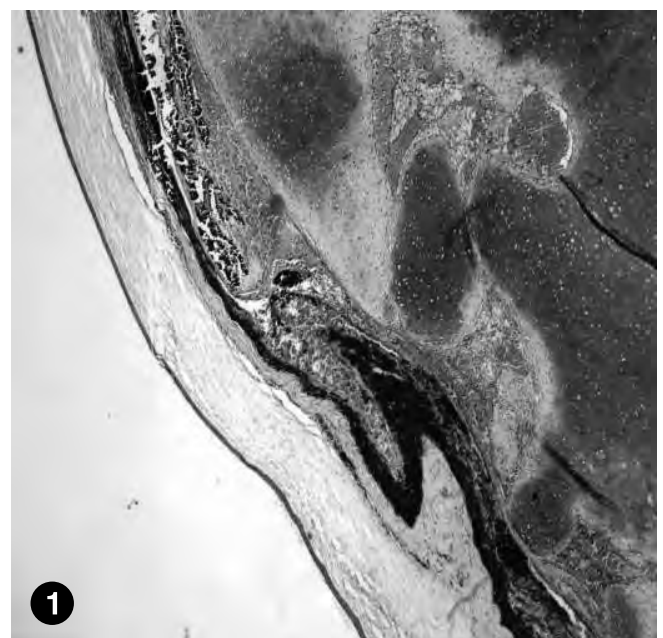
The patient is an 11-year-old girl. Because of the decreased visual acuity and proptosis with swelling of the right eye half a year, she was admitted to hospital on March 5, 2014. During the admission, the patient hadn't the symptoms such as headache, eye pain, and photophobia. The systemic examination was normal, but specialist right eye examination showed no light perception, eyelid swelling, conjunctival hyperemia, lens dislocation, Vitreous opacities and invisible fundus. Ultrasound examination showed the right eye had a solid mass with calcifications. The left eye examination was normal. The clinical diagnosis was retinoblastoma. Right eye enucleation was performed under general anesthesia. Pathological examination showed the whole eyeball was brown and oval. The size of the eyeball was about 3cm × 3cm × 2.5cm. The cut section was grey, and part of it was necrotic. There was a gray nodule which size was about 2cm × 1.5cm × 1cm. The normal structure of the eyeball had disappeared, without attachment of optic nerve.

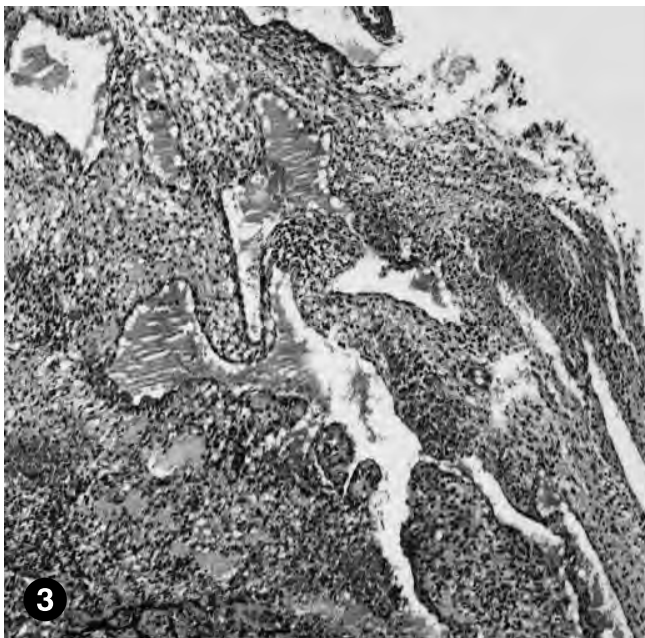
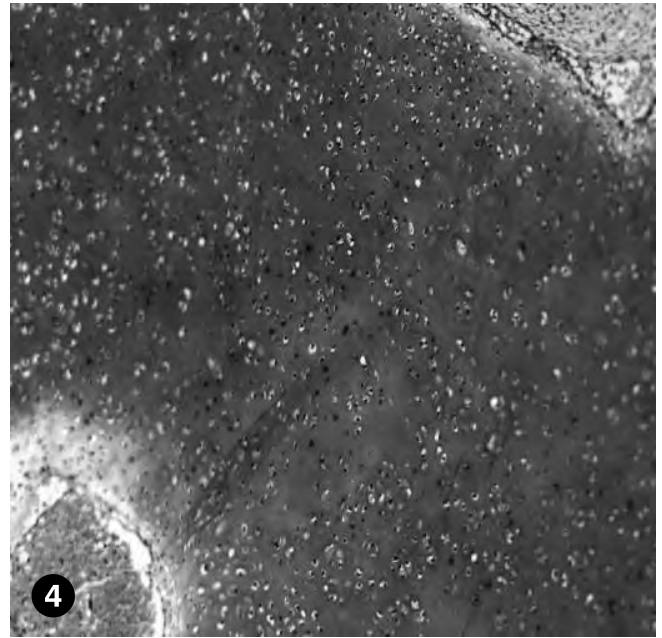
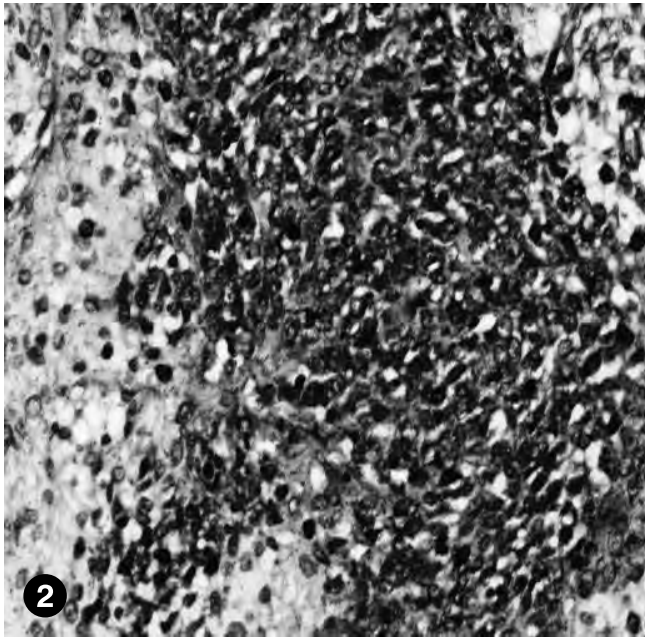
Microscopically the tumor was confined to the eyeball (Figure 1), and the tumor cells were composed of dense patches of immature undifferentiated cells (Figure2). The cells were

oval or columnar arranged in finger-like, duct-like structures (Figure 3), in addition there was a large number of mature cartilage tissue within the tumor tissue (Figure 4).

Pathological diagnosis: (Right eye) Malignant teratoid medulloepithelioma

**Figure-1. The tumor is confined to the eyeball.**





**Figure-2.** The tumor cells are composed of dense patches of immature undifferentiated cells.

**Figure-3.** Oval or columnar cells are arranged in finger-like, duct-like structures in the local area.

**Figure-4.** A large number of mature cartilage tissue is present in the tumor tissue.

## DISCUSSION

Medulloepithelioma is also called retinal embryonic tumor. It is a congenital tumor which originated in primitive embryonic optic cup inner medullary epithelial cells or non-pigmented ciliary epithelial cells<sup>1</sup>. It is extremely rare in infants and children, especially from 6 months to 5 years old. This tumor often involves unilateral eyes, no family history and genetic characteristics, and the incidence is similar for men and women. It is often originated in the ciliary epithelium<sup>2</sup>, but it also may originate in the retina and optic nerve<sup>3</sup>. Based on morphology, structure and growth characteristics, it is divided into benign medulloepithelioma, malignant medulloepithelioma and teratoid medulloepithelioma<sup>4</sup>.

### Pathological features

The macroscopy shows the boundary of the tumor is often clear, and the cut section is usually gray. The texture is crisp or slightly harder, and it may be accompanied by hemorrhage, necrosis and cystic degeneration.

### The microscopic features

(1) Benign medulloepithelioma: The tumor tissue is composed of cord-like structure by a single or multi-columnar or spindle cells and the cord-like structure was tortuous and

roundabout forming various shapes and sizes of lumen or cyst structure.

- (2) Malignant medulloepithelioma: Tumor cells are made up of a large number of dense immature undifferentiated cells, presenting sheets, or tubular, papillary, adenoid, rosettes like arrangement. Tumor cells have obvious atypia and many pathological mitoses, hemorrhage, necrosis, or involving the surrounding tissue.
- (3) Teratoid medulloepithelioma: In addition to the components of medulloepithelioma, one or more tissues which don't belong to the intrinsic intraocular tissue can be found, and the most common is the cartilage and striated muscle tissue. Most studies show that medulloepithelioma may be derived from stem cells<sup>5</sup>, because it can often shows different directions of differentiation and maturation, along astrocytes, ependymal cells, neurons, oligodendrocytes differentiation<sup>6</sup>, and it can also differentiate into cartilage, bone and skeletal muscle tissue<sup>7</sup>. Medulloepithelioma is rare, and it lacks long-term follow-up data. The literature reports that the surgical treatment of benign medulloepithelioma is effective, but malignant medulloepithelioma progresses faster, easy to recurrence and metastasis to the intracranial brain tissue. There are a lot of mature cartilages and sheets of undifferentiated immature cells in this tumor, so in our case we came to a conclusion of the diagnosis of malignant teratoid medulloepithelioma. However the

tumor was confined to the eye, without involving the surrounding tissue, and we didn't find optic nerve in the sample submitted, so the optic nerve involvement could not be ascertained. Close follow-up of the patient is recommended.

Copyright© 18 Nov, 2014.

## REFERENCES

1. Vajaranant TS, Mafee MF, Kapur R, et al. **Medulloepithelioma of the ciliary body and optic nerve: clinicopathologic, CT, and MR imaging features [J]**. Neuroimaging Clin N Am, 2005, 15(1): 69-83.
2. Yang Zhenzhong, Xie Qun. **Ciliary medulloepithelioma one case report [J]**. Chinese Journal of Pathology, 2002, 31: 521.
3. Font RL, Rishi K. **Diffuse retinal involvement in malignant nonteratoid medulloepithelioma of ciliary body in an adult [J]**. Arch Ophthalmol, 2005, 123: 1136-1138.
4. Xiao-Li Hu, Xue-Wen Wang, Song Lanyun, et al. **Orbital malignant medulloepithelioma one case report [J]**. Chinese Journal of Pathology, 2006, 35 (8): 504-505.
5. Hui Yunzhong, main translator. Rosai J, main editor. **Ackerman Surgical Pathology [M]**. Education Press, Liaoning, 1999, 2315-2316.
6. Deck JH. **Cerebral medulloepithelioma with maturation into ependymal cells and ganglion cells [J]**. J Neuropathol Exp Neurol, 1969, 28: 442-454.
7. Auer RN, Becker LE. **Cerebral medulloepithelioma with bone, cartilage and striated muscle. Light microscopic and immunohistochemical study [J]**. J Neuropathol Neurol, 1983, 42:256-267.

## CORRECTION

The amendment of the Professional Vol:21,No.03 (Prof-2473) on page 580 is as under;

### INCORRECT

**Dr. Saima Perveen**  
MBBS, MCPS, FCPS  
Associate Professor of Obs/Gynae  
Mohtarma Benazir Bhutto Hospital,  
Mirpur

### CORRECT

**Dr. Saima Perveen, MCPS, FCPS**  
Assistant Professor  
Gynae & Obs.  
Mohtarma Benazir Bhutto Shaheed Medical College  
Mirpur AJK

## CORRECTION

The amendment of the Professional Vol:22,No.01 (Prof-2591) on page 40 is as under;

### INCORRECT

**Dr. Saima Perveen**  
Armed Forces Institute of  
Radiology and Imaging (AFIRI)  
Rawalpindi Cantt.

### CORRECT

**Dr. Saima Perveen, MCPS, FCPS**  
Assistant Professor  
Gynae & Obs.  
Mohtarma Benazir Bhutto Shaheed Medical College  
Mirpur AJK