



## CONGENITAL POUCH COLON; OUR EXPERIENCE WITH SINGLE STAGE PROCEDURE.

1. MBBS, FCPS (General Surgery),  
FCPS (Pediatric Surgery)  
Assistant Professor  
Department of Pediatric Surgery  
Quaid-e-Azam Medical College/  
Bahawal Victoria Hospital,  
Bahawalpur.
2. MBBS  
Medical Officer  
Department of Pediatric Surgery  
Quaid-e-Azam Medical College/  
Bahawal Victoria hospital,  
Bahawalpur.
3. MBBS, MS  
Associate Professor  
Department of Pediatric Surgery  
Quaid-e-Azam Medical College/  
Bahawal Victoria hospital,  
Bahawalpur.

**Correspondence Address:**  
Dr. Muhammad Ramzan Bhutta  
House No. 23-B, Medical Colony,  
Quaid-e-Azam Medical College/  
Bahawal Victoria hospital, Bahawalpur.  
mramzanbhutta@gmail.com

**Article received on:**

29/09/2018

**Accepted for publication:**

25/12/2018

**Received after proof reading:**

25/06/2019

**Muhammad Ramzan Bhutta<sup>1</sup>, Faseeh Abid<sup>2</sup>, Abid Hameed Sheikh<sup>3</sup>**

**ABSTRACT...** To review our experience with single-stage management of congenital pouch colon (CPC) as regard to complications and continence. **Study Design:** retrospective study. **Setting:** Paediatric Surgery Bahawal Victoria Hospital Bahawalpur. **Period:** July 2011 to July 2017. **Materials and Methods:** All the patients of anorectal agenesis that were diagnosed as case of CPC on history, clinical examination and supported by x-ray (invertogram) admitted during the study period 2011 to 2017 were included. A total of 35 cases were managed with single stage procedure. All the patients were assessed for complications, mortality, and continence with Kelly's scoring. **Results:** We managed 35 patients with average age 2.8 days ranging from 12 hours to 5 days. 29 (82.8%) were males and 6 (17.2%) females. In 31 (85.7%) patients, the association was with high anorectal agenesis, whereas, in 4(14.3%) patients with low ARM. At operation, type I CPC was in 4 (11.4%) patients, type II in 9 (25.7%), type III in 5 (14.2%) patients, and type IV in 17 (48.5%) patients. There were 2 (5.7%) deaths in our study; the reason was associated anomaly and sepsis. Wound infection was seen in 5 (14.2%) pts. anal stenosis in 2 pts. and mucosal prolapse in 1 pt. Continence was evaluated by the Kelly's scoring and it showed good results. **Conclusions:** The results of SSP for various types of CPC are good as regards continence and cosmetics, with decrease rate of morbidity and mortality and hence it is recommended.

**Key words:** Anorectal Agensis, Kelly's scoring, ARM, Pouch Colon, SSP.

**Article Citation:** Bhutta MR, Abid F, Sheikh AH. Congenital pouch colon; our experience with single stage procedure. Professional Med J 2019; 26(7):1187-1191.  
**DOI:** 10.29309/TPMJ/2019.26.07.13

### INTRODUCTION

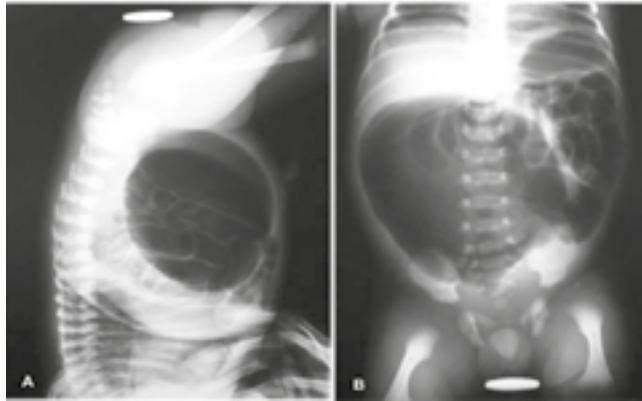
Congenital pouch colon is an anomaly in which a part of normal colon or whole of its length is replaced by a pouch like structure resulting in small size of total colon and this pouch has a fistulous communication with the urogenital system. It is associated with anorectal agencies and is also described as congenital short colon and pouch colon syndrome.<sup>1,2,3,4,5</sup> These cases are more frequently presented in the north and central part of India.<sup>2</sup> Some patients of congenital pouch colon have also been reported from other parts of the world.<sup>6</sup> Congenital pouch colon is more frequent in India, Pakistan, Bangladesh and Nepal. Few reports also came from China, Japan, Sweden, United Kingdom and other parts of the world.<sup>7</sup> The CPC is almost equally prevalent in Pakistan but due to lack of published literature it could not be retrieved in spite of extensive search. Three-staged procedure is considered

the standard procedure for the management of CPC.<sup>1,3</sup> We managed different types of CPC patients with single stage procedure. We are presenting our experience with a brief review of literature.

### MATERIALS AND METHODS

This is a retrospective study. It was conducted at Pediatric and neonatal Surgery unit, Bahawal Victoria hospital Bahawalpur between July 2011 to July 2017. The medical record of patients of CPC was reviewed. Mode of presentation, features of clinical examination and investigations performed were assessed. Surgical notes showing operative findings, postoperative notes and the outcome of surgery all were reviewed. The invertogram/cross-table prone lateral view was the choice of the investigation during the initial admission to investigate the cases of ARM. CPC was suspected (pre-operatively) with characteristic radiological

findings [Figure-1] A and B.



All the patients were assessed for other associated congenital anomalies and baseline investigations like complete blood count, serum electrolytes, echocardiography was performed.

After informed consent exploratory laparotomy through left lumbar incision was performed, the type of pouch colon assessed according to the classification of Narasimharao et al, and SSP was performed.

The SSP includes initial posterior sagittal approach and placement of nelaton tube at the site of anus identified with the nerve stimulator, then the position of patient was changed for abdominal approach which comprises of exploratory laparotomy, identification of the fistula, its division and ligation, then the pouch is excised after ligation of its vascularity and primary abdominoperineal pull-through and anoplasty with pulled down colon/ileum /abdomino-PSARP is done.

Evaluation of complications, mortality, was done in each patient and Kelly’s scoring was used for assessment of continence.

CPC was classified into 4 types as per Rao et al classification;<sup>8</sup>

Type I: ileum opens directly into the dilated pouch; normal colon is absent. Type II: The small bowel (ileum) opens into a small part of caecum which opens into the dilated pouch (absent normal colon. Type III: consists of significant length of normal large bowel (colon)

b/w the ileum and the dilated colonic pouch. Type IV: consists of almost normal colon except the terminal part (sigmoid and rectum) which is converted into a dilated pouch.

**RESULTS**

We managed 35 patients of CPC during the study period. The average age of the patients when they presented to hospital was 2.8 days ranging from 12 hours to 5 days. 29 (82.8%) were males and 6 (17.2%) females. In 31 (88.5%) patients, the association of congenital pouch colon was with high anorectal agenesis, whereas, in 4 (11.4%) patients the association was with low anorectal malformation (Table-I). The most common clinical presentation was moderate to severe abdominal distension with imperforate anus. Abdominal radiographs helped in preoperative diagnosis. At operation, type 1 congenital pouch colon was found in 4 (11.4%) patients, type II in 9 (25.7%), type III in 5 (14.2%) patients, and type IV CPC in 17 (48.5%) patients (Table-II). In all patients, fistula identified, ligated and pouch excised, followed by primary abdominoperineal pull-through and anoplasty / abdomino-PSARP. There were 2 (5.7%) deaths in our study; the reason was associated anomaly and sepsis. All the patients were examined regularly till discharge from hospital and looked for any complications like wound infection, anal retraction, prolapse.

Type of ARM	No. of Patients	Percentage
High variety	31	88.5
Low variety	4	11.4

**Table-I. The association with type of ARM**

Type of CPC	No. of Patients	Percentage
1	4	11.4
2	9	25.7
3	5	14.2
4	17	48.5

**Table-II. Frequency of different types of CPC**

Wound infection was seen in 5 (14.2%) pts. and it was managed by cleansing and washing with saline and pyodine solution. 2 pts had anal stenosis because of infrequent dilatation and delay in follow up (noncompliance by parents), they were managed by counselling of the parents and then dilatation program and 1 pt. with anal

mucosal prolapse managed by surgical mucosal excision and later on dilatation program (Table-III). Later all the patients were followed up and Kelly's scoring was used for assessment of continence and showed good results. In all the male patients the pouch was opening in posterior wall of urinary bladder through a fistulous communication, whereas in female patients the communication was with the cloaca in 3, and with vestibule in 2. Most of the patients have associated anomalies and were mainly from urogenital and gastrointestinal systems. Duplex appendix was noted in 3 patients, Malrotation in 3 patients, horse shoe kidney 1, hydro ureter in 2, esophageal atresia with TEF in 1 and cardiac defect in 1 patient.

Complications	No. of patients	Percentage
Wound Infection	5	14.2
Anal Stenosis	2	5.7
Mucosal Prolapse	1	2.8

**Table-III. Frequency of complications**

**DISCUSSION**

In 1912, Spriggs described a CPC like condition, in a London hospital museum specimen, in which left half of the colon and rectum was absent, but its name was not given at that time.<sup>1,2</sup> In 1959 from Canada a similar pouch-like dilation of shortened colon associated with high ARM was described by Trusler et al. but at that time also it was not given any name.<sup>1,28</sup> Six cases of CPC associated with imperforate anus were reported by Singh and Pathak from India in 1972 and the name of this anomaly was suggested by them as "Short Colon".<sup>9</sup> 1984 the name "Pouch Colon Syndrome" was given by Narsimha Rao et al. and he also classified this condition on anatomical basis which is now accepted widely.<sup>1,2,10</sup> Different series reported 2% to 18% incidence of CPC among all the cases of ARM and 10 to 26% among the high ARM and almost all the series reported male preponderance.<sup>3,5,6</sup> Even high incidence (55.8%) of CPC with high ARM has been reported from Udaipur, Rajasthan, India.<sup>11</sup> We managed 35 CPC cases during the study period and it comprised of 8.71% (35 out of 403) of all ARM and we also observed male preponderance as 4.8:1. The incidence of 6.73%

with the male to female ratio of 3.2:1 was also reported in another study.<sup>2</sup> Almost all the series on CPC are reported from India; Lucknow, Delhi, Chandigarh, Varanasi, Bhopal, Kashmir, Udaipur, and Rohtak.<sup>1,16,13,14</sup> Recently, a study from Saudi Arabia also reported seven patients of congenital pouch colon.<sup>15</sup> Plain abdominal X-ray, either erect or inverted, which shows a single air fluid level in a large loop of gut that involves more than half of the total width of the abdomen is almost diagnostic of CPC and one can diagnose pouch colon in about 75-90% of the cases.<sup>4,5,14,16</sup> The diagnosis of congenital pouch colon can be made very easily by plain x-ray abdomen (erect and invertogram) showing a large loop of bowel filled with air and meconium, that occupies more than half of the abdominal cavity, is confirmatory of CPC in a patient with ARM.<sup>17</sup> In our series after clinical examination CPC was diagnosed on typical features of abdominal radiographs (invertogram) that were performed in all the patients. Three-staged procedure is considered the standard for the management of congenital pouch colon which consist of:

- A. 1<sup>st</sup> stage: It includes stoma formation (a) colostomy/ or ileostomy either end or loop with ligation of fistula or without ligation. (b) ligation of fistula, pouch excision and end stoma, and (c) fistula ligation, dilated colon used for coloplasty and end colostomy.
- B. 2<sup>nd</sup> stage: It includes Definitive operation either of one (a) pouch excision and APPT of colon or ileum (b) pouch excision with PSARP, (c) ligation of fistula, coloplasty and APPT of coloplasty colon/PSARP and proximal loop ileostomy.
- C. Colostomy/ileostomy closure

People are also doing CPC in two stages i.e.

Initial operative procedure/1<sup>st</sup> stage either of one (a) proximal colostomy/ileostomy either loop or end with fistula ligation or without ligation. (b) ligation of fistula, pouch excisin and end stoma and (c) ligation of fistula, coloplasty and end stoma.

Definitive operation/2<sup>nd</sup> stage operation : It includes either of one without covering stoma

(a) pouch excision and APPT of colon, (b) pouch excision with PSARP (c) ligation of fistula, coloplasty and APPT of coloplasty colon/psarp, (d) pouch excision and APPT of ileum.

We performed single-staged procedures in 35 cases and the details are provided in "Results" section.

In our study wound infection occurred in 5 patients and all were managed conservatively by wound wash with normal saline and povidone solution. 2 pts had anal stenosis because of infrequent dilatation and delay in follow up (noncompliance by parents), they were managed by parents counselling and then dilatation program and 1 pt. with anal mucosal prolapse managed by surgical mucosal excision and later on dilatation program. Continence checked by Kelly's scoring system showed good results which were comparable with international studies. Another study showed that better continence and cosmetic results are obtained with single stage procedure with low morbidity and mortality.<sup>4</sup>

Ideally in Single stage procedure there is ligation of fistula, pouch excision, and then primary abdomino-perineal-PSARP /pull through of bowel and anoplasty is done.<sup>18</sup> Recently, good results are being reported with single stage procedure though initially they were not considered safe.<sup>2,18</sup>

## CONCLUSION

CPC is rare disease associated with ARM being more common in the Asian subcontinent than in the western world. Continence and cosmetic results are good with Primary single-stage procedure for different types of congenital pouch colon. Morbidity and mortality are also low and hence is recommended.


Copyright© 25 Dec, 2018.

## REFERENCES

1. Wakhlu AK PA. **Congenital pouch colon**. In: Textbook of Neonatal Surgery. New Delhi: Modern Publishers; 2000. p. 240–8.
2. Gupta D, Sharma S. **Congenital pouch colon - Then and now**. J Indian Assoc Pediatr Surg. 2007 Jan 1;12(1):5–12.
3. Ghritlaharey R, Budhwani K, Shrivastava D, Gupta G, Kushwaha A, Chanchlani R, et al. **Experience with 40 cases of congenital pouch colon**. J Indian Assoc Pediatr Surg. 2007 Jan 1;12(1):13–6.
4. Gangopadhyay AN, Shilpa S, Vittal Mohan T, Chooramani Gopal S. **Single-stage management of all pouch colon (anorectal malformation) in newborns**. J Pediatr Surg. 2018 Apr 19;40(7):1151–5.
5. Wakhlu A, Wakhlu AK. **Technique and long-term results of coloplasty for congenital short colon**. Pediatr Surg Int. 2009 Jan;25(1):47–52.
6. Bhat NA. **Congenital pouch colon syndrome: A report of 17 cases**. Ann Saudi Med. 2007;27(2):79–83.
7. Hasina K. **Congenital pouch colon**. J Paediatr Surg Bangladesh. 2013;4(1):24–7.
8. Trusler GA, Mestel AL, Stephen CA. **Colon malformation with imperforate anus**. Surgery. 1959 Feb;45(2):328–34.
9. Singh S, Pathak IC. **Short colon associated with imperforate anus**. Surgery. 1972 May;71(5):781–6.
10. Narsimha Rao KL, Yadav K, Mitra SK PI. **Congenital short colon with imperforate anus (pouch colon syndrome)**. Ann Paediatr Surg. 1984;1:159–67.
11. Saxena AK, Mathur P. **Classification of congenital pouch colon based on anatomic morphology**. Int J Colorectal Dis. 2008 Jun;23(6):635–9.
12. Gharpure V. **Our experience in congenital pouch colon**. J Indian Assoc Pediatr Surg. 2007;12(1):22–4.
13. Chadha R, Bagga D, Malhotra CJ, Mohta A, Dhar A, Kumar A. **The embryology and management of congenital pouch colon associated with anorectal agenesis**. J Pediatr Surg. 1994 Mar;29(3):439–46.
14. Budhiraja S, Pandit SK, Rattan KN. **A report of 27 cases of congenital short colon with an imperforate anus: So-called "pouch colon syndrome"**. Trop Doct. 1997 Oct;27(4):217–20.
15. Pal K. **Congenital pouch colon from Al-Ahsa region of Saudi Arabia - A changing demography?** J Kuwait Med Assoc. 2009;41(1):39–42.
16. Mathur P, Saxena AK, Bajaj M, Chandra T, Sharma NC, Simlot A, et al. **Role of plain abdominal radiographs in predicting type of congenital pouch colon**. Pediatr Radiol. 2010 Oct;40(10):1603–8.
17. Mirza B, Ijaz L, Sheikh A. **Congenital pouch colon**. Ann Saudi Med. 2011;31(5):546–7.

18. Mirza B, Ahmad S, Sheikh A. **Congenital pouch colon: A preliminary report from pakistan.** J neonatal Surg. 2012;1(3):37.

**AUTHORSHIP AND CONTRIBUTION DECLARATION**

Sr. #	Author-s Full Name	Contribution to the paper	Author=s Signature
1	M. Ramzan Bhutta	1st Author	
2	Faseeh Abid	2nd Author	
3	Abid Hameed Sheikh	3rd Author	