

ORIGINAL ARTICLE

Role of HRCT temporal bone in diagnosis of chronic suppurative otitis media in correlation with intraoperative findings.

Iqra Aslam¹, Nadeem Ibrahim², Naima Rauf³, Amer Hayyat⁴, Jahanzeb Javed⁵

ABSTRACT... Objective: To evaluate the role of high-resolution computed tomography (HRCT) of the temporal bone in diagnosing and delineating disease in chronic suppurative otitis media (CSOM) by comparing preoperative HRCT findings. **Study Design:** Prospective Diagnostic Evaluation study. **Setting:** Departments of Radiology and Otolaryngology, CMH, Gujranwala, Pakistan. **Period:** January 2024 to December 2024. **Methods:** A total of 57 patients aged 1–60 years, clinically diagnosed with CSOM and scheduled for mastoid surgery were analyzed. Patients underwent preoperative HRCT of the temporal bone. Radiological findings were documented and compared with intraoperative observations. Sensitivity, specificity, positive predictive value (PPV), negative predictive value (NPV), and overall accuracy were calculated for each anatomical structure. **Results:** In a total of 57 patients, the median age was 26.00 years (IQR: 17.50-41.50). There were 38 (66.7%) males and 19 (33.3%) females. HRCT demonstrated 100% sensitivity and specificity for incus, malleus, scutum, stapes suprastructure erosion, sigmoid plate erosion, and jugular bulb dehiscence. Bony external auditory canal erosion showed 80% sensitivity and 100% specificity. Facial canal dehiscence had 50% sensitivity and 100% specificity. Mastoid cortex erosion had high sensitivity (100%) but lower PPV (66.7%), while tegmen erosion had 100% sensitivity and 98.2% specificity. Overall diagnostic concordance was excellent (Cohen's Kappa=0.935, $p<0.001$). The McNemar-Bowker test showed no significant discordance between HRCT and surgical findings ($p=0.223$). **Conclusion:** HRCT of the temporal bone demonstrated excellent diagnostic accuracy and agreement with surgical findings in evaluating structural changes associated with CSOM.

Key words: Accuracy, Computed Tomography, Intraoperative, Malleus, Surgery.

Article Citation: Aslam I, Ibrahim N, Rauf N, Hayyat A, Javed J. Role of HRCT temporal bone in diagnosis of chronic suppurative otitis media in correlation with intraoperative findings. Professional Med J 2026; 33(06):1031-1035. <https://doi.org/10.29309/TPMJ/2026.33.06.10324>

INTRODUCTION

Chronic suppurative otitis media (CSOM) affects around 3.8% of the global population, and contributing to chronic hearing loss and morbidity.¹ CSOM is typically classified as “safe” (tubotympanic) or “unsafe” (atticoantral) types.² The unsafe type generally involves a cholesteatoma, and can progressively erode middle ear ossicles and surrounding bony structures, and may lead to serious complications.³

High-resolution computed tomography (HRCT) of the temporal bone is an indispensable tool in the preoperative evaluation of CSOM, especially for cholesteatomatous disease.^{4,5} HRCT can provide crucial details about middle ear and mastoid anatomy, highlighting soft-tissue masses and erosion of critical structures that may not be apparent in the general clinical exam. Routine pre-surgery temporal

bone CT scanning is advocated when cholesteatoma or complications are suspected.⁶ Contemporary literature affirms the value of preoperative HRCT in cholesteatoma surgery as modern HRCT is a useful tool prior to mastoid surgery.⁷ Recent analyses continue to demonstrate that HRCT findings correlate closely with operative findings in CSOM.⁸⁻¹⁰

The exact diagnostic performance of HRCT or various pathological features of CSOM warrants careful evaluation. This study aims to assess the role of HRCT of the temporal bone in diagnosing and delineating disease in CSOM. This study prospectively evaluates patients with CSOM, assessing key pathological features on HRCT in correlation with surgical observations.

1. MBBS, Post-graduate Resident Radiology, Combine Military Hospital, Gujranwala, Pakistan.
2. MBBS, FCPS (Radiology), Consultant Radiologist Radiology, Combined Military Hospital, Gujranwala, Pakistan.
3. MBBS, Post-graduate Resident Radiology, Combined Military Hospital, Gujranwala, Pakistan.
4. MBBS, FCPS, Consultant Radiologist Radiology, AFIU Rawalpindi, Pakistan.
5. MBBS, Post-graduate Resident of Radiology, Combine Military Hospital, Gujranwala, Pakistan.

Correspondence Address:

Dr. Iqra Aslam
Department of Radiology, Combine Military Hospital, Gujranwala, Pakistan.
iqra_aslam776@yahoo.com

Article received on:

04/12/2025

Accepted for publication:

10/02/2026



METHODS

This prospective observational, diagnostic evaluation study was performed at the Department of Radiology, and Otolaryngology at Combined Military Hospital (CMH), Gujranwala, Pakistan, during January 2024 to December 2024. Approval was obtained from the Institutional Review Board (ERB No. 18-2023, dated: 15-08-2023). A sample size of 57 was calculated using OpenEPI online sample size calculator, considering the prevalence of CSOM as 3.8%¹, with 95% confidence level and 5% margin of error. Inclusion criteria were patients aged 1-60 years, diagnosed clinically with CSOM and scheduled for surgical exploration or mastoidectomy. Exclusion criteria were previous otologic surgeries, history of temporal bone trauma, presence of congenital anomalies of the temporal bone, known malignancy involving the ear or temporal region, or patients unwilling to undergo surgical intervention or participation in the study. Informed written consent was sought from participants, or parents / legal guardians.

All patients underwent preoperative HRCT of the temporal bone. Scans were performed with a high-resolution bone algorithm, using 0.5–1 mm axial and coronal sections spanning the temporal bone from the mastoid tip through the tegmen. No contrast was administered. Key HRCT findings including soft tissue opacification in middle ear/mastoid, presence of an atticointral mass suggestive of cholesteatoma, erosion of the ossicles, erosion of the scutum, erosion of the cochleariform process or otic capsule, dehiscence or erosion of the facial nerve canal, erosion of the tegmen tympani, or erosion of the sigmoid sinus plate were systematically recorded by a radiologist blinded to the eventual surgical findings. The radiologist also noted any anatomical variants like a low-lying dura or high jugular bulb, to inform surgical caution. Patients subsequently underwent tympanomastoid surgery (canal wall up or down mastoidectomy as appropriate, with tympanoplasty). The surgeon was aware of the CT findings prior to surgery, but intraoperative findings were recorded independently. During surgery, the status of the ossicles was documented. The presence of cholesteatoma versus granulation tissue was confirmed via surgical observation and histopathology of excised tissue when in doubt.

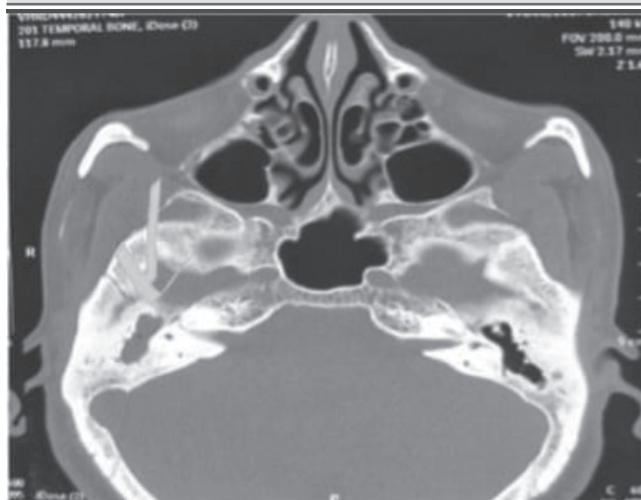Data were analyzed using IBM-SPSS Statistics, version 26.0. Sensitivity, specificity, positive predictive value (PPV), negative predictive value (NPV), and diagnostic accuracy were calculated for each anatomical feature evaluated on HRCT, with surgical observations served as the gold standard. Correlation coefficients were determined applying Cohen's Kappa to assess the agreement between radiological findings and surgical outcomes. $P < 0.05$ was considered significant.

RESULTS

In a total of 57 patients, the median age was 26.00 years (IQR: 17.50-41.50), ranging between 11 to 53 years. There were 38 (66.7%) males and 19 (33.3%) females. Figure-1 is showing axial image of cholesteatoma in right middle ear cavity with widening of aditus and antrum and ossicular erosion. Figure-2 is showing coronal image of right tegmen erosion. Figure-3 is showing axial image of right lateral semicircular canal and facial canal erosion.

FIGURE-1

Cholesteatoma in right middle ear cavity



HRCT demonstrated 100% sensitivity and specificity for incus erosion, jugular bulb dehiscence, malleus erosion, scutum erosion, sigmoid plate erosion, and stapes suprastructure erosion, achieving perfect diagnostic accuracy (100%) for these parameters. For bony external auditory canal (EAC) erosion, sensitivity was 80.0%, specificity was 100%, PPV was 100%, NPV was 98.1%, and diagnostic accuracy was 98.2%. In the case of facial canal

dehiscence, sensitivity was 50.0%, specificity 100%, PPV 100%, NPV 96.4%, with an overall diagnostic accuracy of 96.5%. Mastoid cortex erosion exhibited high sensitivity (100%) and NPV (100%), but a lower PPV (66.7%) due to false positives, resulting in an overall diagnostic accuracy of 96.5% (Table-I).

FIGURE-2

Coronal image showing right tegmen erosion

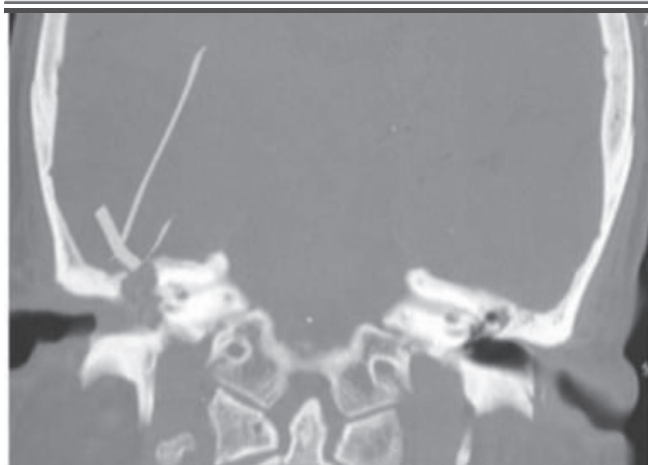
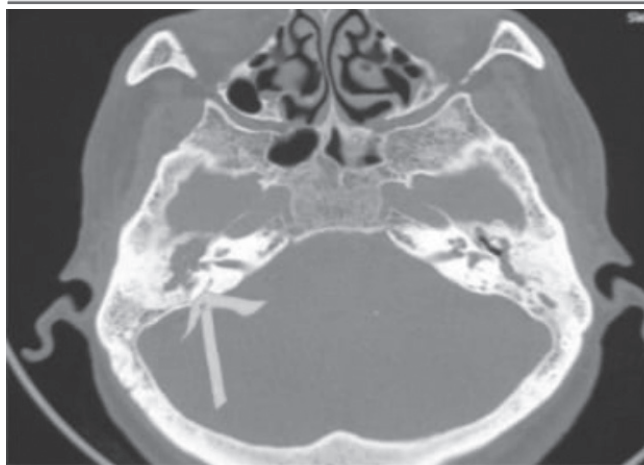

FIGURE-3

Right lateral semicircular canal and facial canal erosion



DISCUSSION

This study found HRCT to high diagnostic accuracy in identifying key anatomical erosions and pathological changes. Shah et al.¹¹, evaluating 100 patients also found HRCT to be a consistent and reliable tool.

TABLE-I

Diagnostic utility of HRCT temporal bone in CSOM taking surgical findings as reference

Findings	HRCT findings (%)	Surgical findings (%)	Sensitivity (%)	Specificity (%)	PPV (%)	NPV (%)	Accuracy (%)
Bony external auditory canal cholesteatoma erosion	4 (7.0%)	5 (8.8%)	80	100	100	98.1	98.2
Facial canal dehiscence	2 (3.5%)	4 (7.0%)	50	100	100	96.4	96.5
Incus erosion	2 (3.5%)	2 (3.5%)	100	100	100	100	100
Jugular bulb dehiscence	6 (10.5%)	6 (10.5%)	100	100	100	100	100
Malleus erosion	5 (8.8%)	5 (8.8%)	100	100	100	100	100
Mastoid cortex erosion	6 (10.5%)	4 (7.0%)	100	96.2	66.7	100	96.5
Scutum erosion	22 (38.6%)	22 (38.6%)	100	100	100	100	100
Sigmoid plate erosion	4 (7.0%)	4 (7.0%)	100	100	100	100	100
Stapes suprastructure erosion	3 (5.3%)	3 (5.3%)	100	100	100	100	100
Tegmen erosion	3 (5.3%)	2 (3.5%)	100	98.2	66.7	100	98.2

Agreement between HRCT and surgical findings revealed no significant discordance after applying McNemar test (p=0.223). The extent of agreement between HRCT and surgical findings was analyzed and showed Cohen's Kappa as 0.935 (standard error 0.036), with p<0.001.

Facial canal dehiscence showed a relatively lower sensitivity of 50%, despite 100% specificity, which may reflect anatomical subtleties or radiologic limitations in detecting partial dehiscence, unlike Shah et al., who reported uniformly high sensitivity across different features.¹¹ Another study documented sensitivity and specificity range between 86.4-100%, and 93.3-100%, respectively, for tegmen erosion, facial nerve canal erosion, and sigmoid sinus plate erosion.¹² Jadia et al.¹³, reported high sensitivity and specificity for ossicular erosion, including 100% sensitivity for malleus and incus involvement. Jadia et al.¹³, also emphasized HRCT as a roadmap for surgery in atticointral disease. Regional data have also shown 100% sensitivity for cholesteatoma and malleus erosion, and 91% sensitivity for incus erosion.¹⁴ These findings are consistent with the current results, where malleus and incus erosions were detected with 100% sensitivity and specificity. Challenges in evaluating stapes erosion have been reported previously, whereas the present study recorded 100% sensitivity and specificity for stapes suprastructure erosion.¹⁴ Khan et al.¹⁵, documented high diagnostic yield of HRCT, with sensitivity and specificity values of 71.5%, and 88.5% respectively for malleus, 86.3%, and 95% for incus, and 53.1%, and 64.7% for stapes erosion.

This research demonstrated higher sensitivity (100%) and kappa (0.935), suggesting better imaging resolution, more consistent radiological reporting, or rigorous intraoperative verification in a controlled surgical setting. Regional data emphasized high sensitivity and specificity for malleus and scutum erosion, and proposed HRCT as effective approach in the similar study population.¹⁶ Agarwal and others.¹⁷, found relatively lower correlation values for facial canal dehiscence, and dural plate status, and this aligns with a relatively lower sensitivity (50%) for facial canal involvement observed in this study, underlining a common limitation in visualizing certain fine bony structures.

This study supports the utilization of HRCT as an essential tool in the diagnostic workup and preoperative mapping of CSOM, as has been described previously.¹⁸⁻²⁰ The accurate detection of ossicular erosion, scutum involvement, and sinus plate dehiscence can influence the choice of

surgical approach and help anticipate intraoperative challenges.²¹ The identification of potentially hazardous variants such as high jugular bulb or low-lying dura can also inform safer dissection strategies.²²

Relatively modest sample size and a single study center limits the generalizability. As the surgeons were aware of the HRCT findings preoperatively, a degree of confirmation bias cannot be excluded. The absence of interobserver variability assessment for radiologic interpretation limits generalizability.

CONCLUSION

HRCT of the temporal bone demonstrated excellent diagnostic accuracy and agreement with surgical findings in evaluating structural changes associated with CSOM. HRCT seems effective for detecting ossicular erosion, scutum defects, and sinus plate involvement.

CONFLICT OF INTEREST

The authors declare no conflict of interest.

SOURCE OF FUNDING

This research received no specific grant from any funding agency in the public, commercial, or not-for-profit sectors.

Copyright© 10 Feb, 2026.

REFERENCES

1. Onifade A, Katolo HW, Mookerjee S, Bhutta MF. **Epidemiology of chronic suppurative otitis media: Systematic review to estimate global prevalence.** J Epidemiol Glob Health 2025; 15(1):55.
2. Bhalla AS, Singh A, Jana M. **Chronically discharging ears: Evaluation with high resolution computed tomography.** Pol J Radiol. 2017; 82:478-89.
3. Popescu C, Văruț RM, Puticiu M, Belghiru VI, Banicioiu M, Rotaru LT, et al. **Comprehensive management of cholesteatoma in otitis media: Diagnostic challenges, imaging advances, and surgical outcome.** J Clin Med. 2024; 13(22):6791.
4. Stefanescu EH, Balica NC, Motoi SB, Grigorita L, Georgescu M, Iovanescu G. **High-Resolution computed tomography in middle ear cholesteatoma: How much do we need it?** Medicina (Kaunas). 2023; 59(10):1712.
5. Monali M, Ashok TP, Craig MB, Dnyanesh AB. **The role of high-resolution computerized tomography as a diagnostic tool in the evaluation and planning of management of patients with chronic otitis media.** Muller J Med Sci Res. 2021; 12(1):6-12.

6. Rogha M, Hashemi SM, Mokhtarinejad F, Eshaghian A, Dadgostar A. **Comparison of preoperative temporal bone CT with intraoperative findings in patients with cholesteatoma.** Iran J Otorhinolaryngol. 2014; 26(74):7-12.
7. Rai T. **Radiological study of the temporal bone in chronic otitis media: Prospective study of 50 cases.** India J Otolaryngol. 2014; 20(2):48-55.
8. Abdelaziz AA. **The role of preoperative computed tomography of temporal bone in atticotomy as a new tool for determining the approach.** Indian J Otolaryngol Head Neck Surg. 2019; 71(Suppl 2):1272-5.
9. Aljehani M, Alhussini R. **The correlation between preoperative findings of high-resolution computed tomography (HRCT) and intraoperative findings of chronic otitis media (COM).** Clin Med Insights Ear Nose Throat. 2019; 12:1179550619870471.
10. Rogha M, Hashemi SM, Mokhtarinejad F, Eshaghian A, Dadgostar A. **Comparison of preoperative temporal bone CT with intraoperative findings in patients with cholesteatoma.** Iran J Otorhinolaryngol. 2014; 26(74):7-12.
11. Shah CK, Gupta S, Gupta DP, Prajapati BJ, Prajapati V. **Role of high resolution computed tomography of temporal bone in patients with cholesteatoma, in a Tertiary Care Health Center.** India J Otolaryngol Head Neck Surg. 2022; 74(Suppl 1):681-5.
12. Singh R, Rai R, Singh P, Sethi S, Ahluwalia APS, Choudhary G. **High-resolution computed tomography (HRCT) in pediatric and adult patients with unsafe chronic suppurative otitis media (CSOM) and its surgical correlation.** J Family Med Prim Care. 2020; 9(8):4067-73.
13. Jadia S, Qureshi S, Sharma S, Mishra K. **Correlation of Preoperative 'HRCT Temporal Bone' Findings with 'Surgical Findings' in Unsafe CSOM.** India J Otolaryngol Head Neck Surg. 2021; 73(1):33-40.
14. Kumar SR, Vudumula VP, Maghiben M. **Role of HRCT temporal bone in diagnosis of chronic suppurative otitis media in correlation with intraoperative findings.** Medico Legal Update. 2020; 20(4):2361-6.
15. Khan MI, Patel S, Dasgupta K. **Is HRCT Temporal Bone Necessary in All Cases of Active Squamous Chronic Otitis Media?** India J Otolaryngol Head Neck Surg. 2019; 71(Suppl 2):1212-16.
16. Kumari A, Alam N, Kumar S. **High-Resolution computed tomography of the temporal bone in chronic otitis media: An observational study at a Tertiary Care Center in Jharkhand, India.** Cureus. 2023; 15(8):42813.
17. Agarwal R, Pradhananga R, Das DH, Poudel S. **Correlation of pre-operative temporal bone CT scan findings with intraoperative findings in chronic otitis media: Squamous Type.** India J Otolaryngol Head Neck Surg. 2022; 74(Suppl 1):33-42.
18. Pramod V, Raghuraj U, Shrikrishna U. **Correlation of intraoperative and HRCT of temporal bone findings in CSOM.** J Otorhinolaryngol Allied Sci. 2020; 3(1):10-7.
19. Prakash, MD, Tarannum A. **Role of high resolution computed tomography of temporal bone in preoperative evaluation of chronic suppurative otitis media.** Int J Otorhinolaryngol Head Neck Surg. 2018; 4(5):1287-92.
20. Lakshmikanth HKA, Kumar SR, Raju V. **Role of high-resolution computed tomography temporal bone in evaluation of patients with Chronic Suppurative Otitis Media (CSOM).** Int J Curr Res Rev. 2021; 3(20):28-35.
21. Pareek DK, Gehlot R, Chaturvedy K, Chaudhary R, Viram, Raghunath, et al. **Diagnostic Accuracy of High-resolution Computed Tomography (HRCT) Temporal Bone in the Evaluation of Chronic Suppurative Otitis Media.** Int J Med Biomed Stud. 2020; 6(4):42-57.
22. Ouattassi N, Maaroufi M, Slaoui H, Taha BA, Aarsalane Z, Alami MNE, et al. **Middle ear-acquired cholesteatoma diagnosis based on CT scan image mining using supervised machine learning models.** Beni-Suef Univ J Basic Appl Sci. 2024; 13:78.

AUTHORSHIP AND CONTRIBUTION DECLARATION

1	Iqra Aslam: Data collection.
2	Nadeem Ibrahim: Concept, design.
3	Naima Rauf: Drafting.
4	Amer Hayyat: Literature review.
5	Jahanzeb Javed: Data analysis.