



# TWIN REVERSED ARTERIAL PERFUSION SEQUENCE (TRAP);

## A CASE REPORT

1. PGR – Year III  
Obs & Gyn Dept.  
Civil Hospital, Bahawalpur
2. MCPS  
Senior Medical Officer  
Obs & Gyn Dept.  
Civil Hospital, Bahawalpur

### Correspondence Address:

Dr. Mubasher Saeed Pansota  
PGR – Year III  
Obs & Gyn Dept.  
Civil Hospital, Bahawalpur  
Mubashersaeed17@gmail.com

### Article received on:

24/09/2016

### Accepted for publication:

01/06/2017

### Received after proof reading:

03/07/2017

## INTRODUCTION

TRAP sequence affects approximately 1 percent of mono chorionic pregnancies with an incidence of 1 in 35000 births. Reversed arterial perfusion is used to describe this condition because blood flow is opposite from the normal blood supply of the fetus. In TRAP sequence, blood enters the abnormal twin (also called the acardiac or acephalic twin) through the umbilical artery (which usually carries blood away from the fetus back to the placenta) and exits through the umbilical vein (which normally carries blood from the placenta to the fetus). The pump twin perfuses deoxygenated blood into the recipient twin. This leads to reduced formation of body tissues resulting in acardiac-acephalous twin. The twin reversed arterial perfusion sequence is one of the forms of twin to twin transfusion syndrome (TTTS).

## CASE REPORT

A G2P1 with previous cesarean delivery referred to Civil Hospital Bahawalpur at 32 weeks of gestation from periphery with the complaints of decreased fetal movements for one day and an USG report showing twin pregnancy. One of the fetuses, fetus A was alive with mild hydrocephalous and the

**Mubasher Saeed Pansota<sup>1</sup>, Muhammad Imran Niaz<sup>2</sup>**

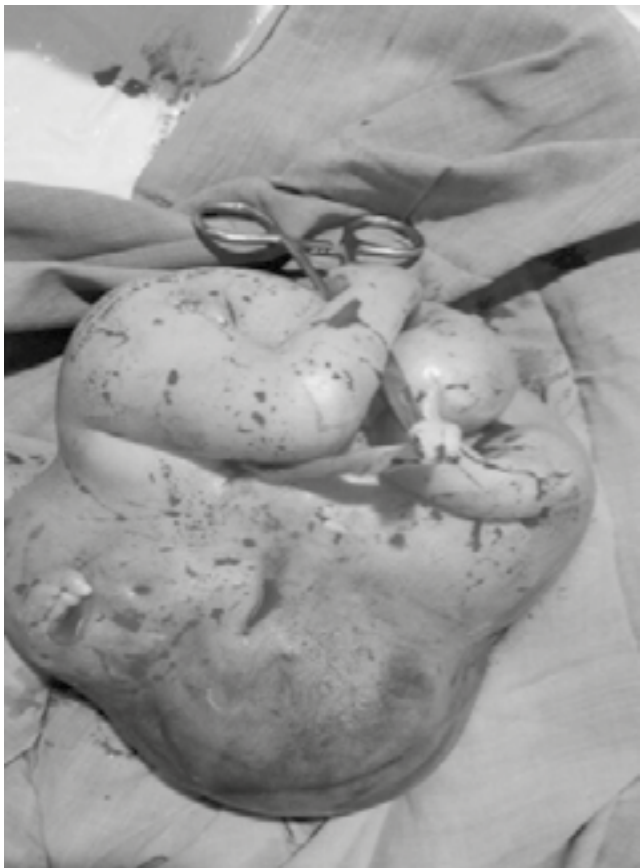**ABSTRACT:** Twin reversed arterial perfusion sequence (TRAP sequence) is a condition that occurs only in identical twins that share a placenta (monochorionic), in which one twin lacking a functioning cardiac system “acardiac monster” receives blood from the normally developing twin called the “pump twin”. This places an enormous demand on the heart putting the pump twin at risk for cardiac failure. Left untreated, the pump twin will die in 50 percent to 75 percent of cases. Here we present the case report of a 20 years old G2P1 at 32 weeks POG with a mono chorionic twin pregnancy. One of the twins was “acardiac acephalous” and the other a “pump twin” with mild hydrocephalous.

**Key words:** Twin reversed arterial perfusion sequence (TRAP), Mono chorionic pregnancies

**Article Citation:** Pansota MS, Niaz MI. Twin reversed arterial perfusion sequence (TRAP); a case report. Professional Med J 2017;24(7):1093-1095.  
**DOI:** 10.17957/TPMJ/17.3705

other fetus B was reported to be dead. No history of cousin marriage, drug intake and infection during early pregnancy. Patient was of average height, weight and a housewife belonging to poor socio-economic class. She had no previous medical and antenatal record available and was an unbooked case. Her vitals were pulse 76/min, BP 100/70, Temp 98 degree F and Resp Rate 16/min. Her P/A examination revealed uterus size of 36 weeks of gestation with multiple fetal parts palpable. Routine investigations were done which showed Hb 7.7 g/dl, Blood group O-Positive, HBs Ag and HCV Ag –ive and RBS 98 mg/dl. RFTs and LFTs were also within normal limits. USG done at Civil Hospital revealed a mono chorionic diamniotic twin pregnancy with fetus A alive, vertex presentation and mildly hydrocephalous. No other structural anomaly was seen in fetus A. While gross anatomical anomaly was seen in fetus B with skull and heart absent. USG findings were consistent with TRAP sequence. Patient remained in gynae ward for three days during which two pints of blood were transfused to build up Hb and two doses of 12 mg intramuscular dexamethasone over a period of 24 hours were given. On fourth admission day, there was spontaneous rupture of membranes and patient

did the complaints of severe lower abdominal pains, there were signs of fetal distress. On P/A, palpable uterine contractions were present. Patient and her attendants were counseled about the whole situation and after proper antibiotics cover emergency cesarean section was performed under general anesthesia. The first twin was a 2.6kg female baby with an APGAR score of 6 and 8, mildly hydrocephalic and no other gross structural abnormality. Baby was seen in the operation theatre by the paediatrician and was shifted to NICU for further management. The second twin was a malformed female with poorly developed lower limb, absent thorax, upper limb, neck and head. It had a well-developed female external genitalia and anus. After operation, patient was shifted to post-operative ward and was discharged on 4<sup>th</sup> post-operative day with a healthy female baby. Patient was advised for a follow up visit after 6 weeks.



## DISCUSSION

TRAP sequence is a rare complication of

monochorionic twinning. It was first described by Gruenwald in 1942. Although the initiating events are unclear, TRAP sequence is thought to result from abnormal communication between the blood vessels in the two fetal circulations as well as a cardiac problem in the recipient twin. The acardiac twin is usually grossly abnormal with structural abnormalities of upper part of the body as seen in our case. The acardiac twin loses direct vascular connection with the placental villi and receives its entire blood supply from the pump twin. Some authorities have reported absence of external genitalia in the acardiac twin. But in our case external genitalia was well developed and both the babies were females. The condition does not appear to run in the families and currently there are no reports of recurrence in the same family. Because of the strain on the pump twin's heart, every case of TRAP should be evaluated by fetal echocardiography. The reversed arterial flow in the acardiac/acephalic twin should be documented using colour flow doppler. It is important to exclude a chromosomal abnormality prior to offering a fetoscopic procedure in TRAP sequence because the incidence of chromosomal abnormality in the pump twin may be as high as 9%. Over half of these pregnancies are complicated by polyhydramnios and 75% by preterm labor.


TRAP sequence requires occlusion and division of the cord due to the risk of cord entanglement. Fetal echocardiography is essential for monitoring the pump twin for signs of decompensation and possible intervention. Selective bipolar cord coagulation and radiofrequency ablation (RFA) procedures are the various treatment options available for mothers carrying twins diagnosed with TRAP sequence. However in our case the baby was saved spontaneously.

Copyright© 01 June, 2017.

## REFERENCES

1. Petersen BL, Broholm H, Skibsted L, Graem N. **Acardiac twin with preserved brain.** Fetal Diagn Ther 2001; 16:231-3.
2. Tsao K, Feldstein VA, Albanese CT, Sandberg PL, Lee H, Harrison MR, et al. **Selective reduction of acardiac twin by radiofrequency ablation.** Am J Obstet Gynecol

- 2002; 187:635-40.
3. Torres BJ, Guzman CaJ, Arjona BJE, Acosta CA, Romanos L. Acardius acephalus. **Description of a case.** An Esp Pediatr 2000; 53:346-9.
  4. Faye-Petersen OM, Heller DS, Joshi VV. **Handbook of Placental Pathology, 2nd edition, London, Taylor and Francis, 2006.**
  5. Blaicher W, Repa C, Schaller A. **Acardiac twin pregnancy: associated with trisomy 2: case report.** Hum Reprod, 2000; 15(2): 474–5.
  6. Sogaard K, Skibsted L, Brocks V. **Acardiac twins: pathophysiology, diagnosis, outcome and treatment.** **Six cases and review of the literature.** Fetal Diagn Therapy. 1999; 14:53–59.
  7. Dhall U, Kayalvizhi I, Magu S. **Acardius Acephalus Monster – A case report.** J Anat Soc India. 2005; 54(1):26-28. Available at <http://medind.nic.in/jae/t05/i1/jaet05i1p26.pdf>.
  8. Rohilla M et al. **Acardiac – Acephalic Twin: A case report of 2 cases & Review of literature.** Medscape J Med. 2008; 10(8):200.
  9. Pandey K et al. **Case report - A rare case of Acardiac Acephalus twin pregnancy.** J Obstet Gynecol India January / February 2010; 60(1):75-76.



*“Wise men learn by other men’s mistakes,  
fools by their own.”*

**Italian Proverb**

#### **AUTHORSHIP AND CONTRIBUTION DECLARATION**

Sr. #	Author-s Full Name	Contribution to the paper	Author=s Signature
1	Dr. Mubasher Saeed Pansota	Main Author	
2	Dr. Muhammad Imran Niaz	Co Author	