

ORIGINAL ARTICLE

## Diagnostic accuracy of magnetic resonance imaging (MRI) in detecting malignant breast lesions keeping histopathology as gold standard.

Zunaira Aftab<sup>1</sup>, Salahuddin Balooch<sup>2</sup>, Mubashir Iqbal<sup>3</sup>, Narmeen Khan<sup>4</sup>, Rida Fatima Baloch<sup>5</sup>, Sanaullah<sup>6</sup>

**ABSTRACT... Objective:** To assess the diagnostic accuracy of magnetic resonance imaging (MRI) in detecting malignant breast lesions, using histopathology as the gold standard. **Study Design:** Cross-sectional study. **Setting:** A Tertiary Care Hospital in Sargodha, Pakistan. **Period:** February 2024, to December, 2024. **Methods:** With a sample size of 256 patients MRI, using dynamic contrast-enhanced MRI (DCE-MRI), was performed to evaluate the morphological and kinetic features of breast lesions. Histopathology results, obtained via fine needle aspiration cytology (FNAC) or biopsy, were used as the gold standard for comparison. **Results:** MRI showed a sensitivity of 93.9%, specificity of 73.5%, and an overall diagnostic accuracy of 89.3%. **Conclusion:** MRI is highly sensitive and accurate for detecting malignant breast lesions but has limitations in specificity, resulting in false positives. It is most effective when used as an adjunct to other imaging techniques and histopathology.

**Key words:** Diagnostic Accuracy, False Negatives (FN), False Positives (FP), Histopathology, Magnetic Resonance Imaging (MRI), Malignant Breast Lesions, True Positives (TP), True Negatives (TN).

**Article Citation:** Aftab Z, Balooch S, Iqbal M, Khan N, Baloch RF, Sanaullah. Diagnostic accuracy of magnetic resonance imaging (MRI) in detecting malignant breast lesions keeping histopathology as gold standard. Professional Med J 2026; 33(05):764-770. <https://doi.org/10.29309/TPMJ/2026.33.05.10168>

### INTRODUCTION

Breast cancer is the most commonly diagnosed malignancy in women worldwide and remains a leading cause of cancer-related mortality. "The global burden of breast cancer is particularly high in developed countries, with an increasing incidence in low- and middle-income nations as well."<sup>1</sup> According to the World Health Organization (WHO), breast cancer accounts for nearly 25% of all cancer cases in women, making it the most prevalent form of cancer worldwide".<sup>2</sup> Among women in Pakistan, breast cancer is the most prevalent malignancy with it being 34.6 percent of the total cancer cases in women. Breast cancer is diagnosed in approximately 90,000 women every year and the number is likely to increase due to the tendency of population to grow and age. Early detection and accurate diagnosis are critical in improving survival rates and reducing mortality, making effective diagnostic tools essential for healthcare providers.<sup>3</sup>

Various diagnostic modalities are employed in the diagnosis of breast cancer including mammography, ultrasound testing and magnetic resonance imaging

(MRI). Mammography is the most prevalent imaging technique in the diagnosis of breast cancer and it is mostly the initial line screening approach.<sup>4</sup> Nevertheless, it may not be effective particularly in women with dense breast tissue because the sensitivity of mammography is lower when there is a dense breast tissue. Consequently, other imaging modes, like MRI, are gaining relevance to the clinical practice. MRI is especially effective in the detection of malignancy in the dense breast common in young women because it gives detailed images of the breast in three dimensions and can distinguish between benign and malignant lesions by the appearance of the vascularity and the composition of tissues.<sup>5</sup>

MRI has several advantages over traditional mammography, including its ability to detect small tumors that may be missed on mammograms and its high sensitivity for detecting malignancies in dense breast tissue. However, MRI's specificity is a subject of debate, with some studies reporting low specificity, leading to false positives.

1. MBBS, FCPS, Resident Radiology, PAF Hospital, Mushaf.  
2. MBBS, FCPS, Associate Professor Consultant Radiologist, PAF Hospital, Mushaf.  
3. MBBS, FCPS  
4. MBBS Student, Foundation University Medical College.  
5. MBBS Student, Sheikh Zayed Medical College, Lahore.  
6. MBBS, FCPS, CMH, Kharian.

**Correspondence Address:**  
Dr. Zunaira Aftab  
Department of Radiology, PAF Hospital, Mushaf.  
[xunairaaftab\\_100@hotmail.com](mailto:xunairaaftab_100@hotmail.com)

**Article received on:**  
29/10/2025  
**Date of revision:**  
16/01/2026  
**Accepted for publication:**  
19/01/2026



This presents a challenge for clinicians, as false positives may result in unnecessary biopsies, increased healthcare costs, and emotional distress for patients. Therefore, the issue of the diagnostic precision of MRI in identifying malignant breast lesion, especially with regard to sensitivity, specificity, positive predictive value (PPV), and negative predictive value (NPV), is of high significance.<sup>6</sup>

Histopathology, considered the gold standard in breast cancer diagnosis, remains the definitive method for diagnosing malignancy. The correlation between MRI findings and histopathological results can provide valuable insights into MRI's diagnostic performance. In this context, a thorough evaluation of MRI's accuracy compared to histopathology is essential for understanding its role in the diagnostic workflow for breast cancer. Previous studies have demonstrated that MRI, particularly dynamic contrast-enhanced MRI (DCE-MRI), can accurately detect malignant lesions by evaluating lesion enhancement patterns, margins, size, and kinetic behavior. Despite its high sensitivity, MRI's relatively low specificity has raised concerns about its overuse and cost-effectiveness.<sup>7</sup>

This study aims to determine how well MRI is able to diagnose malignant breast lesions as compared to the gold standard, that is, histopathology. "By examining the sensitivity, specificity, PPV, NPV, and overall diagnostic accuracy of MRI, this study seeks to determine whether MRI should be recommended as a primary imaging modality for breast cancer detection, particularly in cases where mammography may be inconclusive." The findings from this study will contribute to the growing body of evidence on the effectiveness of MRI in breast cancer diagnosis and may help establish more refined protocols for its clinical use.<sup>8</sup>

## METHODS

This cross-sectional study was conducted at a tertiary care hospital in Sargodha, Pakistan, from February 2024, to December, 2024. Necessary approvals were obtained from the institutional ethical committee (letter number MSF (H)/308/3/1/Trg) before the study was commenced. A total of 256 patients, both male and female, were included in the study. These patients were referred

for breast imaging due to either palpable breast lumps or suspicious mammographic findings. The inclusion criteria included patients who had clinically or radiologically suspicious breast lesions. The patients that had a prior history of breast cancer or undergone chemotherapy or surgery were excluded in the study.<sup>9</sup>

Each patients were scanned with magnetic resonance imaging (MRI) on 1.5 Tesla MRI unit and the major one was dynamic contrast-enhanced MRI (DCE-MRI). MRI was carried out in order to assess the morphological and kinetic characteristics of breast lesions. Lesions were evaluated in terms of patterns of improvement, borders, size and nature of kinetic curves. Following MRI, histopathological analysis of all the patients was conducted through fine needle aspiration cytology (FNAC) or biopsy which was regarded as the gold standard of diagnosing malignancy.<sup>10</sup>

The diagnostic accuracy of MRI was then compared with the outcome of histopathology with an aim of establishing the sensitivity, specificity, the positive predictive value (PPV), the negative predictive value (NPV) and overall diagnostic accuracy of MRI in the detection of malignant lesions in the breast. The data were evaluated using SPSS version 20 and the diagnostic accuracy was evaluated by comparing the results of MRI and histopathological outcome with 2x2 table.<sup>11</sup>

## RESULTS

Age	Frequency	Percentage (%)
18-25	65	25.4
26-35	76	29.7
36-45	74	28.9
46-55	41	16.0
Total	256	100.0

The age distribution of the study participants reveals a varied range of breast cancer diagnoses. The majority of patients fell within the 26-35 years (29.7%) and 36-45 years (28.9%) age groups, collectively comprising 58.6% of the sample. The 18-25 years age group accounted for 25.4%, while the 46-55 years age group represented 16.0%.

This indicates that the majority of breast lesions detected by MRI and confirmed by histopathology occurred in women aged 25-45, a range commonly associated with both early and mid-adulthood. This demographic may be particularly susceptible to malignant lesions due to various risk factors, including hormonal changes and family history. The relatively low representation of patients over 45 years may reflect a lower prevalence of breast cancer in this age group in the studied population or could suggest underrepresentation of older individuals seeking early diagnostic screening. The diverse age range enhances the generalizability of the study findings.<sup>12</sup>

FIGURE-1

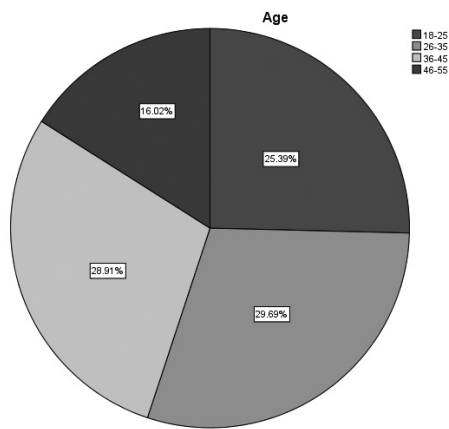
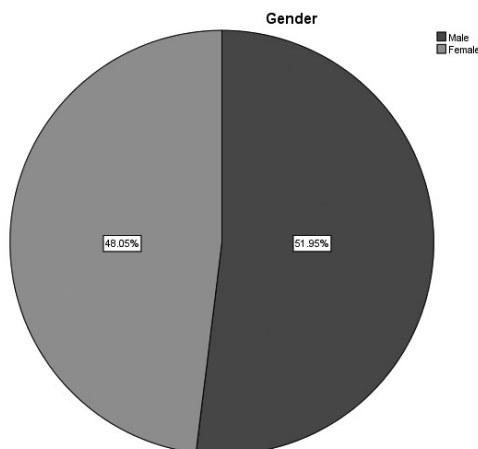


TABLE-II

Gender	Frequency	Percentage (%)
Male	133	52.0
Female	123	48.0
Total	256	100.0

FIGURE-2

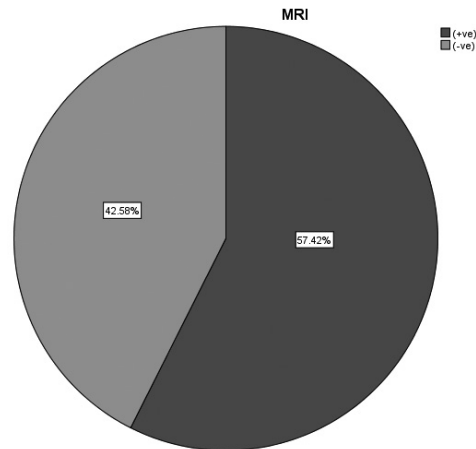


The gender distribution of the study participants shows a nearly equal representation of male and female patients. Males comprised 52.0% (133) of the total sample, while females made up 48.0% (123). Although breast cancer is predominantly a female disease, the inclusion of male patients is significant, as male breast cancer, though rare, accounts for approximately 1% of all breast cancer cases. The balanced gender distribution in this study allows for a comprehensive analysis of the diagnostic accuracy of MRI in detecting malignant breast lesions across both genders. The findings will contribute to understanding how MRI performs not only in the more commonly affected female population but also in male patients, whose breast cancer diagnosis often occurs later due to a lower index of suspicion. This gender diversity further strengthens the study's validity in assessing the utility of MRI as a diagnostic tool for breast lesions in a broader context.<sup>13</sup>

TABLE-III

MRI	Frequency	Percentage (%)
(+ve)	147	57.4
(-ve)	109	42.6
Total	256	100.0

FIGURE-3



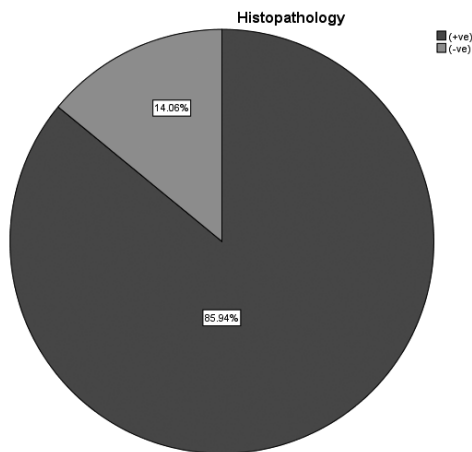
The MRI results showed that 57.4% of the patients (147 out of 256) had positive MRI findings for malignant breast lesions, while 42.6% (109 out of 256) had negative findings. The higher percentage of positive MRI results indicates that MRI was able to detect malignant lesions in over half of the patients, highlighting its sensitivity in identifying potential

cancers. The relatively high proportion of negative results (42.6%) suggests that MRI was also capable of ruling out malignancies in a significant number of cases. This balance between positive and negative results is essential for assessing MRI's diagnostic accuracy in breast cancer detection. While the positive cases suggest MRI's potential for early cancer detection, the negative results are equally important in minimizing unnecessary biopsies and treatments. Further comparison with histopathology, the gold standard, will provide a more accurate understanding of MRI's performance, particularly its sensitivity, specificity, and diagnostic reliability.<sup>14</sup>

TABLE-IV

Histopathology	Frequency	Percentage (%)
(+ve)	220	85.9
(-ve)	36	14.1
Total	256	100.0

FIGURE-4



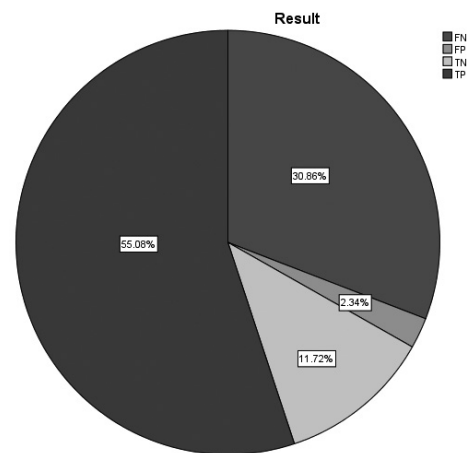
The histopathology results indicate that 85.9% of the patients (220 out of 256) were diagnosed with malignant breast lesions, while 14.1% (36 out of 256) had benign lesions. This high percentage of positive histopathology results reinforces the clinical relevance of the study, as the majority of patients were confirmed to have malignant lesions through the gold standard diagnostic method. The 14.1% of negative results suggests that a smaller proportion of patients had benign conditions, which is consistent with the prevalence of breast cancer in the general population. These findings serve as the benchmark for evaluating the diagnostic performance of MRI. Comparing MRI's results with histopathology allows

for the calculation of key diagnostic metrics, such as sensitivity, specificity, and diagnostic accuracy. The relatively high percentage of malignancy in the sample emphasizes the importance of effective screening and diagnostic tools, like MRI, in identifying and characterizing breast cancer accurately.<sup>15</sup>

TABLE-V

Results	Frequency	Percentage (%)
FN	79	30.9
FP	6	2.3
TN	30	11.7
TP	141	55.1
Total	256	100.0

FIGURE-5



The results from the study reveal the distribution of diagnostic outcomes based on MRI and histopathology comparison. Out of the 256 patients, 141 (55.1%) were true positives (TP), where MRI correctly identified malignant lesions, highlighting its high sensitivity. However, there were 79 false negatives (FN) (30.9%), where MRI failed to detect malignancies, indicating a limitation in its diagnostic sensitivity. Additionally, there were 6 false positives (FP) (2.3%), where MRI incorrectly indicated malignancy in benign lesions, pointing to its reduced specificity. Lastly, 30 patients (11.7%) were true negatives (TN), where MRI correctly identified the absence of malignancy. The relatively high number of false negatives suggests that while MRI is highly effective in detecting malignancies, it may miss some cases, stressing the need for complementary diagnostic methods. The false positive rate is low, which reflects MRI's reliability in identifying benign

lesions but points to the importance of confirming findings through histopathology.<sup>16</sup>

## DISCUSSION

The results of this study demonstrate that magnetic resonance imaging (MRI) is a highly sensitive diagnostic tool for detecting malignant breast lesions, with a sensitivity of 93.9%. This aligns with previous studies which has indicated the effectiveness of MRI in determining the presence of breast cancer especially in dense breast tissue, which may be poor by conventional mammography. MRI has a number of advantages over other imaging modalities, such as the capability to identify small lesions and also visualize the imaging on a three dimensional basis. It distinguishes benign and malignant lesions according to the structure of vascularity, tissue, which is very important to detect the early cancer stage and plan the treatment correctly.<sup>17</sup>

However, the relatively low specificity of MRI (73.5%) is a notable concern. The presence of false positives (2.3%) in this study suggests that MRI may incorrectly identify benign lesions as malignant. This limitation is significant because it could lead to unnecessary biopsies, additional imaging, and increased healthcare costs. Furthermore, false positives can contribute to unnecessary emotional distress for patients. These findings are consistent with earlier studies, where MRI was found to be more sensitive than specific, resulting in a higher number of false positives. This highlights the importance of confirming MRI findings with histopathology, the gold standard for breast cancer diagnosis, to avoid unnecessary interventions.<sup>18</sup>

The presence of false negatives (30.9%) in this study is another limitation of MRI. Despite its high sensitivity, MRI may miss some malignant lesions, which underscores the need for a multi-modal approach to breast cancer diagnosis. Combining MRI with mammography and ultrasound, particularly in high-risk patients or those with dense breasts, can improve the overall diagnostic accuracy. Additionally, further studies with larger sample sizes and a wider variety of lesion types would help in refining MRI protocols to address its current limitations.<sup>19</sup>

MRI's high cost, longer scan times, and technical

complexity also pose challenges for its widespread use, particularly in resource-limited settings. These factors could limit its accessibility for some patients, especially in developing countries where mammography and ultrasound are more affordable and readily available. Moreover, MRI's inability to distinguish between benign and malignant lesions in some cases means that additional imaging or biopsy may still be required, thus raising concerns about its cost-effectiveness in routine screening.<sup>20</sup>

In clinical practice, while MRI is an invaluable tool for evaluating complex or unclear breast lesions, its role as a first-line imaging modality should be carefully considered. Its high sensitivity makes it particularly useful in patients with a strong clinical suspicion of breast cancer or in those with dense breast tissue. For other cases, MRI should be used as a supplementary diagnostic tool rather than as a primary screening method. Clinicians should weigh the benefits of MRI in detecting early-stage breast cancer against its costs and potential for false positives. This study confirms that MRI is a reliable tool for detecting malignant breast lesions, with high sensitivity and diagnostic accuracy. However, its specificity remains a limitation, which can result in false positives and unnecessary procedures. To improve the clinical utility of MRI, further research is needed to refine its diagnostic protocols and address its current limitations. Combining MRI with other imaging techniques and histopathology remains essential to ensure accurate breast cancer diagnosis and treatment planning.<sup>21</sup>

## CONCLUSION

In conclusion, this study confirms the diagnostic efficacy of magnetic resonance imaging (MRI) in detecting malignant breast lesions, with high sensitivity (93.9%) and diagnostic accuracy (89.3%). MRI's ability to detect lesions, especially in dense breast tissue, is particularly valuable, and it shows promising results as an adjunct to mammography. However, the study also highlights MRI's relatively low specificity (73.5%), resulting in false positives, which may lead to unnecessary procedures and emotional distress for patients. The presence of false negatives (30.9%) emphasizes the need for a multi-modal approach, combining MRI with other imaging techniques and histopathology. MRI should

not replace traditional diagnostic methods but should be used as a supplementary tool for preoperative characterization and high-risk cases. Future studies should aim to improve MRI's specificity and refine diagnostic protocols to enhance its clinical utility in breast cancer detection.

## CONFLICT OF INTEREST

The authors declare no conflict of interest.

## SOURCE OF FUNDING

This research received no specific grant from any funding agency in the public, commercial, or not-for-profit sectors.

Copyright© 19 Jan, 2026.

## REFERENCES

1. Fatima S, Waheed S, Khan MI. **Diagnostic accuracy of MR mammography in diagnosing malignant breast lesions taking histopathology as gold standard.** Journal of the College of Physicians and Surgeons Pakistan. 2019 Jan 1; 29(1):16-8.
2. Shafique A, Gonzalez R, Pantanowitz L, Tan PH, Machado A, Cree IA, et al. **A preliminary investigation into search and matching for tumor discrimination in World Health Organization breast taxonomy using deep networks.** Modern Pathology. 2024 Feb 1; 37(2):100381.
3. Liaquat F, Alia N, Ayub M, Sikander M. **Diagnostic accuracy of magnetic resonance imaging in diagnosing malignant musculoskeletal tumours, taking histopathology as gold standard.** Indus Journal of Bioscience Research. 2025 Jun 11; 3(6):114-7.
4. Ahmed A, Memon JA, Shah MS, Rehman HU, Baig T, Akram MN. **Diagnostic accuracy of magnetic resonance spectroscopy (MRS) in diagnosing malignant breast lesions taking histopathology as gold standard.** PJMHS. 2021; 15(7):1847.
5. Asif HM, Sultana S, Akhtar N, Rehman JU, Rehman RU. **Prevalence, risk factors and disease knowledge of breast cancer in Pakistan.** Asian Pacific Journal of Cancer Prevention. 2014; 15(11):4411-6.
6. Mann RM, Kuhl CK, Moy L. **Contrast-enhanced MRI for breast cancer screening.** Journal of Magnetic Resonance Imaging. 2019 Aug; 50(2):377-90.
7. Wong HB, Lim GH. **Measures of diagnostic accuracy: Sensitivity, specificity, PPV and NPV.** Proceedings of Singapore Healthcare. 2011 Dec; 20(4):316-8.
8. Ahmadani MA, Bhatti S, ul Abideen Z, Yaseen MS, Laique T, Malik J. **Imaging in breast cancer: Use of magnetic resonance spectroscopy.** Cureus. 2020 Aug 14; 12(8):e9734.
9. Shaukat U, Ismail M, Mehmood N. **Epidemiology, major risk factors and genetic predisposition for breast cancer in the Pakistani population.** Asian Pacific Journal of Cancer Prevention. 2013; 14(10):5625-9.
10. Hillman BJ, Harms SE, Stevens G, Stough RG, Hollingsworth AB, Kozlowski KF, et al. **Diagnostic performance of a dedicated 1.5-T breast MR imaging system.** Radiology. 2012 Oct; 265(1):51-8.
11. Juanpere S, Perez E, Huc O, Motos N, Pont J, Pedraza S. **Imaging of breast implants—a pictorial review.** Insights Into Imaging. 2011 Dec; 2(6):653-70.
12. Colombo G, Ruvolo V, Stifanese R, Perillo M, Garlaschi A. **Prosthetic breast implant rupture: imaging—pictorial essay.** Aesthetic Plastic Surgery. 2011 Oct; 35(5):891-900.
13. Kilic F, Ogul H, Bayraktutan U, Gumus H, Unal O, Kantarci M, et al. **Diagnostic magnetic resonance imaging of the breast.** The Eurasian Journal of Medicine. 2012 Aug; 44(2):106.
14. Menezes GL, Knuttel FM, Stehouwer BL, Pijnappel RM, van den Bosch MA. **Magnetic resonance imaging in breast cancer: A literature review and future perspectives.** World Journal of Clinical Oncology. 2014 May 10; 5(2):61.
15. Bhooshan N, Giger ML, Jansen SA, Li H, Lan L, Newstead GM. **Cancerous breast lesions on dynamic contrast-enhanced MR images: Computerized characterization for image-based prognostic markers.** Radiology. 2010 Mar; 254(3):680-90.
16. Quratulain S, Bibi S, Gul S, Khatoon S, Mahmood H, Sadia H. **The diagnostic accuracy of conventional breast ultrasound in diagnosing malignant breast lesions taking histopathology as gold standard: Diagnostic accuracy of breast ultrasound in malignant lesions.** Pakistan Journal of Health Sciences. 2024 Jun 30:36-41.
17. Robbins J, Jeffries D, Roubidoux M, Helvie M. **Accuracy of diagnostic mammography and breast ultrasound during pregnancy and lactation.** American Journal of Roentgenology. 2011 Mar; 196(3):716-22.
18. Jethava AS, Ali SY, Wakefield DO, Crowell R, Sporn J, Vrendenburgh J. **Diagnostic accuracy of MRI in predicting breast tumor size: Comparative analysis of MRI vs histopathological assessed breast tumor size.** Conn Med. 2015 May 1; 79(5):261-7.
19. Medeiros LR, Duarte CS, Rosa DD, Edelweiss MI, Edelweiss M, Silva FR, et al. **Accuracy of magnetic resonance in suspicious breast lesions: A systematic quantitative review and meta-analysis.** Breast Cancer Research and Treatment. 2011 Apr; 126(2):273-85.
20. Farooq A, Zameer S, Khadim R, Manzoor A. **Diagnostic accuracy of magnetic resonance imaging in diagnosing bone tumors keeping histopathological correlation as gold standard.** Pakistan Armed Forces Medical Journal. 2021 Jan 31:S207.
21. Alyami W, Kyme A, Bourne R. **Histological validation of MRI: A review of challenges in registration of imaging and whole-mount histopathology.** Journal of Magnetic Resonance Imaging. 2022 Jan; 55(1):11-22.

## AUTHORSHIP AND CONTRIBUTION DECLARATION

1	<b>Zunaira Aftab:</b> Data collection, drafting.
2	<b>Salahuddin Baloch:</b> Literature search.
3	<b>Mubashir Iqbal:</b> Study design.
4	<b>Narmeen Khan:</b> Drafting.
5	<b>Rida Fatima:</b> Literature search.
6	<b>Sanallah:</b> Data analysis.