



TRANSCRANIAL DURAL REPAIR; EFFICACY IN THE MANAGEMENT OF EARLY TRAUMATIC CEREBROSPINAL FLUID RHINORRHEA.

Sohail Amir¹, Maimoona Qadir², Muhammad Usman³

1. MBBS, MS (Neurosurgery)
Assistant Professor Neurosurgery
Naseer Teaching Hospital
Peshawar.
2. MBBS, FCPS
Registrar Gynae & Obstetric Unit
Khyber Teaching Hospital
Peshawar.
3. MBBS, FCPS (Neurosurgery)
District Specialist
Department of Neurosurgery
Naseer Ullah Babar Memorial
Hospital, Peshawar.

Correspondence Address:

Dr. Sohail Amir
Assistant Professor Neurosurgery
Naseer Teaching Hospital Peshawar.
dr.sohailamir@gmail.com

Article received on:

27/03/2017

Accepted for publication:

30/05/2017

Received after proof reading:

08/08/2017

ABSTRACT... Objectives: To determine efficacy of transcranial dural repair in management of early traumatic cerebrospinal fluid (CSF) rhinorrhea by measuring the rate of resolution of rhinorrhea following repair. **Material and Study Design:** Descriptive study. **Period:** 18 months from March 2014 to September 2015. **Setting:** Department of Neurosurgery Naseer Teaching hospital Peshawar. **Methods:** 30 patients, all head injury patients with CSF rhinorrhea of either gender and any age, reporting to Accident and emergency department were included in the study. MRI Brain T2 Weighted in prone position done in all cases to identify the dural rent. Transcranial intradural repair was done through subfrontal approach. Post op complications were documented and follow at two months. **Results:** In this study 30 patients with cerebrospinal fluid (CSF) leak were observed. The minimum age was 8 years and the maximum was 59 years. 23 (76.6%) were male and 7 (23.3%) were female. 18 (60%) patients have CSF rhinorrhea due to road traffic accident, 7 (23.3%) patient with history of fall, while 5 (6.6%) patient were in other category. MRI brain T-2 Weighted done in all patient to identify the dural defect. The surgical approach was intradural in all of the 30 (100%) patients having fascia lata graft in 28 (93.3%) patients and pericranium in 2 (7%) patients to cover the defect properly. Among the immediate complications 3 (10%) patients had recurrent CSF leak, 2(6.6%) had meningitis, 5 (16.6%) had Pneumoencephalus while 3(10%) patients had other complications like subarachnoid hemorrhage, wound infection etc. The overall success rate was 90%. **Conclusion:** It is concluded that in post traumatic cerebrospinal fluid (CSF) rhinorrhea, if the defect in dura is demonstrated it must be repaired as soon as possible in order to prevent fulminant meningitis.

Keywords: Cerebrospinal fluid rhinorrhea, efficacy, intradural, meningitis, subarachnoid hemorrhage.

Article Citation: Amir S, Qadir M, Usman M. Transcranial dural repair; Efficacy in the management of early traumatic cerebrospinal fluid rhinorrhea.. Professional Med J 2017;24(8):1232-1236. DOI: 10.17957/TPMJ/17.3954

INTRODUCTION

Cerebrospinal fluid (CSF) rhinorrhea is a leakage of CSF from the nasal cavity caused by cranial base or meningeal defects. Aetiologically, CSF rhinorrhea can be classified as: traumatic (fronto-basal skull fractures), iatrogenic (as a result of intracranial surgery), congenital, neoplastic and idiopathic. A CSF leak from the intracranial space to the nasal respiratory tract is potentially serious because of the risk of an ascending infection which could produce fulminant meningitis.¹⁻³

Traumatic CSF leak are divided into two groups i-e early leaks that present within one week and delayed leaks that present in months or years.^{4,5} The main presenting symptom is the constant and uncontrollable unilateral watery rhinorrhea.

It can also present as pneumoencephalus, and meningitis. The fluid nature is confirmed by reservoir sign, and target sign. Plain films, multiplanar tomography, computer tomography (CT) and magnetic resonance imaging (MRI) delineate the anatomy and pathology of the skull base, sinuses, and calvaria. Magnetic resonance imaging (MRI) brain with intravenous gadolinium contrast media in prone position is gold standard investigation to detect the underlying dural defect.⁷

CSF rhinorrhea poses a management challenge for neurosurgeons. Conservative management and surgical treatment of CSF rhinorrhea is highly individualized and depends on a number of factors including etiology, anatomic site, patient

age, and underlying intracranial pressure. The transcranial procedure should be the treatment of choice for patients with frontal sinus fracture, multiple or complex anterior base fractures, or nerve injury.^{8,9}

Postoperative success rates for transcranial approach is 97%.⁷ Fascia lata with vascularized pericranium is highly reliable tensile and well suited for reconstruction of anterior skull base.⁸

CSF leak emanating from head injury carry significant consequences. On national level we need epidemiologic and outcome data of our own patients. Our study will furnish valuable information in this regard by determining efficacy of transcranial repair in early traumatic CSF rhinorrhea.

MATERIAL AND METHODS

The study was descriptive case series. Total of 30 patients were studied in 18 months duration (March 2014 to September 2015). All head injury patients with CSF rhinorrhea of either gender and any age, reporting to Accident and emergency department and those admitted to Neurosurgery unit were included in the study, however, patients presenting with delayed onset or complications and those referred from other department were excluded. All the subjects in our study presented to us 4-28 hours after the trauma took place. After taking permission from the hospital ethics committee for conducting the study data was collected through proforma (annexed). The patients were assessed by adequate history, thorough examination and investigations (plain X-Ray skull as a baseline in all head injury patients, MRI brain to identify the exact location of rent, and other investigations where indicated).

Transcranial intradural repair was done through subfrontal approach; bicoronal or unilateral. All patients were prepared for surgery with preoperative routine investigations and evaluation for general anesthesia fitness was done. Patient shifted to operation theatre and put in supine position on table. After proper scrubbing hair line incision was made and bicoronal approach was

adopted in those patients for which wide exposure was needed (43.3%) and unilateral approach was used in (56.6%) of patients. Rest of the procedure was same in both approaches; burr holes were made and flap elevated bilateral or unilateral as required. Frontal sinuses were packed with bone wax. Linear incision made in dura, brain retracted CSF sucked, defect identified in the cribriform plate and fascia lata graft was put over the defect. Hemostasis meticulously secured. Dura closed water and air tight. Hitch stitches applied to dura, and bone flap replaced. Skin close and antiseptic dressing done.

Data was analyzed and recorded using SPSS version 20.0. frequencies and percentage were calculated and presented in form of tables.

RESULT

Total of 30 patients were studied in 18 months, the minimum age was 8 years and the maximum age was 59 years. Mean age was 30 years. 23 (76.6%) were male and 7 (23.3%) were female. 18(60%) patients had road traffic accident, 7 (23.3%) patients had history of fall while 5 (6.6%) patients were in other category like sports injuries, fire arm injury, and blunt trauma.

In our series all patient presented with CSF leak 30(100%) followed by headache 28(93.3%), ENT bleed 26(86.6%), vomiting 24(80%) and fits 10(33.3%). Halo sign and reservoir sign was observed in all cases. (Table-I). Patients were thoroughly investigated; including skull x-rays were taken in all 30 (100%) patients, CT scan brain was done in 21 (70%) patients and MRI brain in head prone position was done in all patients to rule out CSF rhinorrhea.

The surgical approach was intradural in all patients having fascia lata graft in 28 (93.3%) patients and pericranium in 2 (7%) patients to cover the defect properly. CSF drainage not done in any patient pre operatively while 4 (13.3%) patients had undergone post operative CSF drainage. Associated facial bone fractures were not operated pre operatively while 3 (12%) patients had under gone surgery for facial fractures and

lastly sinus was not repaired in any patient while it was packed in all 30 (100%) patients.

In 13 (43.3%) bicoronal craniotomy was performed where wide exposure was needed and in 17 (56.6%) unilateral subfrontal approach was

adopted (Table-II) Among intraoperative findings, all the 30 (100%) patients had a defect in the dura, 14 (46.6%) patients had fracture of cribriform plate and 10 (33.3%) patients had associated olfactory nerve damage (Table-III).

S. No	Symptoms	Frequency	Percentage	Sign	Frequency	Percentage
1	Headache	28	93.3%	Halo sign	30	100%
2	Vomiting	24	80%	Reservoir sign	30	100%
3	ENT bleed	26	86.6%	Battle sign	14	46%
4	Fits	10	33.3%	Raccoon eyes	27	90%
5	CSF leak	30	100%	Scalp wound	17	56.6%
6	Associated symptoms	14	46.6%			

Table-I. Presentation of CSF rhinorrhea

Approaches	No. of patients	Percentage
Bicoronal	13	43.3%
Unilateral	17	56.6%

Table-II. Surgical approaches

Operative findings	No. of patients	Percentage
Dural defect	30	100%
Fracture of cribriform plate	14	46.6%
Olfactory nerve injury	10	33.3%

Table-III. Operative findings

The immediate complications of surgery i.e. within one week accrued in 13 (43.3%) patients; 3 (10%) patients had recurrence, 2 (6.6%) patients had meningitis, 5 (16.6%) patients developed pneumocephalus while 3 (10%) patients had other complications like subarachnoid hemorrhage, wound infection, etc (Table-IV). All patients were followed-up for 8 weeks and the complications observed; 13 (43.3%) patient were lost to follow-up, 3 (10%) patients had recurrent CSF leakage and 2 (6.6%) patients had meningitis while rest of the patients were normal having no complication.

Complications	Frequency	Percentage
Recurrence	3	10%
Meningitis	2	6.6%
pneumoencephalus	5	16.6%
Others	3	10%

Table-IV. Immediate complications of surgery

DISCUSSION

Cerebrospinal fluid (CSF) rhinorrhea has been

described long ago by Galen.¹⁰ In 1926 Dandy repaired the intracranial defect for the first time and extracranial repair was done in 1948 by Dohlman.¹¹ Hirsch and later Vrabec described transnasal approach while in 1981 Wigand described the use of endoscope in the repair of small leaks for the first time in 1981.¹²

Traumatic CSF rhinorrhea is a common condition occurring in about 2% of head injury resulting in meningitis and its sequel and if not treated can result in recurrent meningitis having a mortality rate of upto 10%.¹³ CSF leak can be detected clinically by certain sign such as Halo sign, reservoir sign, glucose oxidase test and B-2 transferrin test. MRI brain T-2 Weighted images in prone position is the gold standard investigation and once dural rent is identified it must be repaired. The different options for the management of CSF rhinorrhea are transcranial approach (intracranial extradural repair and intracranial intradural repair) and transnasal endoscopic approach^{13,14}

In our study the etiology of CSF rhinorrhea is road traffic accident¹⁸ (60%) which correspond with study done by Samina khaleeq in which 92 patient were studied mostly were young male and mode of trauma was road traffic accident in 80%.¹⁵

The study done by Bell RB and his colleagues the average age of the patient was 28.2 ranging from 2 to 80 years in a total of 34 patients. In our

study the mean age was 30 which correlate with Bells study. In our study male patients were in majority 76% and female were 23% which again correspond with study done by Bell stating 66% male and 33% female.¹⁶

It is seen that patient after CSF rhinorrhea develop meningitis in postoperative period, in this regard Friedman JA and his colleagues found out 10% incidence of meningitis in a total of 51 case.¹⁷ In our study the incidence of meningitis was 3 out of 30 patients (10%) which is similar with Friedman JA study.

The surgical management of CSF rhinorrhea is a successful technique in this connection a study was done by McMains KC and his colleagues who concluded 92% success rate.¹⁸ In our study the success rate was 90% which again correlate with this study.

Our study correlate with all national and international studies and it is concluded that whenever there is defect in dura it should be repaired. The intradural approach being the superior one, the logic behind this is that leak can be more appropriately close from inside rather than outside. Although it is more extensive procedure and carries a risk of morbidity and mortality but if the case individualizes and properly selected the result can be rewarding.

Limitations of our study were small sample size, and short follow up period. Randomized clinical trials are needed to provide evidence base finding

CONCLUSION

It is concluded that in post traumatic cerebrospinal fluid (CSF) rhinorrhea, if the defect in dura is demonstrated it must be repaired as soon as possible in order to prevent fulminant meningitis. The Transcranial dural repair is the safe and effective way of CSF leak repair and hence prevention of complications.

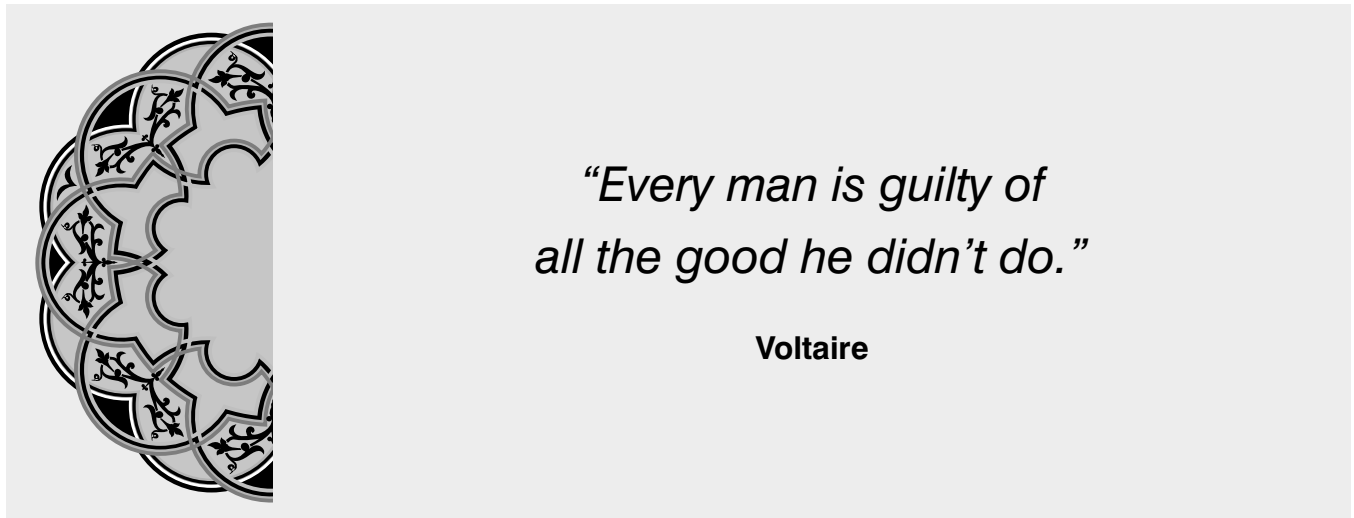
Copyright© 30 May, 2017.

REFERENCES

1. Abuabara A. **Cerebrospinal fluid rhinorrhea: diagnosis and management.** Med oral patol Oral Cir bucal 2007; 12(5):397-400.
2. Domengie F, Cottier JP, Lescanne E, Aesch B, Vinikoff-Sonier c, Gallas S, et al. **Management of cerebrospinal fluid fistulae: physiopathology, imaging and treatment.** J Neuroradiol 2004 Jan; 31(1):47-59.
3. Meco C, Oberascher G. **Comprehensive algorithm for skull base dural lesion and cerebrospinal fluid fistula diagnosis.** Laryngoscope 2004; 14:991-9.
4. Dagi FT. **Management of cerebrospinal fluid leaks. Schmidek and Sweet's operative neurosurgical techniques.** 5th ed. Philadelphia: Elsevier 2006:131.
5. Amin Mu, Ghaffar a. **Delayed appearance of posttraumatic cerebrospinal fluid fistula.** J Coll Physicians surg Pak May 2006; 16(5):378-80.
6. Matsumura A, anno I, kimura h. **Diagnosis of spontaneous intracranial hypotension by using magnetic resonance myelograph.** J Neurosurg.2000; 92(5):873-876.
7. Tosun F, Gonul E, Yetiser S, Greek M. **Analysis of different surgical approaches for the treatment of cerebrospinal fluid rhinorrhea.** Minim Invasive Neurosurg.2005; 48(6):355-60.
8. Gok A, ERKUTLU I, Alpetkin M, Kanlikama M. **Three-layer reconstruction with fascia lata and vascularized pericranium for anterior skull base defects.** cta Neurochir (Wien).2004;146(i):53-6;Epub 2003 Dec.
9. Pinan L, Shengtian W, ZHI I, Bo W. **Surgical strategy for cerebrospinal fluid rhinorrhea repair.** Neurosurgery 2010; 66(6):281-6.
10. Zlab Mk, Moore GF, Daly DT, et al. **Cerebrospinal fluid rhinorrhea: A review of the literature.** Ear Nose Throat J: 1999; (71):314-7.
11. Beckhardt RN, Setzen M, Carras R, **Primary spontaneous cerebrospinal fluid rhinorrhea.** Otolaryngology Head and neck surgery 1998;104(4):425-32.
12. Lanza DC, O' Brien DA, Kennedy DW. **Endoscopic repair of cerebrospinal fistulae and encephalocele.** 1996; 106(9):119-25.
13. Rodriguez de Antonio LA, Tallon Barranco A, Diez-Tajedor E, **CSF fistula in a woman with a history of idiopathic intracranial hypertension.** 2010; 25(8):515-6.
14. Gordon, N. **"Spontaneous intracranial hypotension".** Developmental Medicine and child neurology: 2009; 51(12):932-935.

1. Abuabara A. **Cerebrospinal fluid rhinorrhea: diagnosis and management.** Med oral patol Oral Cir

15. Khaleeq S, Khalid M, Zaman K. **Surgical outcome of Transcranial intradural repair in post traumatic Cerebrospinal fluid leak.** Ann.Pak.Inst.Med.sci.2015; 11(2):67-71.
16. Bell RB, Dierks EJ, Homer L, Potter BE, **Management of cerebrospinal fluid leak associated with craniomaxillofacial trauma.** J Oral Maxillofacial surgery 2004; (62):676-684.
17. McMain KC, Gross CW, Kountakis SE. **Endoscopic management of cerebrospinal fluid rhinorrhea.** 2004; 114(10):1833-37.
18. Friedman JA, Ebersold MJ, Qusat LM, **Post traumatic cerebrospinal fluid leakage.** World J Surg 2001; (25):1062-66.



AUTHORSHIP AND CONTRIBUTION DECLARATION

Sr. #	Author-s Full Name	Contribution to the paper	Author=s Signature
1	Sohail Amir	Concept and design, COllection and assembly of data, Analysis & interpretation of data	
2	Maimoona Qadir	Drafting of article, Statistical experizes.	
3	Muhammad Usman	Critical revision of article for importan intellectual content.	