



## HEMATOLOGICAL TOXICITY IN RATS; THERAPEUTIC PROPERTIES OF ANDROGRAPHIS PANICULATA ON OXALIPLATIN INDUCED

1. Department of Pharmacology, Ziauddin University, Karachi, Pakistan
2. Assistant Professor, King Saud bin Abdulaziz University for Health Sciences (KSAU-HS)-WR
3. Professor, Department of Pharmaceutics, Ziauddin University, Karachi, Pakistan
4. Chairman Department of Medicine, Aga Khan Hospital, Dar es salaam, Tanzania
5. Department of Pharmacology, Ziauddin University, Karachi, Pakistan
6. Quality control officer, Mektum Industry. Pvt. Ltd

### Correspondence Address:

Noor ul Ain  
Department of Pharmacology,  
Ziauddin University, Karachi, Pakistan  
Faculty of Pharmacy, Ziauddin  
University,  
ST-4B, Shahrah-e-Ghalib, Block-6,  
Clifton, Karachi, Pakistan.  
siddiquinoorulain@gmail.com

### Article received on:

08/09/2016

### Accepted for publication:

30/12/2016

### Received after proof reading:

14/02/2017

## INTRODUCTION

Andrographis paniculata (family Acanthaceae) is a native of tropical and subtropical lands. Andrographis paniculata identified as Hemptu Bumi and generally known as King of Bitter extensively cultivate in the tropical area of India, China and South East Asia.<sup>1</sup> Leaves contain an active phytoconstituent which is Andrographolide<sup>2</sup> and has anti-inflammatory<sup>3</sup> and hepatoprotective properties.<sup>4</sup> Andrographis paniculata extract improves activity of antioxidant enzymes i.e. glutathione-S-transferase, superoxide dismutase and catalase.<sup>5</sup> It also considerably reduces lipid peroxidation but significantly enhance concentrations of hepatic glutathione.<sup>6</sup> By inhibiting cell cycle progression, Andrographolide produces anticancer effects against human colorectal carcinoma LoVo cells.<sup>7</sup> Andrographis paniculata produces protective effects against carbon tetra chloride (CCl<sub>4</sub>) caused lipid peroxidation and liver damage.<sup>8</sup> Andrographolide inhibits nitric oxide (NO).<sup>9</sup> and oxygen radical

**Noor ul Ain<sup>1</sup>, Nusrat Bano<sup>2</sup>, Anwar Ejaz Beg<sup>3</sup>, Kamran Hameed<sup>4</sup>, Talha Bin Fayyaz<sup>5</sup>, Rafia Sadaf<sup>6</sup>**

**ABSTRACT... Objectives:** Oxaliplatin causes hematological toxicities in clinical setting which limits its efficacy. The aim of this study is to investigate the therapeutic effects of Andrographis paniculata against hematological toxicity caused by oxaliplatin. **Study design:** Experimental animal study. **Period:** Study takes 8 month from March 2015 to Oct 2015. **Setting:** Dow university animal house. **Method:** Wistar albino male rats, divided into 3 equals groups (n=6): Group N\* was a control group (0.9% normal saline), Group NP0 was Oxaliplatin treated group and Group NP1 was prophylactically treated with Andrographis paniculata followed by Oxaliplatin in order to assess the protective effects of Andrographis paniculata against the hematologic toxicity caused by Oxaliplatin. **Results:** Prophylactic treatment with Andrographis paniculata (NP1) significantly increases the levels of platelets and neutrophile count compared with the standard (NP0) (p<0.01) and increases the RBCs count and levels of hemoglobin compared with the standard (NP0). **Conclusion:** Prophylactic treatment with Andrographis paniculata (NP1) was effective in reducing risk of thrombocytopenia, anemia and neutropenia associated with Oxaliplatin.

**Key words:** Andrographis Paniculata, Hematotoxicity, Oxaliplatin, Rats.

**Article Citation:** Ain N, Bano N, Beg AE, Hameed K, Fayyaz TB, Sadaf R. Hematological toxicity in rats; therapeutic properties of andrographis paniculata on oxaliplatin induced. Professional Med J 2017;24(2):342-346.

**DOI:** 10.17957/TPMJ/17.3720

production in neutrophils<sup>3</sup>, inhibits NF-κB (controls DNA transcription and production of cytokine) activity<sup>10</sup>, TNF-α and IL-12 production<sup>11</sup> and migration of macrophage.<sup>12</sup> The aqueous extract of Andrographis paniculata reduced oxidative stress in lymphocytes isolated from rat when exposed to nicotine.<sup>13</sup> Andrographolide and 14-deoxy-11,12-didehydroandrographolide drastically inhibited thrombin-induced aggregation of platelet while neoandrographolide has little or no activity.<sup>14</sup>

Oxaliplatin is a agent that blocks DNA replication by forming platinum-DNA adducts which leads to cell cycle arrest and cell death.<sup>15</sup> Thrombocytopenia and neutropenia was a frequent toxicity seen during oxaliplatin treatment.<sup>16,17</sup> Oxaliplatin produces cytotoxic effects by initiating production of reactive oxygen species and make intra- and interstrand cross-links with DNA, DNA-protein adducts and thereby inducing DNA damage and apoptosis.<sup>18,19</sup>

The purpose of this study is to reduce the hematotoxic effects of Oxaliplatin and enhances the clinical efficacy of oxaliplatin by using the herbal drug (*Andrographis paniculata*) which possesses hematoprotective effects.

## MATERIAL & METHOD

The experimental study was designed in the Department of Pharmacology, Ziauddin University and conducted in DUHS (Dow University of Health Sciences), succeeding institutional and ethical approval. Three treatment groups (n=6), i.e. each consisting of 6 animals in each group, were designed; N\* (control) was the group to which we administered normal saline 0.9 %, NP0 (standard) received oxaliplatin and NP1 was the group received prophylactic treatment with *Andrographis paniculata* followed by oxaliplatin. Second phase of our study was to assess the changes in hematological profile for which complete blood count was conducted of each animal in a group.

Male albino Wistar rats 220 to 310 g were purchased from Dow University animal house. Animals were housed in properly ventilated, spacious animal house of Dow University of health sciences. Relative humidity (65-75%) and temperature  $23 \pm 2^\circ\text{C}$  was maintained with alternating 12 hr light and 12 hr dark cycles. Animal Food and tap water was provided adlibitum.

Five hundred grams of leaves of *Andrographis paniculata* were collected, washed and air dried. Leaves were grinded using standard grinding machine. Powder drug was macerated in analytical grade ethanol for 48 hours. Powdered leaves (10 gm) were extracted out successively with 100 ml of ethanol. Extraction was carried out in standard soxhlet apparatus at  $40-50^\circ\text{C}$ . The extract concentrate was stored in a refrigerator at  $4^\circ\text{C}$ . Extract concentrate of *Andrographis paniculata* was prepared in 5% DMSO solution (dimethyl sulfoxide) with water for injection for administration by oral route.

The albino wistar rats males were randomized to experimental and control groups, and divided into

3groups comprises of 6 animals in each group.

### Control N\*

Animals in group N\* served as the control group, where 2 ml of 0.9% normal saline was administered i.p for 6 weeks.

### Standard NP0

Animals grouped in NP0 received Oxaliplatin 0.8 mg/kg body mass intraperitoneally<sup>20</sup> for one week (day 1 and 6).

### Group NP1

Animals in Group NP1 were administered *Andrographis paniculata* prophylactically by oral route (400 mg/kg body mass/day for 5 weeks) followed by Oxaliplatin 0.8mg/kg i.p.for one week (day 1 and 6).

Albino wistar rats were housed for 56 days in animal house. Control time before and after dosing was 7 days with sufficient rat chow. Scheduled sacrifice/cardiac puncture was carried out on 7<sup>th</sup> day after last dose i.e. on day 56.

Blood drawn by cardiac puncture was collected in anticoagulant tubes. For estimation of hematological parameters, blood (2 ml) was collected in EDTA K3 tubes for examination of Red Blood Cells, Hemoglobin, Leucocytes, Platelets, Neutrophils, Lymphocytes, Eosinophils, Monocytes on automatic Humacount plus Hematology analyzer Model # 16400/S, (Human Germany).

## STATISTICAL ANALYSIS

Data was analyzed on SPSS version 19 with paired sample test, p value<0.05 was considered significant, p value<0.01 highly significant and p value<0.001 was considered very highly significant.

## RESULTS

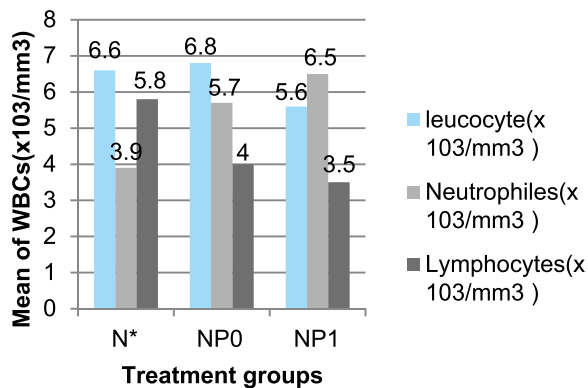
Figure-3&4 and Table-I. shows that the hemoglobin (Hb) levels highly significant increased ( $p < 0.01$ ) and the levels of RBCs significantly increased ( $p < 0.05$ ) in the group treated with *Andrographis paniculata* compared with standard (NP0).

Figure-1 and Table-I shows that Leucocyte count was very highly significantly decreased ( $p < 0.001$ ) in the group NP1. Figure-2 and Table-I shows that Platelet count and neutrophil count was highly significantly increased ( $p < 0.01$ ) in group NP1. Figure-1 and Table-I reveal that lymphocyte

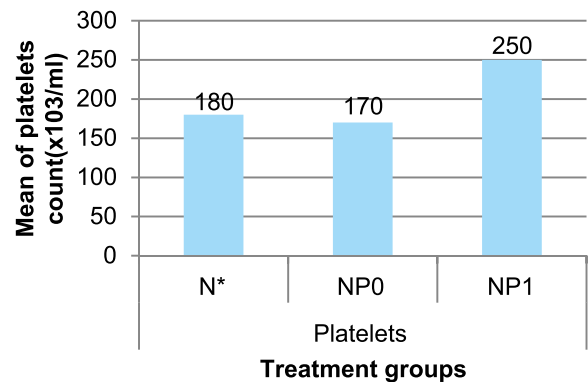
count was insignificantly affected ( $p > 0.05$ ) in group NP2. Table-I shows that eosinophil count was significantly increased ( $p < 0.05$ ) in group NP1 and the monocyte count was significantly decreased ( $p < 0.05$ ) in group NP1.

Paired Samples Test - Hematological profile						
Hematological profile		Paired Differences		t-value	df*	p-value
		Mean	Std. Deviation			
Hb(g/dl)	NP0 - NP1	-1.133	0.585	-4.742	5	0.005
RBC ( x 10 <sup>6</sup> /mm <sup>3</sup> )	NP0 - NP1	-0.383	0.279	-3.369	5	0.020
Leucocytes ( x 10 <sup>3</sup> /mm <sup>3</sup> )	NP0 - NP1	1.217	0.194	15.356	5	0.000
Platelets ( x 10 <sup>3</sup> /mL)	NP0 - NP1	-80.000	24.948	-7.855	5	0.001
Neutrophils ( x 10 <sup>3</sup> /mm <sup>3</sup> )	NP0 - NP1	-0.867	0.378	-5.620	5	0.002
Lymphocytes ( x 10 <sup>3</sup> /mm <sup>3</sup> )	NP0 - NP1	0.500	1.225	1.000	5	0.363
Eosinophils ( x 10 <sup>3</sup> /mm <sup>3</sup> )	NP0 - NP1	-0.011	0.007	-4.000	5	0.010
Monocytes ( x 10 <sup>3</sup> /mm <sup>3</sup> )	NP0 - NP1	0.008	0.005	3.983	5	0.011

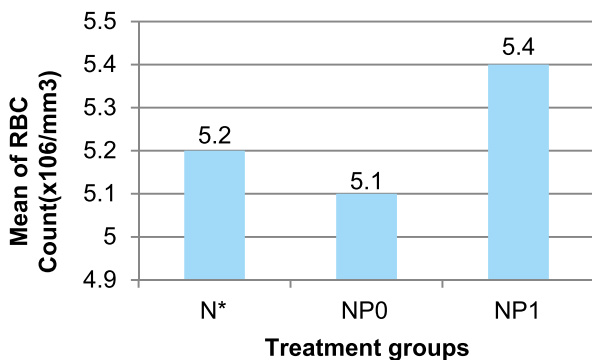
**Table-I. Comparative hematologic profile of NP1 (Andrographis paniculata + oxaliplatin) with Standard NP0 (oxaliplatin) df degree of freedom**  
**p-value < 0.05 (Significant), p-value < 0.01 (highly Significant), p-value < 0.001 (very highly Significant)**



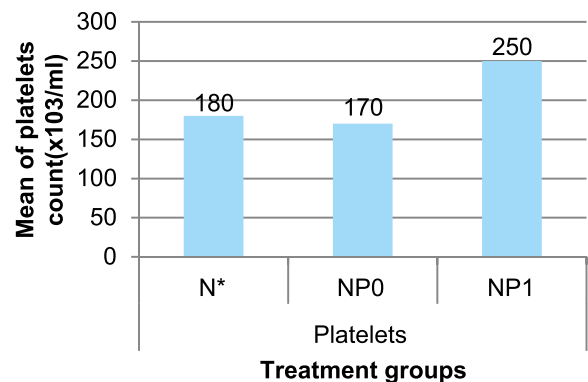
**Figure-1. Comparative difference in the levels of WBCs**



**Figure-2. Comparative difference in the levels of Platelets.**



**Figure-3. Comparative difference in the levels of RBCs**



**Figure-4. Comparative difference in the levels of hemoglobin.**

## DISCUSSION

Prophylactic treatment with *Andrographis paniculata* increases the platelet count compared with the standard (NP0). Thrombocytopenia was a frequent toxicity seen during oxaliplatin therapy. It occurs at any grade up to 70% of patients and leading to delays or even discontinuation of the chemotherapy.<sup>16</sup> The present study indicates that the prophylactic treatment with the *Andrographis paniculata* overcome the reduce levels of platelets induced by oxaliplatin i.e. reduced the occurrence of thrombocytopenia induced by Oxaliplatin. Prophylactic treatment with *Andrographis paniculata* increases neutrophil count compared with the standard (NP0). There was higher incidence of grade 3 or 4 neutropenia associated with oxaliplatin therapy.<sup>17</sup> This reveals that the prophylactic treatment with this agent decreases the incidence of neutropenia associated with Oxaliplatin and increases the efficacy of oxaliplatin. Lymphocyte count was insignificantly decreased in the group prophylactically treated with *Andrographis paniculata* (NP1). Andrographolide inhibits nitric oxide (NO) and oxygen radical production in neutrophils and inhibits macrophage migration as discussed above; indicate anti-inflammatory effects of *Andrographis paniculata*. Serious anemic condition was not frequently associated with Oxaliplatin except Evans' syndrome and immune hemolytic anemia which was rarely reported adverse events with oxaliplatin.<sup>21</sup> Prophylactic treatment with extract of *Andrographis paniculata* was effective in reducing the anemia associated with chemotherapy as it increase the levels of RBCs and Hb compared with standard (NP0) and further investigation is required to check the potential drug effect in reducing the immune induced thrombocytopenia and anemia .

Ethanollic extract of *Andrographis paniculata* also produces cytotoxicity and was effective against hepatic, lymphatic and colon human cancer cells.<sup>22</sup> It is suggested that prophylactic treatment with *Andrographis paniculata* followed by oxaliplatin administration will be effective as it may decrease the side effects caused by oxaliplatin plus enhance the antiproliferative activity of oxaliplatin.

Andrographolide stimulates the production of cytotoxic T lymphocytes and hence inhibit tumor growth in animals.<sup>23</sup> Prophylactic treatment with Ethanolic extract of *Andrographis paniculata* insignificantly decreases the levels of lymphocyte compared to the group treated with oxaliplatin alone. This indicates that the extract modulates the immune system but further investigation is required to figure out the beneficial effects of this drug against the hematic toxicity induced by oxaliplatin.

## CONCLUSION

Prophylactic treatment with *Andrographis paniculata* was effective in reducing the risk of thrombocytopenia and neutropenia induced by oxaliplatin. Prophylactic treatment with *Andrographis paniculata* increases the levels of RBC and hemoglobin compared with standard (NP0) i.e. the drug have the potential to decrease the occurrence of anemia caused by Oxaliplatin.






Copyright© 30 Dec, 2016.

## REFERENCES

1. Calabrese C, Berman SH, Babish JG, Ma X, Shinto L, Dorr M. **A phase I trial of andrographolide in HIV positive patients and normal volunteers.** *Phytother Res* 2000, 14(5):333–338.
2. Du Q, Jerz G, and Winterhalter P. **Separation of andrographolide and neoandrographolide from the leaves of *Andrographis paniculata* using high-speed counter-current chromatography.** *Journal of Chromatography A* 2003; 984(1): 147–151.
3. Shen YC, Chen CF, Chiou WF. **Andrographolide prevents oxygen radical production by human neutrophils: possible mechanism(s) involved in its anti-inflammatory effect.** *Br J Pharmacol.* 2002; 135(2): 399-406.
4. Trivedi NP and Rawal UM. **Hepatoprotective and antioxidant property of *Andrographispaniculata* (Nees) in BHC induced liver damage in mice.** *Indian Journal of Experimental Biology.*2001; 39(1): 41–46.
5. Verma N, Vinayak M .**Antioxidant action of *Andrographispaniculata* on lymphoma.** *Mol. Biol. Rep.* 2008; 35: 535-540.
6. Zhang XF and Tan BKH. **Anti-diabetic property of ethanolic extract of *Andrographispaniculata* in streptozotocindabetic rats.** *ActaPharmacologicaSinica* 2000; 21(12): 1157–1164.

7. Shi MD, Lin HH, Lee YC, Chao JK, Lin RA, and Chen JH. **Inhibition of cell-cycle progression in human colorectal carcinoma Lovo cells by andrographolide.** *Chemico-Biological Interactions.* 2008; 174(3): 201–210.
8. Jayakumar T, Hsieh CY, Lee JJ and RongSheu J. **Review Article Experimental and Clinical Pharmacology of Andrographis paniculata and Its Major Bioactive Phytoconstituent Andrographolide.** *Evidence-Based Complementary and Alternative Medicine.* 2013; Volume 2013: 16 pages. Article ID 846740,
9. Chiou WF, Chen CF, Lin JJ. **Mechanisms of suppression of inducible nitric oxide synthase (iNOS) expression in Raw264.7 cells by andrographolide.** *Br J Pharmacol* 2000, 129: 1553-1560.
10. Hidalgo MA, Romero A, Figueroa J, Cortes P, Concha II, Hancke JL, et al. **Andrographolide interferes with binding of nuclear factor- $\kappa$ B to DNA in HL-60-derived neutrophilic cells.** *Br J Pharmacol* 2005; 144: 680-686.
11. Qin LH, Kong L, Shi GJ, Wang ZT, Ge BX. **Andrographolide inhibits the production of TNF- $\alpha$  and IL-12 in LPS stimulated macrophages: role of mitogen activated protein kinases.** *Biol Pharm Bull* 2006; 29: 220-224.
12. Tsai HR, Yang LM, Tsai WJ, Chiou WF. **Andrographolide acts through inhibition of ERK1/2 and Akt phosphorylation to suppress chemotactic migration.** *Eur J Pharmacol* 2004, 498(1-3): 45-52.
13. Das S, Neogy S, Gautam N, Roy S. **In vitro nitotine induced superoxide mediated DNA fragmentation in lymphocytes: protective role of Andrographis paniculata Nees.** *Toxicol in Vitro* 2009; 23: 90-98.
14. Chao WW and Lin BF. **Isolation and identification of bioactive compounds in Andrographispaniculata (Chuanxinlian).** *Chao and Lin Chinese Medicine* 2010; 5: 17.
15. Kelland L. **The resurgence of platinum-based cancer chemotherapy.** *Nat Rev Cancer* 2007; 7: 573–584.
16. Jardim DL, Rodrigues CA, Novis YAS, Rocha VG & Hoff PM. **Review Oxaliplatin-related thrombocytopenia.** *Annals of Oncology* 2012; 23(8): 1937-1942.
17. Haller DG. **Safety of oxaliplatin in the treatment of colorectal cancer.** *Oncology (Williston Park)* 2000; 12(11): 15-20.
18. Wang D, Lippard SJ. **Cellular processing of platinum anticancer drugs.** *Nat Rev Drug Discov.* 2005; 4(4): 307–320.
19. Brozovic A, Ambriovic-Ristov A, Osmak M. **The relationship between cisplatin-induced reactive oxygen species, glutathione, and BCL-2 and resistance to cisplatin.** *Crit Rev Toxicol.* 2010; 40(4): 347–359.
20. Najam R, Bano N, Mirza T and Hassan S. **Adverse effects on cardiovascular status and lipid levels of albino Wistar rats treated with cisplatin and oxaliplatin in combination with 5 Fluorouracil.** *Pak. J. Pharm. Sci.* 2014; 27(5): 1409-1418.
21. Koutras AK, Makatsoris T, Paliogianni F, Kopsida G, Onyenadum A, Gogos CA, et al. **Oxaliplatin-Induced Acute-Onset Thrombocytopenia, Hemorrhage and Hemolysis .A Case Report and Review of the Literature.** *Oncology* 2004; 67: 179–182.
22. Geethangili M, Rao YK, Fang SH, and Tzeng YM. **Cytotoxic constituents from Andrographis paniculata induce cell cycle arrest in Jurkat cells.** *Phytotherapy Research.* 2008; 22(10):1336–1341.
23. Sheeja K and Kuttan G. **Activation of cytotoxic T lymphocyte responses and attenuation of tumor growth in vivo by Andrographis paniculata extract and andrographolide.** *Immunopharmacology and Immunotoxicology.* 2007; 29(1): 81–93.

### AUTHORSHIP AND CONTRIBUTION DECLARATION

Sr. #	Author-s Full Name	Contribution to the paper	Author=s Signature
1	Noor ul Ain	Concept, analysis, writeup and drafting. Perform experimental work and extraction of herbs.	
2	Nusrat Bano	Concept, designing, interpretation and final approval of manuscript.	
3	Anwar Ejaz Beg	Give his expert view for manuscript designing and finalizing the manuscript	
4	Kamran Hameed	Give his expert view in designing of work and help in analysis.	
5	Talha Bin Fayyaz	Help in experimental work, Data collection and manuscript writing.	
6	Rafia Sadaf	Help in data collection.	