



## FUNCTIONAL OUTCOME OF DYNAMIC COMPRESSION PLATING COMPARED WITH INTRAMEDULLARY INTERLOCKING NAILING IN CLOSED FRACTURE SHAFT OF HUMERUS IN ADULTS.

### 1. FCPS

Consultant  
Dow University of Health Sciences,  
Karachi, Pakistan.

### 2. FRCS

Professor Orthopedic Surgery  
Dow University of Health Sciences,  
Karachi, Pakistan.

### 3. FCPS

Assistant Professor Orthoprdic  
Surgery  
Dow University of Health Sciences,  
Karachi, Pakistan.

### 4. MBBS

House Officer  
Dow University of Health Sciences,  
Karachi, Pakistan.

### Correspondence Address:

Dr. Uzair Yaqoob  
Dow University of Health Sciences,  
Karachi, Pakistan.  
Lakhani Heights, Parsi Colony,  
Karachi.  
ozair\_91393@hotmail.com

### Article received on:

03/05/2019

### Accepted for publication:

25/10/2019

Muhammad Faraz Azmatullah<sup>1</sup>, Maratib Ali<sup>2</sup>, Adeel Ahmed Siddiqui<sup>3</sup>, Uzair Yaqoob<sup>4</sup>

**ABSTRACT... Objectives:** To compare the functional outcome of dynamic compression plating with intramedullary interlocking nailing in closed fracture of the humeral shaft in adults. **Study Design:** Prospective comparative study. **Setting:** Department of orthopedics, Civil hospital, Karachi. **Period:** From 8<sup>th</sup> February to 7<sup>th</sup> August 2017. **Material & Methods:** A total of 82 patients with post-traumatic closed fracture shaft of the humerus were included. Patients were randomly allocated into two groups. Group I was offered Intramedullary Interlocking nail (ILN) and Group II was offered a dynamic compression plate (DCP). The functional outcome was measured by the "Disabilities of Arm, Shoulder and Hand" (DASH) score. **Results:** The average age of the patients was 32.87 ± 6.65 years. The acceptable outcome was significantly high in DCP group as compared to the ILN group (87.8% vs. 61%; p = 0.005). **Conclusion:** We conclude that dynamic compression plating is functionally a better technique than interlocking nailing for closed fracture of shaft of the humerus in adults.

**Key words:** Dynamic Compression Plating, Humeral Fractures, Humerus, Intramedullary Interlocking Nailing, Nailing, Open Reduction Internal Fixation, Plating.

**Article Citation:** Azmatullah MF, Ali M, Siddiqui AA, Yaqoob U. Functional outcome of dynamic compression plating compared with intramedullary interlocking nailing in closed fracture shaft of humerus in adults. Professional Med J 2020; 27(4):765-771. DOI: 10.29309/TPMJ/2020.27.04.3673

## INTRODUCTION

Humerus fracture is a common but difficult to manage issue in orthopedics. These are usually managed non-operatively (with a hanging arm cast, U cast or a U slab) unless complicated. Since there is a thick covering of muscles and blood vessels on the bone, complete union is not always required. It is usually diaphyseal, and surgery is only indicated in case of non-union, neurovascular injuries, pathological, or open fractures, most common being multiple injuries.<sup>1-4</sup>

In surgical techniques, although controversies remain about the fixation with intramedullary nail (IMN) or dynamic compression plating (DCP)/locking compression plating (LCP), till now plating is found to be the better surgical modality,<sup>5,6</sup> with high union rates.<sup>1-3</sup> In a meta-analysis of randomized controlled trials, where plating was compared with IMN of humeral shaft fractures, it was found that the former has a low risk of complications and requires lesser clinical

expertise.<sup>6</sup> However, some studies concluded that there is a higher risk of radial nerve damage and biomechanical failure after plating, due to extensive tissue damage.<sup>3,4,6</sup> With the recent advances in medical field, some surgeons prefer IMN over plating, since IMN is less invasive and give greater mechanical stability.<sup>4,7-9</sup>

In a study by Modi et al., based on the disabilities of arm, shoulder and hand (DASH) scores, excellent results were found in the operative group when compared to non-operative ones. We used the similar scores in our study and have applied on two different procedures done on a fractured humerus i.e. DCP and IMN or ILN (Intramedullary interlocking nailing).<sup>10</sup>

The rationale of our study is to compare the functional outcome of DCP with ILN in closed fractures of the shaft of humerus. Different studies used different tools to measure outcome however, the DASH symptom scale is a validated

tool used only in a few.<sup>11</sup> By the virtue of this tool, the actual magnitude of functional outcome can be assessed and generalized to the entire target population giving us a better treatment modality for patients in our poor resource country.

## MATERIALS AND METHODS

This prospective comparative study was conducted in the Department of Orthopedics, Dr.KM Ruth Phau Civil hospital, Karachi, Pakistan from 8th February to 7th August 2017. Sample size calculation was done by taking statistics of a study done in 2015, using the hypothesis test for two proportion (2 sided test) formula. On considering the proportion of excellent functional outcome in DCP group as 43.5%, the proportion of excellent functional outcome in ILN group as 12%, significance level as 5%, power of the test as 90%, and type I error as 2.5%, minimum sample size came out to be 82.<sup>10</sup>

Patients of age 20-50 years with post-traumatic closed fracture shaft of humerus, duration of fracture  $\leq 4$  weeks, and American Society of Anesthesiologists (ASA) grade I and II were included. Those with skeletal immaturity diagnosed on non-fusion of the epiphysis of long bones assessed on X Rays, pathological fracture of shaft of humerus, or open fractures were not taken into consideration.

Patients were registered via non-probability consecutive sampling and randomly allocated in two groups by sequentially numbered sealed opaque envelope (SNOSE) method. Group I was offered ILN and Group II was offered DCP.

We used a standard antegrade statically locked humeral nail and standard dynamic compression plates of variable lengths from 7 holes to 10 holes depending upon fracture configuration. DCP was implanted through standard anterolateral, and in some cases lateral or posterior approaches. The plates used were AO 4.5 mm broad and narrow DCPs, with the length depending upon the type of fracture. Fixation of six to eight cortices proximal and distal to the fracture was obtained in every patient. The Russell Taylor type of IMN was used, and only antegrade nailing was done through the

standard tuberosity portal. Proximal and distal locking and reaming were done in all cases. The surgery was carried out under general anesthesia in all patients. All patients had a loading dose of antibiotics at induction and prophylactic antibiotics for 48 hours.

All patients were discharged after 48 hours. Stitch removal was done at 10 days in all patients. We followed the patients every four weeks until the union occurred while the final assessment was done at 12 weeks. From the first day, isometric exercises of the muscles of the upper and lower arm were carried out. During every visit, a complete assessment was done including one of the surgical wounds, pain, tenderness, range of motion of the joint, mechanical stability, and union. Union was assessed by seeing the anteroposterior and lateral x-ray films and was confirmed when there were bony trabeculae or cortical bone crossing fractures on at least three sites.

The functional outcome was measured at the final assessment at 12 weeks by applying the DASH score as excellent, good, fair, and poor as per the operational definition. Good to excellent was taken as an acceptable outcome.<sup>12</sup>

The statistical analysis was performed using statistical packages for social science version 19 (SPSS Inc., Chicago, IL). Qualitative variables like ASA status, gender, comorbid like Diabetes Mellitus, functional and acceptable outcome was presented in terms of frequencies and percentages. Age of the patients, height, weight, basal metabolic index (BMI), duration of fracture, and DASH scores were presented as mean  $\pm$  standard deviation. A Chi-square test was used for comparative analysis of functional outcomes. Two one-sided t-tests were used to compare the DASH score between groups. Effect modifiers/confounders like age, gender, BMI, duration of fracture, and Diabetes Mellitus status was dealt through stratification to see the effect of on outcome. The post-stratification chi-square test was applied and the p-value below 0.05 was taken as statistically significant.

The study was conducted after approval from the College of Physicians and Surgeons Pakistan and the institutional review board of Civil Hospital. The study purpose, procedure, risks, and benefits were explained to the patients and informed consent was taken by the primary investigator.

## RESULTS

A total of 82 patients with a post-traumatic closed fracture of the humeral shaft were included in this study. Patients were randomly allocated into two different groups. Group I was ILN and group II was offered DCP. A pictorial representation of this entire process in two patients of each group is given in Figures-1-5.

Distribution of patients according to different age groups, gender, diabetic status, BMI, and duration of fracture with their respective outcomes is presented in Table-I. There were 19 (46.34%) and 14 (34.15%) diabetics in group I and II respectively. Roadside accident was the most common cause of injury in 58% of cases. In male gender, rate of acceptable outcome was significantly higher in the DCP group ( $p = 0.025$ ). Similarly, in normal and overweight patients, the rate of acceptable outcome was significantly higher in the DCP group. Stratification analysis was performed with respect to duration of fracture and diabetic status as presented in Table-I with a significant association in non-diabetics ( $p <$

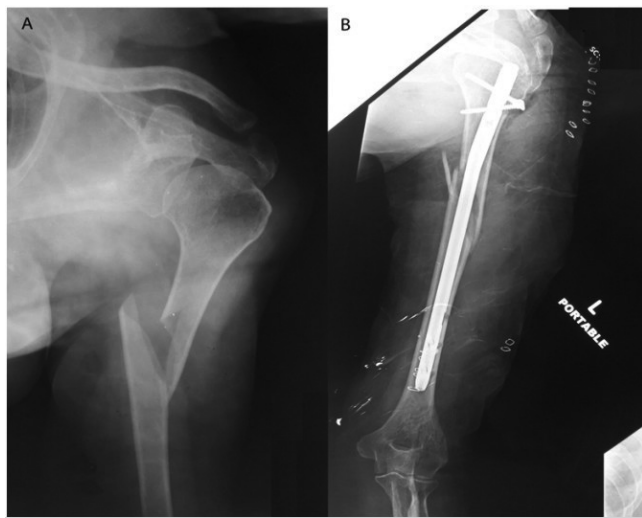
0.05), and greater than two weeks of fracture ( $p < 0.05$ ).

The average age of patients was  $32.87 \pm 6.65$  years. There were 51 (62.2%) males and 31 (37.8%) females. ASA status was similar in both groups as showed in Table-II.

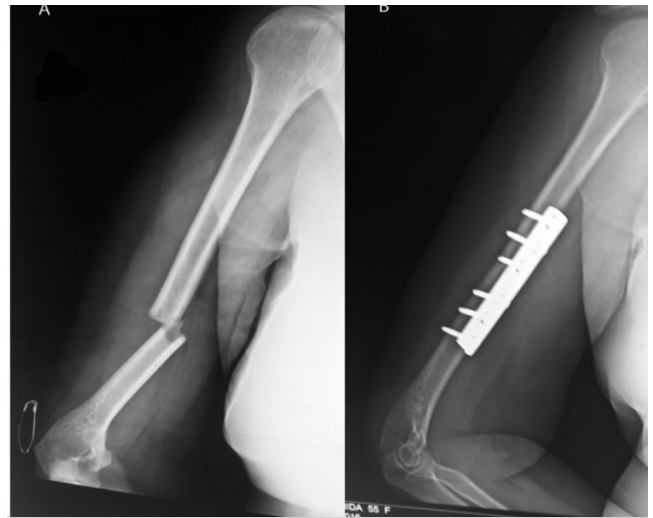
Four patients in the DCP group developed an infection which was superficial and completely eradicated after the course of antibiotic without hardware removal. Only one patient in the ILN group developed a superficial infection. Radial nerve palsy occurred in three cases of DCP group, all of those being neuropraxia which recovered in due course of 2-6 months. No nerve palsy was observed in ILN group while no hardware failure was observed in any group.

Functional outcome (as measured by DASH) of DCP with ILN in closed fracture of shaft of the humerus in adults is presented in figure-I. Good outcome was observed in both groups.

According to the operational definition of this study, acceptable outcome [excellent and good] was 87.8% (36/41) in DCP group and 61% (25/41) in ILN group ( $p < 0.05$ ) (Table-III). Rate of acceptable outcome was high in DCP group as compared to the ILN group in two different age groups but was statistically insignificant.

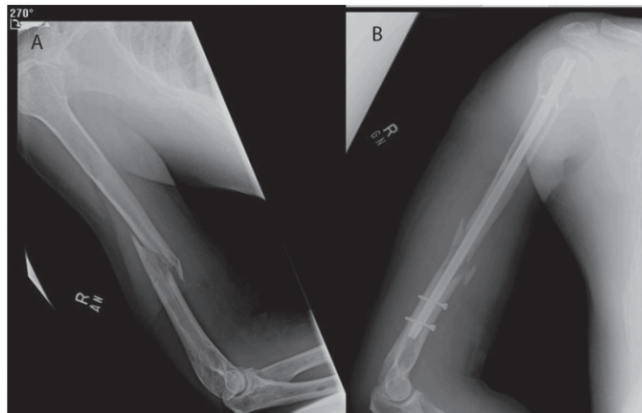

**Figure-1.** Post-traumatic closed fracture of a humeral shaft fixed by inserting an intramedullary interlocking nailing: A, Preoperative; B, Postoperative.

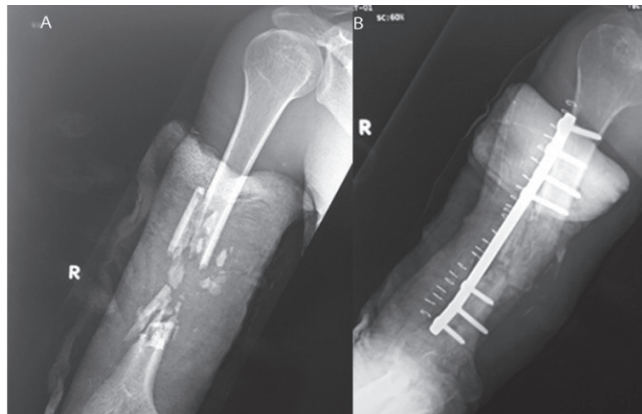


**Figure-3.** Post-traumatic closed fracture of a humeral shaft fixed by applying dynamic compression plating: A, Preoperative; B, Postoperative.

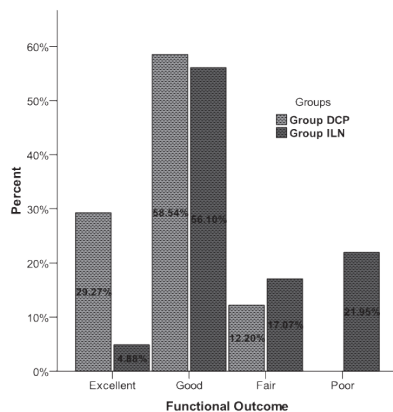
In male gender, rate of acceptable outcome was significantly higher in the DCP group ( $p=0.025$ ).



**Figure-2. Post-traumatic closed fracture of another humeral shaft fixed by inserting an intramedullary interlocking nailing: A, Preoperative; B, Postoperative.**



**Figure-4. Post-traumatic closed fracture of another humeral shaft fixed by applying dynamic compression plating: A, Preoperative; B, Postoperative.**



**Figure-5. Functional outcome of dynamic compression plating (DCP) with intramedullary interlocking nailing (ILN) in closed fracture of shaft of humerus in adults according to DASH score.**

**DISCUSSION**

In the present study, the mean age of the patients was  $32.87 \pm 6.65$  years, while in Chaudhary et al., it was found to be 39 and 35 years for ILN and plating group respectively.<sup>13</sup> Similarly, the mean age of patients was 45.3 years in a study conducted by Raghavendra, and Bhalodiya.<sup>14</sup> There were 62.2% males in this study, while Modi and Pundkar reported 77% of males in a similar study.<sup>10</sup> In our study, in 58% of patients, roadside accidents were the prime cause, a similar finding was observed in another study.<sup>15</sup>

In some studies, restricted shoulder movement and delayed union were seen with intramedullary nailing, believed to be caused by nerve damage due to accidental migration of nail more proximally, damage to the rotator cuff, capsulitis, etc.<sup>6,14</sup>

In our study, good functional outcome was observed in both groups. According to the operational definition of this study, acceptable outcome [Excellent and Good] was significantly high in DCP group (87.8%) as compared to ILN group (61%) ( $p = 0.005$ ). Similar results were also reported in other studies.<sup>10,13,16</sup> In contrast, Raghvendra and Bhalodiya found better outcomes in nailing group.

However, the plating group showed better union at 24 weeks follow-up attributed to distraction at the fracture during insertion.<sup>14</sup> There are also works done which have shown that there is no significant difference between the outcomes of the two techniques like the one done by Benegas E et al.<sup>17</sup> on the other hand, Wang X et al. reported plating to be a better option because of better results as far as the functional measurements and complications are concerned.<sup>18</sup>

In our work, based on the DASH score, the outcome was excellent in 10 (43.5%) and 3 (12%) patients, while good in 8 (32%) and 8 (34.78%) patients of DCP and ILN groups respectively. The fair results were higher in the ILN group. Another study gave us similar results.<sup>10</sup>

Variables	Acceptable Outcome	DCP Group (n=41)	ILN Group (n=41)	P-Value
Age (years)				
<35	Yes	23 (92%)	15 (71.4%)	0.067
	No	2 (8%)	6 (28.6%)	
	Total	25	21	
>35	Yes	13 (81.3%)	10 (50%)	0.052
	No	3 (18.8%)	10 (50%)	
	Total	16	20	
Gender				
Male	Yes	22 (84.6%)	14 (56%)	0.025
	No	4 (15.4%)	11 (44%)	
	Total	26	25	
Female	Yes	14 (93.3%)	11 (68.8%)	0.172
	No	1 (6.7%)	5 (31.3%)	
	Total	15	16	
Diabetic Status				
Yes	Yes	15 (78.9%)	8 (57.1%)	0.178
	No	4 (21.1%)	6 (42.9%)	
	Total	19	14	
No	Yes	21 (95.5%)	17 (63%)	0.007
	No	1 (4.5%)	10 (37%)	
	Total	22	27	
BMI				
Normal	Yes	24 (92.3%)	11 (57.9%)	0.006
	No	2 (7.7%)	8 (42.1%)	
	Total	26	19	
Overweight	Yes	9 (100%)	6 (50%)	0.019
	No	0 (0%)	6 (50%)	
	Total	9	12	
Obese	Yes	3 (50%)	8 (80%)	0.099
	No	3 (50%)	2 (20%)	
	Total	6	10	
Duration of fracture				
≤ 2 Weeks	Yes	30 (88.2%)	17 (94.4%)	0.47
	No	4 (11.8%)	1 (5.6%)	
	Total	34	18	
>2 Weeks	Yes	6 (85.7%)	8 (34.8%)	0.018
	No	1 (14.3%)	15 (65.2%)	
	Total	7	23	

**Table-I. Distribution of patient characteristics according to surgery type and their outcome (n=82).**

**Abbreviation:** DCP, dynamic compression plating; ILN, Intramedullary interlocking nailing; BMI, Basal metabolic index.

Acceptable Outcome	DCP Group (n=41)	ILN Group (n=41)	P-Value
Yes [Good and excellent Outcome]	36 (87.8%)	25(61%)	0.005
No [Poor and fair Outcome]	5 (12.2%)	16(39%)	

**Table-II. Comparison of acceptable outcome of dynamic compression plating (DCP) with intramedullary interlocking nailing (ILN) according to DASH score in close fracture shaft of humerus in adults.**

Chi-Square= 7.75

Variables	DCP Group (n=41)	ILN Group (n=41)
ASA Status		
ASA-I	22 (53.66%)	15 (71.4%)
ASA-II	24 (58.54%)	17 (41.46%)

**Table-III. ASA status of patients with respect to groups (n=82).**

Abbreviation: ASA, American society of anesthesiologists.

For a better union, patients should be mobilized early, since the muscle activity can restore the blood supply and fasten the granuloma formation.<sup>19</sup> Although we have found better DASH scores in patients with DCP, it might be due to uncooperative patients, pain, and muscle compression by nail and fibrosis. One of the ways this restriction can be removed is by removal of the nail after the full strength is gained, followed by physiotherapy and mobilization. Further works are needed where a greater sample size can be studied after removing this bias, and nullifying all the confounders. Union of bones after surgery should be studied and analyzed in detail. Humeral interlocking nailing as compared to dynamic compression plating is a complicated technique and specialized costly equipments are required in order to perform this procedure successfully.

## CONCLUSION

We finally conclude that dynamic compression plating although causing a greater number of complications compared to IMN is a preferred surgical technique for closed fractures of the humeral shaft in adults due to more favorable functional outcomes.




Copyright© 25 Oct, 2019.

## REFERENCES

- Walker M, Palumbo B, Badman B, Brooks J, Van Gelderen J, Mighell M. **Humeral shaft fractures: A review.** J Shoulder Elbow Surg. 2011; 20(5):833-44.
- Zhao JG, Wang J, Wang C, Kan SL. **Intramedullary nail versus plate fixation for humeral shaft fractures: A systematic review of overlapping meta-analyses.** Medicine (Baltimore). 2015; 94(11):e599.
- Duygun F, Aldemir C. **Is locked compressive intramedullary nailing for adult humerus shaft fractures advantageous?.** Eklem hastaliklari ve cerrahisi. 2017; 28(2):80-6.
- Puri SR, Biswas SK, Salgia A, Sanghi S, Aggarwal T, Kohli A. **Operative management of fracture of shaft humerus by dynamic compression plate versus interlocking intramedullary nailing: A comparative prospective study of 30 cases.** Med J DY Patil Univ. 2013; 6(1):49.
- Denies E, Nijs S, Sermon A, Broos P. **Operative treatment of humeral shaft fractures. Comparison of plating and intra-medullary nailing.** Acta Orthop Belg. 2010; 76(6):735-42.
- Bhandari M, Devereaux PJ, D Mckee M, H Schemitsch E. **Compression plating versus intramedullary nailing of humeral shaft fractures—a meta-analysis.** Acta orthop. 2006; 77(2):279-84.
- Ouyang H, Xiong J, Xiang P, Cui Z, Chen L, Yu B. **Plate versus intramedullary nail fixation in the treatment of humeral shaft fractures: An updated meta-analysis.** J Shoulder Elbow Surg. 2013; 22(3):387-95.
- Ma J, Xing D, Ma X, Gao F, Wei Q, Jia H, Feng R, Yu J, Wang J. **Intramedullary nail versus dynamic compression plate fixation in treating humeral shaft fractures: grading the evidence through a meta-analysis.** PLoS One. 2013; 8(12):e82075.
- Tetsworth K, Hohmann E, Glatt V. **Minimally invasive plate osteosynthesis of humeral shaft fractures: Current state of the art.** J Am Acad Orthop Surg. 2018; 26(18):652-61.

10. Modi N, Pundkar GN. **Comparative study of functional outcome of dynamic compression plating with intramedullary interlocking nailing in close fracture shaft of humerus in adults.** J Res Med Dent Sci. 2015; 3(4):298-302.
11. Dewan N, MacDermid JC, MacIntyre N, Grewal R. **Reproducibility: Reliability and agreement of short version of western Ontario rotator cuff index (short-WORC) in patients with rotator cuff disorders.** J Hand Ther. 2016; 29(3):281-91.
12. Atroshi I, Gummesson C, Andersson B, Dahlgren E, Johansson A. **The disabilities of the arm, shoulder and hand (DASH) outcome questionnaire: Reliability and validity of the Swedish version evaluated in 176 patients.** Acta Orthop Scand. 2000; 71(6):613-8.
13. Chaudhary P, Karn NK, Shrestha BP, Khanal GP, Paneru S, Kalawar RPS. **Dynamic compression plate versus intramedullary interlocking nail for management of humeral shaft fractures.** NOAJ. 2013; 3:10-13.
14. Radhavendra S, Bhalodiya HP. **Internal fixation of fractures of the shaft of the humerus by dynamic compression plate or intramedullary nail: A prospective study.** Indian J Orthop. 2012; 41:214-8
15. Gonçalves FF, Dau L, Grassi CA, Palauro FR, Neto AA, Pereira PC. **Evaluation of the surgical treatment of humeral shaft fractures and comparison between surgical fixation methods.** Revista Brasileira de Ortopedia (English Edition). 2018; 53(2):136-41.
16. Cocco LF, Ejnisman B, Belangero PS, Cohen M, dos Reis FB. **Quality of life after antegrade intramedullary nail fixation of humeral fractures: A survey in a selected cohort of Brazilian patients.** Patient safety in surgery. 2018; 12(1):4.
17. Benegas E, Neto AA, Gracitelli ME, Malavolta EA, Assunção JH, Prada FD, Neto RB, Mattar Jr R. **Shoulder function after surgical treatment of displaced fractures of the humeral shaft: A randomized trial comparing antegrade intramedullary nailing with minimally invasive plate osteosynthesis.** J Shoulder Elb Surg. 2014; 23(6):767-74.
18. Wang X, Chen Z, Shao Y, Ma Y, Fu D, Xia Q. **A meta-analysis of plate fixation versus intramedullary nailing for humeral shaft fractures.** J Orthop Sci. 2013; 18(3):388-97.
19. Hashib G. **Management of humeral shaft fracture: A comparative study between interlocking nail and dynamic compression plating.** Int J Res Orthop. 2016; 2(2):40-7.

### AUTHORSHIP AND CONTRIBUTION DECLARATION

Sr. #	Author(s) Full Name	Contribution to the paper	Author(s) Signature
1	M. Faraz Azmatullah	Conception and design, acquisition of data, analysis and interpretation of data.	
2	Maratib Ali	Conception and design, acquisition of data, analysis and interpretation of data.	
3	Adeel Ahmed Siddiqui	Drafted the article and did critical revision of the article.	
4	Uzair Yaqoob	Gave final approval of the version to be published. All authors read and approved the final manuscript.	