



## HERLYN WERNER WUNDERLICH SYNDROME; AN UNUSUAL PRESENTATION. A CASE REPORT.

1. MBBS, MCPS, FCPS  
Consultant  
Department of Gynaecologist and  
Obstetrician  
Senior Registrar  
Gynae Unit 1, Department of Obs/  
Gynae  
Holy Family Hospital, Rawalpindi,  
Pakistan.

**Correspondence Address:**

Dr. Bushra Khan  
Department of Gynaecologist and  
Obstetrician  
Holy Family Hospital, Rawalpindi,  
Pakistan.  
bushrakhandr@yahoo.com

**Article received on:**

07/07/2018

**Accepted for publication:**

15/11/2018

**Received after proof reading:**

31/01/2019

**Bushra Khan<sup>1</sup>**

**ABSTRACT...** Mullerian duct anomalies are underreported because these remain unrecognized. Unfortunately our knowledge of epidemiology has not paralleled the technical advances involved in their diagnosis and management. We report a case of 13 years old girl who presented with normal menarche and progressively severe dysmenorrhea. She was diagnosed to have a pelvic mass which was initially misdiagnosed as acute appendicitis, for which appendectomy was done. Later on, it was thought to be an ovarian cyst, till the time her IVU and CT scan confirmed diagnosis of Herlyn Werner Wunderlich Syndrome. Surgical management relieved symptoms. The aim is to create awareness among clinicians to keep a high index of suspicion of mullerian duct and associated anomalies in young girls.

**Key words:** Mullerian duct anomalies, Herlyn-Werner-Wunderlich syndrome

**Article Citation:** Khan B. Herlyn werner wunderlich syndrome; an unusual presentation. a case report. Professional Med J 2019; 26(2):368-370.

**DOI:** 10.29309/TPMJ/2019.26.02.3125

### INTRODUCTION

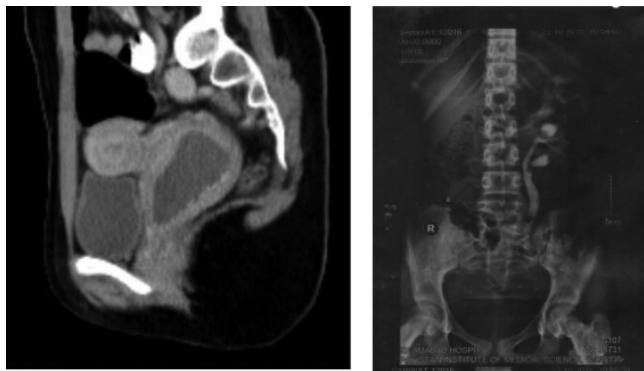
Mullerian duct anomalies affect around 1-3 %<sup>1</sup> of females worldwide and uterus didelphus make upto 11%<sup>2</sup> of uterine anomalies. However the incidence may vary in different populations and it is considered to be underestimated as many women with normally functioning ovaries and genitalia may go undiagnosed and unreported.<sup>3</sup> The significance of Mullerian duct anomalies lies in the fact that it may result in different variations of anatomical malformations like complete agenesis of uterus and vagina to duplication of both.<sup>4</sup> Furthermore, they may present with a large variety of gynaecological problems depending upon the malformed organs and the extent of anomalies. Some common problems may include primary amenorrhea, coital difficulty and dysparunia, sub fertility, recurrent miscarriages. Other possibly associated malformed systems include renal and urinary system (25%)<sup>5</sup> gastrointestinal system (12%)<sup>5</sup> and musculoskeletal system (10%).<sup>5</sup> Therefore, the gynaecologists must be well aware of the fact that treatment of mullerian duct anomalies need to be individualised based on patient's complaints as well as wish regarding treatment options.

### CASE REPORT

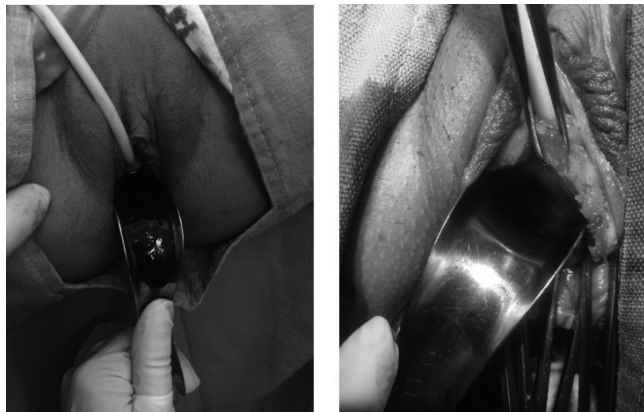A 13 years old girl, student of 7th standard, referred to us from surgical department and admitted through outpatient department with history of cyclical lower abdominal pain since the onset of her normal menarche i.e. 5 months back. She had been admitted in surgical ward for right iliac fossa pain 3 months back, where she was misdiagnosed as appendicitis and was operated upon but the pain did not relieve after surgery as well. Patient gave history of pain and feeling of heaviness and dragging sensation in lower abdomen during menstruation. The pain was non radiating, mild in intensity that kept on increasing with days of menstruation and gradually settled when the bleeding stopped. She otherwise, had normal 28day menstrual cycle with average blood flow. There were no associated urinary or bowel complaints.

On admission, patient was vitally stable. On abdominal examination a firm mass with regular margins was palpated in right iliac fossa and lower limit was not accessible. Local examination of vulva was unremarkable with normal looking external genitalia and intact hymen and no bluish membrane. Pelvic examination was not done.

Her baseline investigations were normal. Abdominal and pelvic ultrasound revealed double uterus and double vagina with obstruction of right sided vagina leading to hematocolpos. Left kidney was hydronephrotic and right kidney was atrophic and appeared to be in pelvis. On renal scan there was fairly functional left kidney with non functioning right kidney. IVU revealed non functioning right kidney with no dye uptake and moderate left hydronephroureter. CT scan revealed a uterus didelphys with obstructed right hemivagina and absent right kidney with left kidney hypertrophic and hydroureteronephrosis.



Her examination under anaesthesia and drainage of right sided hematocolpos was done. Intraoperative findings included bulge in right vaginal wall. Incision was made on the bulge and chocolate coloured fluid was drained. After drainage of fluid, two cervixes and single vagina with central septum (previously obstructing the right hemi-vagina) visualised. Septum was excised to allow further drainage of chocolate coloured fluid, creating a single vagina.



Postoperative recovery was normal and patient was referred to department of urology for evaluation of renal abnormalities.

She was called back for follow up and her subsequent menstrual cycles were found to be normal and unremarkable and follow up ultrasound scan revealed normal pelvic study with no evidence of any fluid collection.

## DISCUSSION

This case is a rare example of a triad of mullerian duct anomalies called Herlyn-Werner-Wunderlich syndrome. The syndrome is also known as Obstructed hemi vagina and ipsilateral renal anomaly (OHVIRA). The true incidence of this disorder is very small and only few cases have been reported.<sup>6</sup> The syndrome is characterized by a set of three disorders<sup>7</sup> such as mullerian duct anomaly (as uterus didelphys in our case), obstructed hemivagina and mesonephric anomaly (renal dysgenesis in our case).

Normal development of female reproductive tract results of differentiation from paired mullerian ducts and urogenital sinus. Disruption of this process of differentiation, migration and canalization leads to malformation of reproductive organs.<sup>8</sup> The Mullerian ducts are paired invaginations of Coelomic epithelium and they elongate in horizontal and vertical regions where each region results in formation of distinct organs. Uterus didelphys or double uterus is formed due to incomplete or complete arrest of midline fusion of mullerian ducts. Each hemiuteri has separate cervix, endocervical canal and one fallopian tube. The vagina may vary in number from single to double. The renal anomalies result from any interruption in differentiation of mesonephric ducts.

Females affected from Herlyn-Werner-Wunderlich syndrome usually present in the teenage after the onset of menarche. The most common presentation is cyclic dysmenorrhoea with or without menstrual flow depending upon type and extent of outflow obstruction. Any obstruction may lead to collection of menstrual blood resulting in hematocolpos and haematometra. In some cases pelvic mass may also be present. The diagnosis is often missed and patients are treated for other causes of lower abdominal pain such as Urinary tract infections, ovarian cysts,

endometriosis. In some cases diagnostic or therapeutic surgical interventions are also done as appendectomy in our case. The diagnosis is mainly made on clinical grounds along with radiological investigations including ultrasound, MRI and Intravenous urogram to confirm the renal status.

Treatment is always surgical, where incision and relief of vaginal obstruction and drainage of collected blood is mainstay of surgery. Vaginal dilators may be recommended to maintain patency of vagina. Patients usually have normal sexual life.<sup>6</sup> Pregnancy and its outcome may vary where the incidence of pregnancy in both hemi uteri is almost equal.

Hence the conclusion made is that Herlyn-Werner-Wunderlich syndrome or OHVIRA syndrome is rare disorder that may easily be missed clinically. However appropriate investigations and early diagnosis can not only relieve the symptoms but also prevent unnecessary medication and surgeries.

Copyright© 15 Nov, 2018.

## REFERENCES

1. Strassmann EO. **Fertility and unification of double uterus.** *Fertil Steril.* 1966 Mar-Apr; 17(2):165-76.
2. Nahum GG. Uterine anomalies. **How common are they, and what is their distribution among subtypes?.** *J Reprod Med.* 1998 Oct. 43(10):877-87.
3. Chan Y, Jayaprakasan K, Zamora J, Thornton GJ, Raine NF, Coomarasamy A. **The prevalence of congenital uterine anomalies in unselected and high-risk populations: A systematic review** *Hum. Reprod. Update* (November-December 2011) 17 (6): 761-771
4. Rock JA, Schlaff WD. **The obstetric consequences of uterovaginal anomalies.** *Fertil Steril.* 1985 May. 43(5):681-92.
5. Li S, Qayyum A, Coakley FV, Hricak H. **Association of renal agenesis and mullerian duct anomalies.** *J Comput Assist Tomogr.* 2000; 24(6):829-34.
6. Bajaj SK, Misra R, Thukral BB, Gupta R. **OHVIRA: Uterus didelphys, blind hemivagina and ipsilateral renal agenesis: Advantage MRI.** *Journal of Human Reproductive Sciences.* 2012;5(1):67-70.
7. Del Vescovo R, Battisti S, Di Paola V et-al. **Herlyn-Werner-Wunderlich syndrome: MRI findings, radiological guide (two cases and literature review), and differential diagnosis.** *BMC Med Imaging.* 2012; 12 (1): 4.
8. Amesse LS, Pfaff-Amesse T. **Congenital anomalies of the reproductive tract.** Falcone T, Hurd WW, eds. *Clinical Reproductive Medicine and Surgery.* 1st ed. New York: Elsevier; 2007, 171. 21(2): 235-9.



You can't have a better **tomorrow**  
if you're still thinking about **yesterday.**

“Unknown”



## AUTHORSHIP AND CONTRIBUTION DECLARATION

Sr. #	Author-s Full Name	Contribution to the paper	Author=s Signature
1	Bushra Khan	Development the theory, practically involved in case management, reporting, discussion, and making conclusion.	