

# RIGID BRONCHOSCOPY; A CASE SERIES OF 62 CASES IN CMH RAWALPINDI

ORIGINAL  
PROF-1749

## DR. MUHAMMAD TAHIR

MBBS, FCPS  
Graded ENT Specialist  
CMH, Multan

## DR. AMEER ABDULLAH, MBBS, FCPS

Graded ENT Specialist,  
CMH, Murree

## DR. MUHAMMAD ALI BHATTI, MBBS, FCPS

Graded ENT Specialist  
CMH, Okara

**ABSTRACT...Objectives:** To evaluate foreign bodies in tracheobronchial tree and effectiveness of the therapeutic use of rigid bronchoscopy in a tertiary care setting. **Study Design:** Descriptive study. **Place and duration of study.** This study was carried out at Department of ENT and Head and Neck Surgery, Combined Military Hospital, Rawalpindi from June 2006 to June 2010. **Patients and methods:** This descriptive study was designed to evaluate the foreign bodies in tracheobronchial tree & effectiveness of the use of rigid bronchoscopy in a tertiary care setting. Sixty two patients underwent initial evaluation by ENT consultants and senior registrars followed by management with rigid bronchoscopy. **Results:** The most commonly affected age group was under 4 years. Male to female ratio was 3:1. Right main bronchus was affected in 51.61% cases. Most of the foreign bodies removed were organic in nature in 90.32% cases. The success rate for removal with rigid bronchoscopy was achieved in 98.39% cases, with fewer complications and no mortality **Conclusions:** It may be concluded from this study that early diagnosis & management is essential to prevent morbidity & mortality associated with foreign bodies. Rigid bronchoscopy is the most effective procedure for the removal of foreign bodies in tracheobronchial tree.

**Key words:** Tracheobronchial tree , foreign bodies, rigid bronchoscopy

## INTRODUCTION

Despite improvements in medical care and public awareness, approximately 3000 deaths occur each year from foreign body aspiration in USA, with most deaths occurring before hospital evaluation and treatment. Children are more prone to aspirate foreign material with peak age incidence between one to three years. This is due to lack of molar teeth thus decreases their ability to sufficiently chew food and their habit to often examine even nonfood substances with their mouth. Male to female ratio is 2:1. Right main bronchus is the commonest site followed by left main bronchus for the foreign body to lodge. Obstruction of the tracheobronchial tree by a foreign body presents in variety of clinical features. The most common clinical presentations are choking, cough and wheeze followed by a relatively symptom free period as the object settles in the lower airway. Partial obstruction of one of the main bronchi causes specific wheeze on auscultation<sup>1</sup>. Often the F.B. may present with atypical symptoms and signs, like unexplained fever, chest pain, haemoptysis, persistent or recurrent lobar pneumonia & asthma<sup>2</sup>. The hyperinflation of one lung with mediastinal shift is evident on chest X-ray, but these findings are by no means

mandatory. The use of CT scan is not of additional advantage in diagnosis, as organic F.B. does not show up well<sup>1,3</sup>. A combination of good history, clinical signs and radiological investigation are more helpful in reaching the diagnosis than any of these separately<sup>4,5</sup>. If both the clinical signs and radiological investigations are negative but the history is suggestive of F.B. inhalation, then rigid bronchoscopy is preferred by otolaryngologists as a definitive tool for the diagnosis as well as removal of foreign body of tracheobronchial tree, with minimal complications<sup>6,7</sup>. Thus, a high index of suspicion and early consideration for rigid bronchoscopy are essential.

## OBJECTIVE

To evaluate foreign bodies in tracheobronchial tree and effectiveness of the therapeutic use of rigid bronchoscopy in a tertiary care setting

## MATERIAL AND METHODS

This is a descriptive study of foreign body removal at a tertiary care hospital. We received 62 patients from our emergency department with the diagnosis of foreign body inhalation, from June 2006 to June 2010. All cases underwent rigid bronchoscopy for the removal of foreign

body from tracheobronchial tree in general anaesthesia (G.A.). Analysis of the 62 cases showed 61 patients to be in the paediatric age group (under 12 years) and one adult 25 years old patient. Urgent chest x-ray and complete blood count were performed on all patients. The G.A. was given by anaesthetists using a T-piece circuit attached to the sidearm of the bronchoscope to allow delivery of oxygen and anesthetic gases during the procedure. The bronchoscopic procedures were done by ENT consultants having previous vast experience. The foreign bodies were visualized using ventilating rigid bronchoscope made by Karl StorzR, Germany. The size of the bronchoscope (external diameter) varied from 3.5 mm to 5 mm, and was selected according to the age of the patient. Chevalier Jackson forceps & suction apparatus with long tips were used to remove the foreign bodies & secretions. A second look was taken to ensure that a second foreign body had not been overlooked, and to remove any remaining small fragments particularly in case of peanuts. Antibiotics, oxygen and steroids were administered during per-op & post-op period to prevent complications. Post operatively, all the patients were observed overnight in ITC for airway distress. Deep breathing exercises were advised for resolution of the atelectasis and surgical trauma. Check X-rays chest were performed 6-12 hours after the operation. All the patients were discharged after 48 hours, except for one, who underwent for thoracotomy.

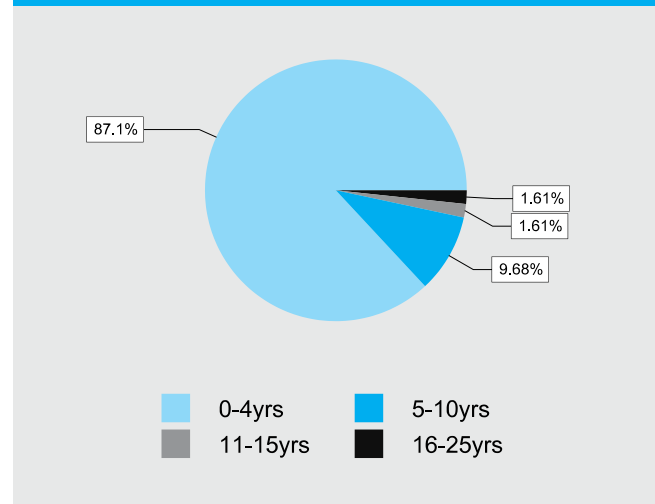
## RESULTS

Out of 62 patients included in this study, 47 (75.80%) were males and 15 (24.19%) females. Male to female ratio was approximately 3:1. Their ages ranged from 10 months to 25 years. 54 (87.09%) patients were under the age of four (Figure: 1).

The positive history was obtained from 58 (93.54%) patients. All presented in ENT OPD with in 24 hours. One (1.61%) patient presented with in a week with the history of cough, while three (4.83%) were initially treated by pediatrician for pyrexia of unknown origin (PUO) with cough and non-resolving asthma for 7-10 days. They were then referred to ENT department by the pediatric consultants on the suspicion of F.B. tracheobronchial tree. The most common presenting complaints were choking; cough & wheeze in 59 (95.16%) cases followed

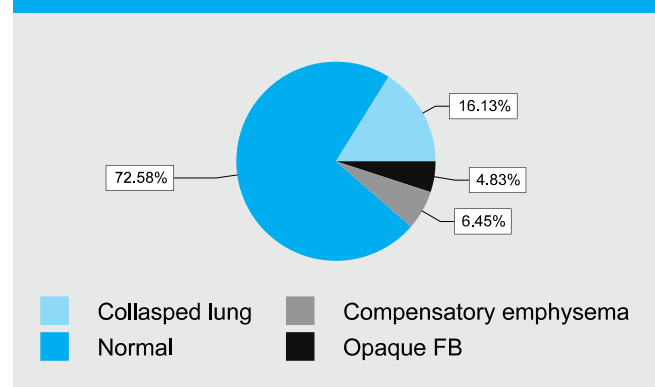
by pyrexia due to unknown origin in three (4.83%) cases. Ronchi & decreased breath sounds on the affected side were the most common clinical signs, found in all the patients.

Fig-1. Age distribution of the patients (n=62)



X-ray chest PA view was performed in all cases. It was normal in 45 (72.58%) cases. Opaque foreign bodies including 2 plastic whistles and a cap of fountain pen were visible in three (4.83%) cases. (Figure: 2).

Fig-2. X-ray chest (n=62)



During rigid bronchoscopy, 32 (51.61%) patients had foreign body in the right main bronchus (Figure: 3). No foreign bodies was found in larynx or trachea. The most frequently encountered foreign bodies were organic in 56 (90.32%) cases and non-organic in 6 (9.67%) cases (Figure: 4).

Fig-3. Site of impaction F.B. (n=62)

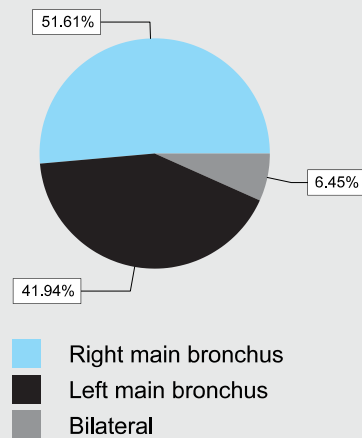
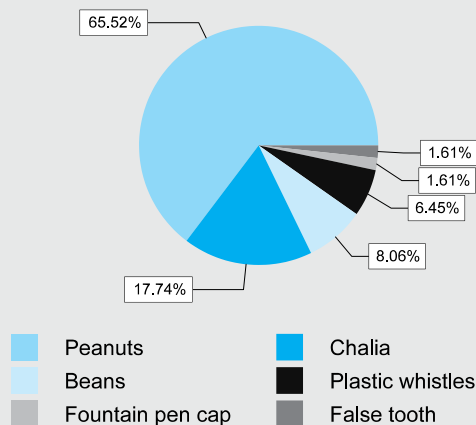


Fig-4. Types of F.B. aspirated (n=62)



Foreign bodies were successfully removed with rigid bronchoscopy in 61 (98.39%) cases. One patient had to undergo fiber optic bronchoscopy followed by lateral thoracotomy by the thoracic surgeons for the removal of F.B. after the unsuccessful rigid bronchoscopy. The major complication of bronchoscopy was airway edema post-operatively in 10 (16.12%) patients. There was no mortality associated with it.

## DISCUSSION

A foreign body in the airway is an extreme emergency and has been recognized for many years. Its diagnosis and treatment is challenging for otolaryngologists

because of the significant morbidity and mortality that continues to be associated with it. Jackson in 1936 reported a decrease in mortality for FBA from 24% to 2% with the use of endoscopic techniques for foreign body removal. Rigid bronchoscopy remains the procedure of choice for removing foreign materials, as the greater diameter of the rigid bronchoscope allows instruments to be more easily inserted through it.

Our study had 54 (87.09%) patients less than four years of age. It confirms the view of other studies that the highest incidence of foreign body inhalation occurs in less than four years age group, related to the fact that children are in the habit of putting objects into their mouth to determine their texture and taste, and to chew on when teething<sup>1,8</sup>. Male to female ratio was 3:1. It is not significantly different from previously reported cases, i.e. 2.4:1 or 2:1<sup>6,9</sup>. In our study the positive history of F.B. inhalation was obtained from 58 (93.54%) patients, while four (6.45%) cases presented with other complaints such as cough, PUO & un-resolving asthma. These results are similar to study done by Burton & Brick 1996<sup>10</sup>.

The most common presenting complaints were choking, cough & wheeze in 59 (95.16%) cases followed by pyrexia due to unknown origin in three (4.83%) cases. Similar observation was made by Burton & Brick, who observed the symptoms of foreign cough and wheezing in 93.54% cases<sup>10</sup>.

45 (72.58%) patients had normal chest findings. Opaque foreign bodies were visible in three cases. Positive x-ray findings such as collapsed lung or compensatory emphysema were visible in 14 (22.58%) cases. This is because majority of the patients presented in emergency within 24 hours and most of the foreign bodies were organic in nature. Similar observation was made by Baraka, who noted no x-ray evidence of a F.B. within 24 hours & dramatically altered figure after 24 hours, when abnormal x-rays were seen in 90% cases<sup>2</sup>.

During rigid bronchoscopy, 32(51.61%) patients had foreign body in the right main bronchus, 26 (41.93%) in left main bronchus and 4 (6.45%) patients had fragments of F.B. bilaterally. None of F.B. was found in larynx or trachea. The ratio of F.B. impaction between right & left

sides was 1.23:1. These results are in comparison to other studies by Cohen<sup>11</sup> and Baharloo<sup>12</sup>. According to Cohen and colleagues only 12% F.B. impaction occurs in larynx with most passing through cords in to tracheobronchial tree. Baharloo and colleagues state that in children F.B. tend to lie more centrally or just distal to carina, in contrast to adults, where objects tend to lodge in the distal bronchi or right main bronchus.

The most commonly inhaled F.B. was organic in 56 (90.32%) cases. Among these, peanuts were removed in 40 (71.42%) cases. This is because peanut is the most favourite & commonly available dry fruit in our country. The most common non-organic F.B. removed was plastic whistle in four cases. These whistles were packed along with toffees by the company, for their publicity. When compared with local & international studies, similar results were found. Both, nuts among organic F.B. and plastic toys among non-organic F.B. were the most frequent causes of accidental inhalation<sup>2,6</sup>.

The major complication of bronchoscopy i.e. airway edema was noted in 10 (16.12%) patients, post-operatively. For which O<sub>2</sub> ination, ventolin nebulisation and I/V steroids were given. There was no mortality associated with it. Rigid bronchoscopy for the removal of F.B. has a success rate of 99% in the literature<sup>2</sup>. Our results are comparable to it with successful removal of F.B. in 61 (98.39%) cases.

The average incidence of F.B. inhalation in our set-up was 15.5 (25%) cases per year. In the western world due to better public awareness & education the average incidence is not more than 5.9 cases per year, even in large tertiary care units such as Johns Hopkins Hospital<sup>13</sup>.

## CONCLUSIONS

The accidental inhalation of F.B. is preventable. Infants & children under the age of 4 should not be allowed to eat peanuts, and their play area should be cleared of small objects that could be inhaled. Adults should set a good example by never placing pins or tacks in their mouth. Otolaryngologists should consider foreign body

aspiration in the airway in the differential diagnosis of any patient with the complaints of stridor, dyspnea, sudden onset of cough and intractable and recurrent lower respiratory tract infections. Timely intervention with the experienced surgical team would decrease the complication and mortality rate.

Copyright© 04 March, 2011.

## REFERENCES

1. Carney AS, Patel N, Clarke R. **Foreign bodies in the ear and the aerodigestive tract in children.** In: Scott-Browns Otolaryngology, Head and Neck surgery, 7th ed. Hodder Arnold, 2008: 1188-1191.
2. Evans JNG. **Foreign bodies in the larynx & trachea.** In: Scott-Browns Otolaryngology, Head and Neck surgery, 6th ed. Oxford, London: Butterworth-Heinemann, 1997: 6/25/1-6/25/11.
3. Applegate KE, Dardinger JT, Lieber ML, Herts BR, Davros WJ, Obuchowski NA et al. **Spiral CT scanning technique in the detection of aspiration of LEGO foreign bodies.** Pediatric Radiology. 2001; 31: 836-40.
4. Ayed AK, Jafar AM, Owayed A. **Foreign body aspiration in children: diagnosis & treatment.** Pediatric Surgery International. 2003; 19: 485-8.
5. Ali M, Aslam S, Majeed FA, Ashfaq M. **An unusual foreign body bronchus (Open safety pin).** PAFMJ. 2008; 3.
6. Asmatullah, Inayatullah, Rasool G, Billah M, **Endoscopic removal of tracheobronchial foreign bodies at a peripheral hospital.** JPMI. 2004; 18 (3): 447-52.
7. Pasaoglu I, Dogan R, Demircin M, Hatipoglu A, Bozer AY. **Bronchoscopic removal of foreign bodies in children: retrospective analysis of 882 cases.** Journal of Thoracic & Cardiovascular Surgery. 1991; 39: 95-8.
8. Byard RW. **Mechanisms of unexpected death in infants & young children following foreign body ingestion.** Journal of Forensic Sciences. 1996; 41: 438-41.
9. Sharma HS, Sharma S. **Management of Laryngeal foreign bodies in children.** Journal of accident & emergency medicine. 1999; 16: 150-3.
10. Burton EM, Brick WG, Hall JD, Riggs JW, Houston CS. **Tracheobronchial foreign body aspiration in children.** Southern medical journal. 1996; 89: 195-8.

11. Cohen SR, Herbert WI, Lewis JGB, Geller KA. **Foreign bodies in the airway. Five year retrospective study with special reference to management.** Annals of otology, rhinology & laryngology. 1980; 89:437-42.
12. Baharloo F, Veyckemans F, Francis C, Bietlot MP, Rodenstein Do. **Tracheobronchial foreign bodies: presentation & management in children & adults.** Chest. 1999; 115: 1357-62.
13. Hughes CA, Baroody FM, Marsh BR. **Pediatric tracheobronchial foreign bodies: historical review from Johns Hopkins Hospital.** Annals of Otology, Rhinology & Laryngology. 1996; 105: 555-61.

Article received on: 18/02/2011

Accepted for Publication: 04/03/2011

Received after proof reading: 12/08/2011

**Correspondence Address:**

Dr. Muhammad Tahir  
MBBS, FCPS  
Graded ENT Specialist,  
CMH, Multan  
dr\_gopang@yahoo.com

**Article Citation:**

Tahir M, Bhatti MA, Abdullah A. Rigid bronchoscopy; a case series of 62 cases in CMH Rawalpindi. Professional Med J Sep 2011;18(3): 402-406.

**War is like love, it always  
finds a way.**

**(Bertolt Brecht)**