



DENTAL IMPLANT; OBJECTIVE EVALUATION OF BONE WIDTH AND HEIGHT AT PROSPECTIVE DENTAL IMPLANT SITES USING CONE-BEAM COMPUTED TOMOGRAPHY.

1. BDS, FCPS, OJT (UK)
Assistant Professor and Head
Department of Prosthodontics
National University of Medical Sciences
(NUMS), Islamabad.
2. BDS
PG Resident Prosthodontics
Armed Forces Institute of Dentistry,
Rawalpindi.
3. BDS, MSc, CHPE
Senior Registrar
Department of Prosthodontics
Army Medical College / Armed Forces
Institute of Dentistry
National University of Medical
Sciences (NUMS),
Islamabad, Pakistan.
4. BDS, FCPS, M.Sc. Med Edu
Assistant Professor
Department of Prosthodontics
Army Medical College / Armed Forces
Institute of Dentistry
National University of Medical Sciences
(NUMS),
Islamabad, Pakistan.
5. BDS
PG Resident Prosthodontics
Armed Forces Institute of Dentistry,
Rawalpindi.

Correspondence Address:

Dr. Ayesha Aslam
Department of Prosthodontics
Army Medical College / Armed Forces
Institute of Dentistry
National University of Medical
Sciences (NUMS),
Islamabad, Pakistan
dr.ayasha.aslam@hotmail.com

Article received on:

25/01/2018

Accepted for publication:

07/05/2018

Received after proof reading:

02/10/2018

INTRODUCTION

Replacement of missing teeth using dental implants has become the most reliable and popular treatment modality.¹ Use of dental implants has increased dramatically over the last twenty years and it is expected to amplify further in future.² Successful placement of a dental implant requires adequate occluso-apical height, mesio-distal length and bucco-lingual width of alveolar bone at the prospective site of placement.³ However, following tooth loss, alveolar bone undergoes remodeling with resultant changes in its dimensions.⁴ As a result, a patient may present with deficient bone height and width, precluding placement of dental implants.⁵

The prospective dental implant site needs to be evaluated both clinically and radiographically in

Mubashir Sharif¹, Sajjad Hussain², Ayesha Aslam³, Syed Hammad Hassan⁴, Muhammad Uzair Riaz⁵

ABSTRACT... Objectives: To measure the average bone width and bone height in the posterior edentulous spans in the mandible as well as to evaluate bone quality and anterior extension of the Inferior alveolar nerve to assess possibility for dental implant placement. **Study Design:** Cross-sectional study. **Setting:** Armed Forces Institute of Dentistry, Rawalpindi – Pakistan. **Period:** July 2017 to Oct 2017. **Method:** Bone height, width and anterior extension of inferior alveolar nerve was assessed using CBCT images from the hospital database. Bone quality was categorized as hard, moderately hard or soft based on clinician's tactile sensations. **Results:** Average bone width of 6.12 ± 1.51 mm and average bone height of 13.56 ± 2.43 mm was found among the study subjects. "Soft" bone quality was found most prevalent in the posterior mandible. Anterior extension of the Inferior alveolar nerve was visible in 14% of subjects only. **Conclusion:** Variations in the bone width, height and density endorse the importance of a site-specific bone tissue evaluation prior to implant installation.

Key words: Alveolar Ridge, Cone Beam Computed Tomography, Dental Implants.

Article Citation: Sharif M, Hussain S, Aslam A, Hassan SH, Riaz MU. Dental implant; objective evaluation of bone width and height at prospective dental implant sites using cone-beam computed tomography. Professional Med J 2018; 25(10):1600-1604. DOI:10.29309/TPMJ/18.4677

terms of its quality and quantity.⁶ Conventional radiographic techniques such as periapical, bitewing and panoramic view have been traditionally used for evaluation of implant sites but being two-dimensional, they allow only a limited analysis.⁷ Moreover, image distortion and superimposition of structures compromises the accuracy of these techniques.⁸

With the advent of 3-dimensional sectional imaging modalities such as computed tomography (CT) and cone-beam computed tomography (CBCT), the three-dimensional anatomy of the bone can now be visualized at submillimeter resolution pre-operatively.^{9,10} These modalities not only help to avoid superimposition and distortion errors but also allow measurements to be made in planes of space not available or accurately depicted in

conventional radiographs.^{11,12} They can also be used to fabricate surgical guides for accurate and guided implant placement.

CBCT has recently been declared as the diagnostic imaging modality of choice for treatment planning with dental implants.¹³ It is now cost – effective and allows imaging with lesser exposure to harmful radiations. Owing to its advantages, the use of CBCT images for pre-operative assessment for prospective implant placement has been on the rise. CBCT allows optimal selection of dental implant length and diameter for residual ridges of varying dimensions and avoid unintentional measurement errors that may lead to treatment failure.^{14,15} Different studies have been carried out to evaluate ridge height and width using CBCT in various populations.^{5,16} It appears that both bone width and bone height tend to vary among subjects of different ethnicity and race. The aim of this study, therefore, was to measure the average bone width and bone height in the posterior edentulous spans in the mandible of Pakistani population. It also aimed to assess bone quality in posterior mandible as well as anterior extension of the Inferior alveolar nerve (IAN) to evaluate the possibility for implant placement. The knowledge will help the clinicians in better planning and execution of dental implant therapy.

MATERIALS AND METHODS

A cross-sectional study was designed and carried out at Armed Forces Institute of Dentistry, Rawalpindi – Pakistan. Prior approval from AFID ethical committee was obtained. Based on previously published data⁷, keeping confidence level (1- α) at 95, absolute precision (d) at 0.12, population mean (μ) at 2.11, population standard deviation (σ) 0.53, a sample size of 85 was calculated using WHO sample size calculator. Bone height, width and anterior extension of inferior alveolar nerve (IAN) was assessed using CBCT images taken through CBCT unit NewTom VGi® (Quantitative Radiology, Verona, Italy). The images were retrieved from the hospital database. The data was collected from January 2015 to January 2016. Following inclusion and exclusion criteria was used to select CBCT images:

Inclusion Criteria

1. Good quality CBCTs.
2. Medium density and contrast of images.
3. Patients with no clinically observable oral pathology in the oral region.
4. Both male and female patients were selected.
5. Partially dentate patients with 1-2 teeth missing in the posterior mandible.
6. Healing period of at least 3 months after tooth extraction.
7. Patients with good oral hygiene i.e. no plaque or calculus deposits.

Exclusion Criteria

1. Distorted or unclear images.
2. Patients with adjacent metallic restorations with scatter effects in CBCT images.
3. Long span edentulous area i.e. 3 or more missing teeth.
4. Patients with bony protuberances in the mandible.
5. Patients with active lesions in the mandible.
6. Patients with a history of trauma.

After appropriate selection of the samples, informed consent was obtained from the patients to use their radiographic images for the study. Two measurements were performed on each edentulous site. Buccolingual width was measured between the two most prominent reference points - one on the buccal aspect of the bone and the other on the lingual aspect. Bone height was measured between the crest of the alveolar ridge and the superior aspect of the inferior alveolar nerve canal. Images were also evaluated to see if anterior extension of IAN was visible or not.

Bone quality of the edentulous span was assessed clinically by two independent qualified clinicians and was categorized as being “hard”, “moderately hard” or “soft”. For inter- and intra-examiner reliability, about ten subjects were randomly chosen and assessed independently for bone quality twice by each clinician. There was good (0.82) inter-examiner agreement and excellent (0.98) intra-examiner agreement between the two clinicians.

Collected data was analyzed using SPSS version 21. Descriptive statistics were calculated. Qualitative variables like gender were presented as frequency and percentages while quantitative variables like alveolar ridge dimensions obtained by CBCT were depicted as mean ± SD. Post stratification Fisher’s Exact test was used to evaluate the effect of gender on bone quality while the difference in mean bone width and height between males and females was compared using Independent Sample T - test. P value <0.05 was taken as significant.

RESULTS

Out of the sample of 85 individuals, 51 (60%)

were males while 34 (40%) were females. Table-I illustrates the mean values of buccolingual width and bone height amongst the sample. A statistically significant difference in mean buccolingual bone width was found between males and females (P<0.001) whereas no significant difference for bone height between genders could be established (Table-I). Anterior extension of the Inferior alveolar nerve could only be appreciated in 12 subjects (Table-II). The most prevalent bone quality according to subjective evaluation in the mandibular posterior region was “soft” (Figure-1). However, association of bone quality with gender using Fisher’s exact test was not found to be significant (P = 0.693).

Parameter	Minimum (mm)	Maximum (mm)	Mean ± SD	Mean ± SD (male)	Mean ± SD (female)	P value
Bone Width (bucco-lingual)	3.1	10.1	6.12 ± 1.51	6.61 ± 1.6	5.38 ± 1.01	< 0.001
Bone Height	6.1	19.8	13.56 ± 2.43	13.88 ± 2.49	13.07 ± 2.27	0.125

Table-I. Mean bone width and bone height in posterior edentulous region and its association with gender among the study subjects

Parameter	Visible on CBCT	Not Visible on CBCT
Anterior extension of Inferior Alveolar Nerve (IAN)	12 (14.12%)	73 (85.88%)

Table-II. Assessment of anterior extension of inferior alveolar nerve

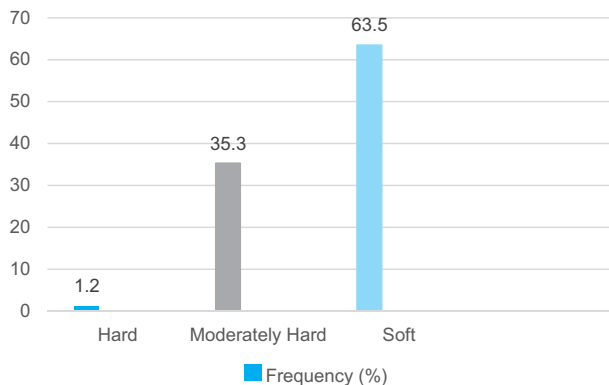


Figure-1. Frequency of bone quality encountered in mandibular posterior edentulous region

DISCUSSION

Appropriate patient history, clinical examination augmented with diagnostic cast and investigations are essential for adequate implant treatment. Every other patient presents with distinctive set of problems and treatment needs. The clinician must consider individual circumstances including

anatomical, functional and aesthetic requirements so that a realistic, predictable and satisfactory result can be achieved.

In the present study, the mean bucco-lingual bone width in the posterior mandible (edentulous site) was found to be 6.12 ± 1.51 mm. Similar results have been reported by Alrahaimi et al.⁵ who found a buccolingual bone width of 6.22 ± 1.96 mm in the premolar region and 6.51 ± 1.75 mm in the 1st molar region. Another similar study by Braut et al.¹⁶ reported a range of buccolingual widths, ranging from 3.47 mm to 10.1 mm. However, the increasing width values were found just superior to the inferior alveolar nerve canal and not close to the crest. Since in the present study, site-specific measurements were not recorded, hence, only a general comparison of results can be carried out. Also, in the present study, a statistically significant difference in mean buccolingual bone width was found between males and females (P<0.001)

with greater width seen in males. These findings are endorsed by those of Braut et al.¹⁶ who also reported significantly higher buccolingual bone width values in male subjects. Alrahaimi et al.,⁵ on the other hand, did not find any effect of gender on bone width.

In terms of bone height, the present study found a mean bone height of 13.56 ± 2.43 mm in the posterior mandible. Contradictory to these findings, Alrahaimi et al.⁵ reported a mean bone height of 15.19 ± 2.12 mm in the premolar region and 14.53 ± 2.34 in the 1st molar region. This suggests prevalence of increased bone height in the Saudi population as compared to the Pakistani population. In the study by Braut et al.,¹⁶ bone height gradually decreased from the first premolar to the 2nd molar region. Mean bone height in the 2nd premolar region was found to be 13.32 mm which is comparable to the findings of the present study. The present study did not find any significant difference in terms of bone height between male and female subjects. Similar findings have been reported by Alrahaimi et al.⁵ while Braut et al.¹⁶ found significantly greater bone height in Swiss males than in Swiss females. These differences can be explained on the basis of difference in ethnicity and also by the fact that the researchers selected fully dentate patients for measurements.

In the present study, the most prevalent bone quality in the posterior mandible was characterized as “soft”. Although this is not the most commonly used classification system, it seems rather practical for clinical evaluation of bone based on clinician’s subjective evaluation. Such a classification system was put forward by Trisi and Rao¹⁷ who also concluded that “hand feeling” can distinguish between two extreme bone qualities i.e. D1 and D4 but fails to distinguish between the intermediate qualities i.e. D2 and D3.

The present study also evaluated the anterior extension of IAN canal and found it visible in only 14% of the study samples. Studies reveal that visibility of mandibular canal decreases from the 3rd molar region to the region of mental foramen, the highest being in the 3rd molar region.¹⁸ This is

due to lack of definitive canal walls in the anterior region.¹⁹ These findings are corroborated by those of Aslam et al.²⁰

The present study has a few limitations to its credit. First, only partially dentate patients presenting to AFID were selected. Secondly, site-specific height and width were not evaluated, rather a mean value was calculated. Third, bone quality was only assessed in a subjective manner and not objectively. Despite these limitations, this study gives useful insight to quantitative evaluation of bone prior to implant placement. Its findings also build up on the epidemiological data pertaining to the local population. However, similar studies with larger sample size and a diverse sample must be carried out so that the results can be generalized to the population of the entire country.

CONCLUSION

Cone beam computed tomography (CBCT) provides excellent information to evaluate the morphology of the bone. Variations in bone width, height and density endorse the importance of a site-specific bone tissue evaluation prior to dental implant placement.





Copyright© 07 May, 2018.

REFERENCES

1. Juodzbalsys G, Kubilius M. **Clinical and radiological classification of the jawbone anatomy in endosseous dental implant treatment.** J Oral Maxillofac Res. 2013;4:1-17.
2. Mittal Y, Jindal G, Garg S. **Bone manipulation procedures in dental implants.** Indian J Dent. 2016;7:86-94.
3. Zhang W, Skrypczak A, Weltman R. **Anterior maxilla alveolar ridge dimension and morphology measurement by cone beam computerized tomography (CBCT) for immediate implant treatment planning.** BMC oral health. 2015;15:65.
4. Safi Y, Vasegh Z, Kadkhodazadeh M, Hadian H, Bahemmat N. **Different methods to evaluate mandibular alveolar ridge in cone beam computed tomography images in pre-implant surgery assessments.** Int J Med Res Health Sci. 2016;5:134-42.
5. Alrahaimi SF, Venkatesh E. **Localization of mandibular canal and assessment of the remaining alveolar bone in posterior segment of the mandible with**

- single missing tooth using cone-beam computed tomography: A cross sectional comparative study.** J Korean Assoc Oral Maxillofac Surg. 2017;43:100-5.
6. Vasconcelos TV, Neves FS, Moraes LAB, Freitas DQ. **Vertical bone measurements from cone beam computed tomography images using different software packages.** Braz Oral Res. 2015;29:1-6.
 7. Panchbhai AS. **Quantitative estimation of vertical heights of maxillary and mandibular jawbones in elderly dentate and edentulous subjects.** Spec Care Dentist. 2013;33:62-9.
 8. Harris D, Horner K, Grondahl K, Jacobs R, Helmrot E, Benic GI, et al. **E.A.O. guidelines for the use of diagnostic imaging in implant dentistry 2011. A consensus workshop organized by the European Association for Osseointegration at the Medical University of Warsaw.** Clin Oral Implants Res. 2012;23:1243-53.
 9. Pertl L, Gashi-Cenkoglu B, Reichmann J, Jakse N, Pertl C. **Preoperative assessment of the mandibular canal in implant surgery: comparison of rotational panoramic radiography (OPG), computed tomography (CT) and cone beam computed tomography (CBCT) for preoperative assessment in implant surgery.** Eur J Oral Implantol. 2013;6:73-80.
 10. de Souza LA, Souza Picorelli Assis NM, Ribeiro RA, Pires Carvalho AC, Devito KL. **Assessment of mandibular posterior regional landmarks using cone-beam computed tomography in dental implant surgery.** Ann Anat. 2016;205:53-9.
 11. Benavides E, Rios HF, Ganz SD, An CH, Resnik R, Reardon GT, et al. **Use of cone beam computed tomography in implant dentistry: The international congress of oral implantologists consensus report.** Implant Dent. 2012;21:78-86.
 12. Alkhader M, Hudieb M, Jarab F, Shaweesh A. **The visibility of mandibular canal on orthoradial and oblique CBCT slices at molar implant sites.** Biotechnol Biotechnol Equip. 2016;30:770-6.
 13. Tyndall DA, Price JB, Tetradis S, Ganz SD, Hildebolt C, Scarfe WC. **Position statement of the American Academy of Oral and maxillofacial radiology on selection criteria for the use of radiology in dental implantology with emphasis on cone beam computed tomography.** Oral Surg Oral Med Oral Pathol Oral Radiol. 2012;113:817-26.
 14. Guerrero ME, Noriega J, Castro C, Jacobs R. **Does cone-beam CT alter treatment plans? Comparison of preoperative implant planning using panoramic versus cone-beam CT images.** Imaging Sci Dent. 2014;44:121-8.
 15. Kajan ZD, Asli HN, Taramsari M, Chai SM, Hemmaty YB. **Comparison of height and width measurements of mandibular bone in various head orientations using cone beam computed tomography: An experimental in-vitro study.** Oral Radiol. 2015;31:28-35.
 16. Braut V, Bornstein MM, Kuchler U, Buser D. **Bone dimensions in the posterior mandible: A retrospective radiographic study using cone beam computed tomography. Part 2—analysis of edentulous sites.** Int J Periodontics Restorative Dent. 2014;34:639-47.
 17. Trisi P, Rao W. **Bone classification: Clinical-histomorphometric comparison.** Clin Oral Implants Res. 1999;10:1-7.
 18. Oliveira-Santos C, Capelozza AL, Dezzoti MS, Fischer CM, Poleti ML, Rubira-Bullen IR. **Visibility of the mandibular canal on CBCT cross-sectional images.** J Appl Oral Sci. 2011;19:240-3.
 19. Gowgiel J. **The position and course of the mandibular canal.** J Oral Implantol. 1992;18:383-5.
 20. Aslam A, Aslam S. **Visibility of mandibular canal on CBCT Images before prosthetic rehabilitation with dental implants.** 4th Pakistan Prosthodontics Association Conference; Karachi, Pakistan 2015.

AUTHORSHIP AND CONTRIBUTION DECLARATION

Sr. #	Author-s Full Name	Contribution to the paper	Author=s Signature
1	Mubashir Sharif	Study concept and design.	
2	Sajjad Hussain	Data collection and analysis + Writing.	
3	Ayesha Aslam	Manuscript writing.	
4	Syed Hammad Hassan	Critical revision.	
5	Muhammad Uzair Riaz	Data collection & analysis.	