



1. B.D.S, M. Phil  
Assistant Professor,  
Department of Oral Pathology  
Dow University of Health Sciences,  
Karachi
2. M.B.B.S, F.C.PS, PhD  
Professor and Director of PhD  
Department of Pathology  
King Edward Medical University,  
Lahore
3. B.D.S, M.D.S, F.C.PS  
Professor and Chairman  
Department of Oral & Maxillofacial  
Surgery  
King Edward Medical University/  
Mayo Hospital, Lahore
4. BDS, FCPS  
Assistant Professor  
Department of Operative Dentistry  
Dow University of Health Sciences
5. BDS, M.Phil  
Assistant Professor  
Department of Oral & Maxillofacial  
Surgery, King Edward Medical  
University/Mayo Hospital, Lahore
6. B.D.S  
Department of Orthodontics  
Demont Morency College of  
Dentistry, Lahore

**Correspondence Address:**

Dr. Mulazim Hussain Bukhari  
Professor and Director of PhD  
Department of Pathology  
King Edward Medical University  
Lahore  
[mulazim.hussain@gmail.com](mailto:mulazim.hussain@gmail.com)

**Article received on:**

27/05/2014

**Accepted for publication:**

10/11/2014

**Received after proof reading:**

17/01/2015

## ORAL SQUAMOUS CELL CARCINOMA; CLINICO-PATHOLOGICAL PARAMETERS AND AGNOR STATUS IN GRADING

Dr. Sofia Ali Syed<sup>1</sup>, Dr. Mulazim Hussain Bukhari<sup>2</sup>, Dr. Riaz Ahmed Warraich<sup>3</sup>, Dr. Fauzia Quadir<sup>4</sup>,  
Dr. Asifa Iqbal<sup>5</sup>, Dr. Faryal Ali Syed<sup>6</sup>

**ABSTRACT... Background:** The aim of this study was to evaluate clinico-pathological parameters and the status of argyrophilic nucleolar organizer regions stain in various histological grades of oral squamous cell carcinoma. **Materials and Methods:** A cross sectional study was conducted on fifty cases of oral squamous cell carcinoma. The specimen were collected from the department of Oral & Maxillofacial Surgery and processed for hematoxylin and eosin stain and AgNOR stain Pathology Laboratory, King Edward Medical University Lahore. **Results:** Bidi smoking is associated with oral squamous cell carcinoma. The AgNOR (mAgNOR and pAgNOR) status was significantly low in well differentiated and moderately differentiated compared to poorly differentiated oral squamous cell carcinoma ( $p = 0.001$ ). AgNOR size in poorly differentiated was significantly higher than the AgNOR size in well differentiated oral squamous cell carcinoma. Similarly the distribution of AgNOR in moderately and poorly differentiated oral squamous cell carcinoma was significantly high. The AgNORs index was significantly high in poorly differentiated squamous cell carcinoma as compared to well differentiated and moderately differentiated squamous cell carcinoma. **Conclusions:** The use of AgNORs stain is easy, valid and reliable method to assess the histological grading of oral squamous cell carcinoma and should be used to predict the prognosis of patients.

**Key words:** AgNOR stain, AgNOR mean and index, squamous cell carcinoma, histological grading, smoking, huqqa

**Article Citation:** Syed SA, Bukhari MH, Warraich RA, Quadir F, Iqbal A, Syed AF. Oral squamous cell carcinoma; clinico-pathological parameters and agnor status in grading. Professional Med J 2015;22(1):018-026.

### INTRODUCTION

Squamous cell carcinoma (OSCC) is the sixth most common malignant tumor worldwide. In Pakistan, it is the second most common cancer among males and third most common cancer in female. OSCC occurs in middle and old people ranging from 40 to 65 years of age. Several studies also reported OSCC in people younger than 40 years and older than 65 years of age.

The etiology of oral squamous cell carcinoma is multifactorial which includes tobacco, alcohol, syphilis, sunlight, radiations, phenols, viruses, malnutrition and iron deficiency anemia. It is significantly associated with chewing of various forms of smokeless tobacco including snuff,

naswar, and betel quid with tobacco.

OSCC is the 2nd most common cause of cancer death in Pakistan. Despite advancement in treatment modalities, the 5 year survival rate of patients with OSCC is 45-50%. Thus evaluation of etiologic and risk factors like alcohol, tobacco and precancerous lesions are essential for early diagnosis. Prognosis depends or varies with tumor primary site, nodal involvement, tumor thickness, and the status of the surgical margins.

Hematoxylin and eosin (H & E) staining of tumor is one of the routine techniques used in histopathology for diagnosis of oral squamous cell carcinoma. Recent advances in OSCC

include molecular markers for oncogenes, tumor suppressor genes, cell proliferation markers, and intercellular adhesion molecules. These methods are used in precancerous lesions as a marker for an imminent malignancy. Main disadvantages of these methods are that, they are expensive, time consuming and need technical skill<sup>1</sup>.

The proliferative biomarkers include proliferating cell nuclear antigen (PCNA), Ki-67, histone argyrophilic nucleolar organizer regions (AgNORs) and for oncogenes C-myc, Thymidine Labeling Index (TLI), cyclins and cyclin dependent kinase (CDK), bromodeoxyuridine.

The argyrophilic nucleolar organizer region (AgNOR) staining technique was illustrated by Goodpasture and Bloom (1975) and was improved by Ploton. The count, size and form of nucleolar organizer regions can be determined easily with the help of argyrophilic nucleolar organizer region (AgNOR) stain.

Several studies reported that AgNOR counts are useful in differentiating odontogenic cysts and tumors, benign and malignant salivary gland tumors, hyperplastic, premalignant and malignant lesions of oral cavity.

In continuation with the previous studies, the aim of this study was to evaluate clinico-pathological parameters and AgNOR status in grading of oral squamous cell carcinoma by AgNOR staining.

## MATERIALS AND METHODS

The cross sectional study was selected as a study design on 50 cases of clinically diagnosed oral squamous cell carcinoma in the year 2009-2010. The specimens were collected from Mayo Hospital Lahore through surgical biopsies. The approval was taken from the ethical committee and written consent from patients was also obtained before collection of research data. Well-fixed surgical specimens in 10% formalin were collected from both genders and all ages suffering from oral squamous cell carcinomas of all histological grades and variants. Patients' history were collected in deigned proforma.

**Tissue Processing:** Tissues were processed in an automatic processor for 22 hours according to the following scheme. The sections after placing in ascending grades of alcohol i.e. 70%, 90% and absolute alcohol for 3 hours each, were given four washings of absolute alcohol, first two for 1 hour each and next two for 2 hours each. The tissues after giving two changes of xylene for 2 hours each were placed in wax bath for 3 hours to complete tissue processing. Tissues were embedded in paraffin wax using L-shaped molds. All the blocks were cut into multiple sections of 4 $\mu$ m thickness on a rotary microtome one by one. When the sections were cut, the frosted glass slides were used to take the section using APES (3-aminopropyltriethoxysilane) as adhesive. All the slides of the cases were divided into two batches and then each slide of both the batches was stained for hematoxylin and eosin and AgNOR.

**Tissue staining:** Harris's Hematoxylin solution was prepared by adding 2.5gm of hematoxylin powder in 25ml of absolute ethanol then 50gm of potassium alum was dissolved in 500ml of distilled water by heating. Both the solutions were mixed and heated to boiling point then 1.25 gm of mercuric oxide was dissolved in this solution. The solution was immediately cooled and 20ml of glacial acetic acid was added. The stain was stored in a stopper bottle. Eosin solution was prepared by dissolving 1gm of eosin powder in 200ml of distilled water. The sections were dewaxed for 4-5 minutes in xylene. The dewaxed slides were placed in each ascending grades of alcohol that is 70%, 90 % and absolute 1 minute followed by immersion of slides in Harris's hematoxylin for 10-15 minutes. The slides were then rinsed in tap water for 5-10 minutes, differentiated in 1% acid alcohol for 10-15 seconds and then again rinsed in tap water for 3-5 minutes. The tissue slides were then kept in eosin solution for 1-2 minutes, dehydrated in 70%, 90 % and absolute alcohol followed by clearance in xylene. The slides were then mounted with DPX mounting medium and observed under microscope. The findings were recorded in the proforma.

**Tumors grading system:** The nuclei and

cytoplasm of the cells were stained blue and pink respectively. Broder's classification of grading system was used to grade the oral squamous cell carcinoma. Grading is the histopathological evaluation of the degree to which tumors resemble to their parent tissue (squamous epithelium) and produce their product (keratin). Thus tumors are graded on three or four point (grades I to III/IV) scale. OSCC that strongly resembles normal squamous epithelium is called low-grade I or well-differentiated. Oral squamous cell carcinoma that includes abnormal mitoses, higher mitotic activity, nuclear pleomorphism and less keratin is called grade II or moderately differentiated while OSCC that contains immature cells along with typical or atypical mitoses and less or no keratin is called high-grade III/IV or poorly differentiated.

**AgNOR staining:** It contained solutions A and B. Solution A was made at 37°C by adding 2g gelatin and 1 ml formic acid in 100ml distilled water. Clear solution was obtained by dissolving and mixing the solution for about 10 minutes at 37°C. Solution B was prepared by adding 50% w/v silver nitrate in distilled water. Solution A and solution B were mixed with 1:2 ratios by volume to form working solution. The two solutions were mixed immediately before the staining procedure<sup>16</sup>. The slides were deparaffinized by heat and xylene for 5 minutes and descending alcohols concentration that is absolute, 70% and 50% for 1 minute each followed by rehydration with distilled water, post-fixation for 5 minutes in acid alcohol and rinsing with distilled water several times. The slides were then placed in silver nitrate solution in a dark room for 45 min at 37°C. The slides were rinsed in 6 changes of distilled water followed by immersion in 5% sodium thiosulphate for 3 minutes and rinsing with distilled water. The slides were then dehydrated with 50%, 70% and absolute alcohols, cleared in xylene, mounted in DPX and were observed under microscope using 4X, 10X, 40X<sup>14</sup>. The cells and nuclei were well visible. AgNORs dots were visible in brown or black color. The number, size and distribution of AgNORs were calculated in hundred (100) cells. Total three counts of AgNORs were carried out. The first and second counts were the mean

number of AgNORs in two hundred (200) tumor cells. Both intra and extra-nucleolar AgNOR dots, were counted. The third count was performed to examine the proliferative activity called proliferative index (pAgNOR). High proliferative rate of tumors was reflected by 5 or more AgNORs per nucleus. The grading of size variation and distribution of AgNORs were performed according to Khan.

#### Size Variation<sup>20</sup>

- 0 = More or less uniform in size
- 1+ = Two different sizes
- 2+ = More than two different sizes (but not those of 3+)
- 3+ = Including all grades and sizes

#### Distribution<sup>20</sup>

- 0 = Limited to nucleoli
- 1+ = Occasional dispersion outside nucleoli
- 2+ = Moderate dispersion outside nucleoli
- 3+ = Widely dispersed through the nucleus.

The data was entered and analyzed by using SPSS version 20. The mAgNOR was calculated by mean of first and second AgNOR counts. Proliferative index of AgNOR (pAgNOR) was calculated by counting five or more than five AgNOR dots in hundred nuclei. One-way ANOVA was used to assess the differences found in groups. The p-value was smaller than 0.05 ( $p < 0.05$ ).

## RESULTS

The study was conducted in the Department of Pathology at King Edward Medical University Lahore. The clinico-pathological parameters of OSCC were evaluated in terms of age, gender, risk factors, grades and variants of at time of presentation.

A total of 50 cases of oral squamous cell carcinoma were studied. In 50 cases of oral squamous cell carcinoma 28 (56%) were males and 22 (44%) were females and male to female ratio was 1.27:1 (Fig.1).

The maximum numbers of patients were seen in 50-60 years of age. The mean age of patients of oral squamous cell carcinoma was  $52 \pm 13.08$ . The minimum age of the patients was 20 and the maximum age was 80 (Fig.2).

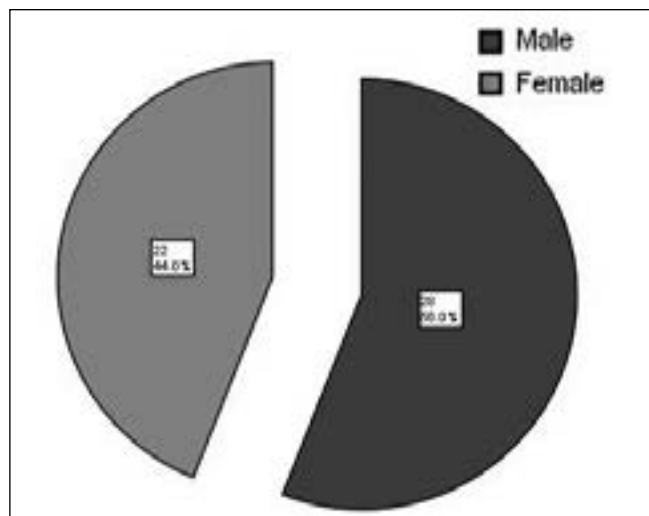


Figure-1. Gender of the Patients

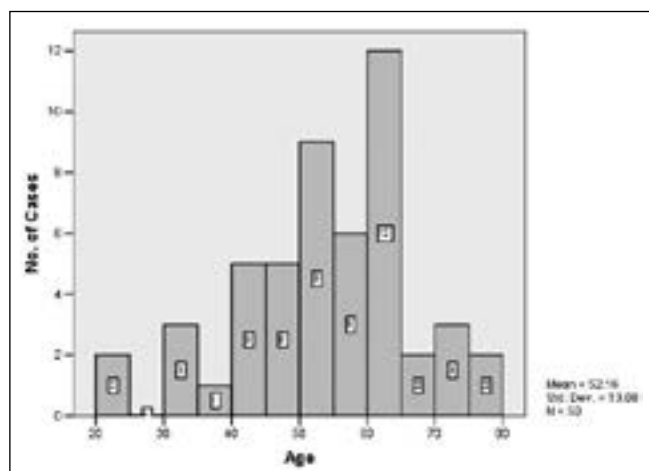


Figure-2. Age of the Patients

Among 50 cases of oral squamous cell carcinoma, 37 (74%) were well-differentiated squamous cell carcinoma, 6 (12%) were moderately differentiated, 3 (6%) were poorly differentiated squamous cell carcinoma (Fig. 3).

Out of 50 cases of oral squamous cell carcinoma, 4 (8%) patients had verrucous carcinoma (variant of oral squamous cell carcinoma as shown in Fig.5. In the present study the only risk factor which was significantly associated with oral squamous cell carcinoma was bidi  $p= 0.001$  ( $p<0.05$ ). Among bidi smokers; out of 37 cases of well differentiated squamous cell carcinomas, only 1 patient was ex-bidi smoker while 36 patients were those who never smoked bidi. In 6 case of moderately differentiated squamous cell

carcinomas, 1 was ex-bidi smoker and 5 were those who never smoked bidi. Among 3 cases of poorly differentiated squamous cell carcinoma, 2 were ex-bidi smokers while the remaining 1 never smoked bidi. Other risk factors such as smoking, huqqa, paan, tobacco, snuff and alcohol were found insignificant (Table I).

Mean AgNOR (mAgNOR) count was significantly less in well differentiated and moderately differentiated compared to poorly differentiated oral squamous cell carcinoma. AgNOR proliferative index (pAgNOR) also showed significant difference ( $p =0.001$ ). pAgNOR counts were high in poorly differentiated than moderately and well differentiated (Table II). AgNOR size in poorly differentiated was significantly of higher grade than AgNOR size in well differentiated (Table III). AgNOR distribution was significantly high in moderately and poorly differentiated (Table II). Mean AgNOR (mAgNOR), pAgNOR, AgNOR size and distribution showed no statistical significant differences between verrucous carcinoma and well differentiated squamous cell carcinoma ( $p > 0.05$ ) (Table V, Table V).

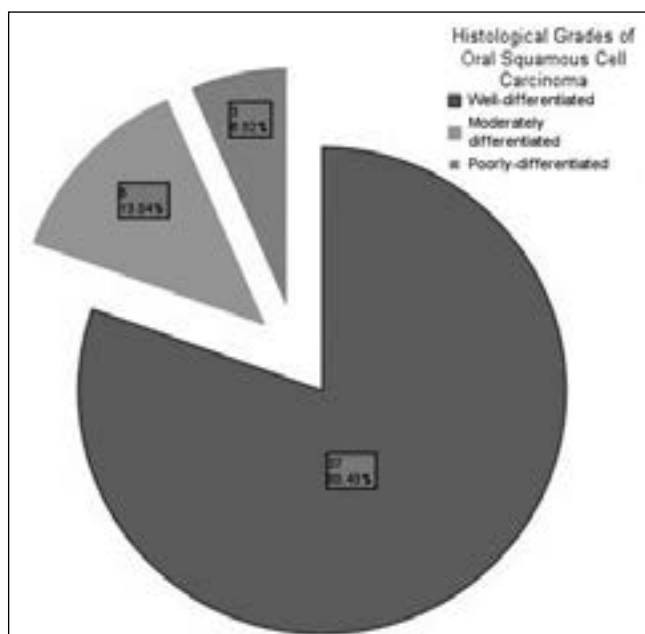
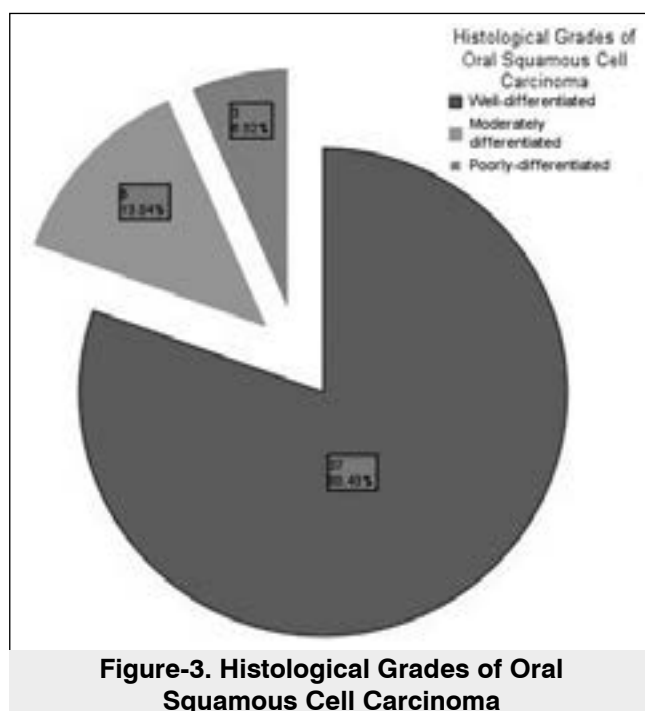


Figure-3. Histological Grades of Oral Squamous Cell Carcinoma



Risk Factors		Histological Grades of Oral Squamous Cell Carcinoma			Total	p-value
		Well differentiated (37)	Moderately differentiated (6)	Poorly differentiated (3)		
Cigarette Smoker	Never smoked	21	4	2	27	0.59
	Ex-smoker	5	0	1	6	
	Smoker	11	2	0	13	
Bidi Smoker	Never	36	5	1	42	0.001
	Ex-Bidi Smoker	1	1	2	4	
	Bidi Smoker	0	0	0	0	
Huqqa Smoker	Never	31	4	2	37	0.340
	Ex-Huqqa Smoker	3	0	0	3	
	Huqqa Smoker	3	2	1	6	
Paan	Never	18	3	3	24	0.462
	Ex-Paan	11	1	0	12	
	Paan	8	2	0	10	
Alcohol	No	30	6	2	38	0.396
	Yes	7	0	1	8	

**Table-I. Risk Factors Associated with Oral Squamous Cell Carcinoma**

AgNOR Parameters	Grades of Oral Squamous Cell Carcinoma	No. of Cases	Mean
Mean AgNOR Count (mAgNOR)	Well-differentiated	37	3.66±0.58
	Moderately differentiated	6	5.26±0.56
	Poorly-differentiated	3	7.04±0.65
	Total	46	4.09±1.11
AgNOR Proliferative Index (pAgNOR))	Well-differentiated	37	77.45±4.38
	Moderately differentiated	6	83.50±1.76
	Poorly-differentiated	3	85.00±5.00
	Total	46	78.73±4.88
Note:	p = .000 (mAgNOR) p = .001 (pAgNOR)		

**Table-II. mAgNOR and pAgNOR Counts in Histological Grades of Oral squamous Cell Carcinoma**

Histological Grades of Oral Squamous Cell Carcinoma	AgNOR Size			AgNOR Distribution		
	1+	2+	3+	1+	2+	3+
Well-differentiated (n=37)	37	0	0	0	33	4
Moderately differentiated (n=6)	0	4	2	0	0	6
Poorly differentiated (n=3)	0	0	3	0	0	3
Note:	AgNOR distribution in moderately differentiated and poorly differentiated (3+) was high compared to well differentiated (2+) and this difference was highly significant amongst histological grades of oral squamous cell carcinoma. (p= 0.000)					

**Table-III. AgNOR Size and AgNOR Distribution in different Histological Grades of Oral Squamous Cell Carcinoma**

AgNOR Parameters	Variants of Oral Squamous Cell Carcinoma	No. of Cases	Mean
Mean AgNOR Count (mAgNOR)	Verrucous Carcinoma	4	3.44±.540
	No Variant	46	4.09±1.11
	Total	50	4.04±1.09
AgNOR Proliferative Index (pAgNOR))	Verrucous Carcinoma	4	82.50±5.00
	No Variant	46	78.73±4.88
	Total	50	79.04±4.94

**Table-IV. mAgNOR and pAgNOR Counts in Variants of Oral squamous Cell Carcinoma**

*p = .256 (mAgNOR)      p = .147 (pAgNOR)*

Histological Variants of Oral Squamous Cell Carcinoma	AgNOR Size			AgNOR Distribution		
	1+	2+	3+	1+	2+	3+
Verrucous carcinoma (n+4)	4	0	0	0	4	0
No Variant (n+46)	37	4	5	0	33	13
Note:	p = 0.621			p = 0.287		

**Table-V. AgNOR Size and AgNOR Distribution in Variants of Oral Squamous Cell Carcinoma**



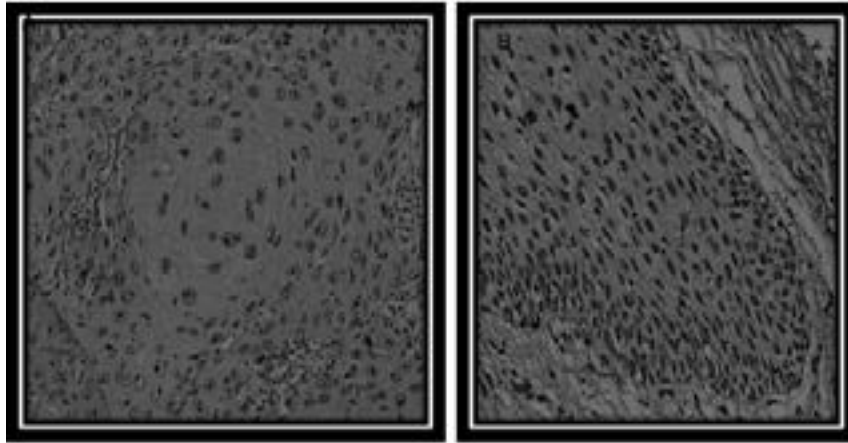


Figure 1: Photomicrograph showing AgNORs (20x AgNOR stain) in well differentiated (A) and Verrucous (B) Oral Squamous Cell Carcinoma with two different sizes, Occasional dispersion outside nucleoli with less rise in mAgNOR and pAgNOR




Figure 2: Photomicrograph showing AgNORs (20x AgNOR stain) in moderate differentiated Oral Squamous Cell Carcinoma with more than two different size

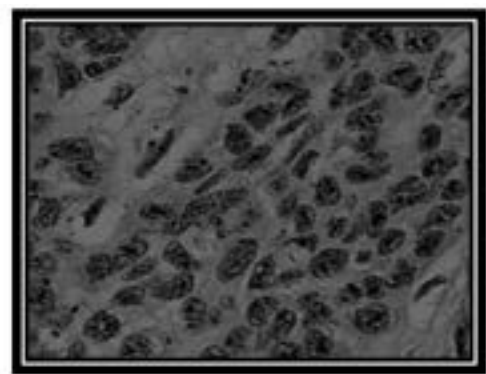


Figure: Photomicrograph showing AgNORs (20x AgNORs stain) in poorly differentiated Oral Squamous Cell Carcinoma with polymorphous sizes with higher grades, widely dispersed through the nucleus with high mAgNORs and pAgNORs

## DISCUSSION

Nucleolus organizing regions (NORs) is the part of deoxy ribonucleic acid known as ribosomal deoxy ribonucleic acid (rDNA). Ribosomal DNA is converted into ribosomal RNA (rRNA) by RNA-polymerase 1 enzyme<sup>14</sup>. The transcriptional activity of nucleolar organizer regions (NORs) is associated with acidic nonhistone, argyrophilic proteins which are stained by argyrophilic nucleolar organizer regions stain. They appear as black or brown colored dots under light microscope and are named as argyrophilic nucleolar organizer region or AgNORs<sup>15</sup>.

The aim of this study was to evaluate the AgNOR status in grading of oral squamous cell carcinoma. Out of 50 cases of histologically confirmed tissues

of oral squamous cell carcinomas, 37 (74%) were well-differentiated, 6 (12%) were moderately differentiated, 3 (6%) were poorly differentiated squamous cell carcinomas and 4 (8%) were verrucous carcinomas.

The age ranged from 20 to 80 years. The maximum numbers of patients found in 50-60 years. The mean age was  $52.16 \pm 13.08$ . Our results were comparable with the previous studies<sup>1</sup>.

The male to female ratio was 1.27:1. This ratio was comparable with the earlier reported studies on oral squamous cell carcinoma which showed male predilection<sup>2</sup>.

In the present study, risk factors such as

smoking, paan, huqqa, alcohol, snuff did not show significant association with oral squamous cell carcinoma. Similar study was carried out by Karin et al 2004 in which use of tobacco and alcohol were not associated with oral squamous cell carcinoma (OSCC) whereas in our study bidi showed a significant association with oral squamous cell carcinoma  $p=0.000$  ( $p<0.05$ ) which is in accordance with the earlier reported studies<sup>3,4</sup>.

In this study mean AgNOR count was  $3.66 \pm 0.58$  for well differentiated,  $5.26 \pm 0.56$  for moderately differentiated,  $7.04 \pm 0.65$  for poorly differentiated. The mean AgNOR count increased from well to moderately and poorly differentiated. The difference found in well, moderately and poorly differentiated squamous cell carcinoma was highly significant ( $p = .000$ ). It is in accordance with other studies<sup>5</sup>. pAgNOR in poorly differentiated squamous cell carcinoma ( $85 \pm 5.00$ ) was significantly high ( $p = 0.001$ ) compared to moderately differentiated ( $83 \pm 1.76$ ) and well differentiated ( $77 \pm 4.38$ ) squamous cell carcinoma<sup>6</sup>. The size and distribution grades of AgNORs found in poorly differentiated squamous cell carcinoma were significantly higher ( $p=0.000$ ) than in moderately and well differentiated squamous cell carcinoma which was similar to the earlier reported studies<sup>7</sup>.

Although the mAgNOR count was statistically significant, there was overlap of the counts between verrucous carcinoma and well differentiated squamous cell carcinoma, thus mAgNOR, pAgNOR were not significant in verrucous carcinoma ( $p > 0.05$ ) which was in accordance with the previous study<sup>8</sup>. No search was found in literature was found to compare AgNOR size and distribution. Therefore we recommend further studies on AgNOR size and distribution in verrucous carcinoma in order to make our results more valid.

## CONCLUSIONS

The results of the present study indicate that bid smoking is a risk factor of oral squamous cell carcinoma and hence prompt cessation is needed

in order to prevent this cancer. Also AgNOR count, pAgNOR, AgNOR size and distribution aided to distinguish well differentiated, moderately differentiated and poorly differentiated squamous cell carcinoma. Therefore we conclude that AgNOR stain plays a role in distinguishing histological grades of oral squamous cell carcinoma.

## Conflict of Interest

The authors declare that there is no conflict of interests.

## Acknowledgement

The authors are thankful for Dr Shahida Niazi for helping in our paper. They are also thankful for Professor Dr Muhammad Munir and Professor Samina Naeem for their help in using the Pathology Laboratory.

Copyright© 10 Nov, 2014.

## REFERENCES

1. Warnakulasuriya S: **Global epidemiology of oral and oropharyngeal cancer**. Oral Oncol 2009, 45(4-5):309-16.
2. Merchant A, Husain SS, Hosain M, Fikree FF, Pitiphat W, Siddiqui AR, et al. **Paan without tobacco: an independent risk factor for oral cancer**. International journal of cancer Journal international du cancer. 2000;86(1):128-31.
3. Sasaki T, Moles DR, Imai Y, Speight PM. **Clinico-pathological features of squamous cell carcinoma of the oral cavity in patients <40 years of age**. J Oral Pathol Med. 2005; 34:129-33.
4. Hirota SK, Migliari DA, Sugaya NN. **Oral squamous cell carcinoma in a young patient - Case report and literature review**. An Bras Dermatol. 2006; 81:251-4.
5. Johnson N. **Tobacco Use and Oral Cancer: A Global Perspective**. 2001; 65(4):328-39.
6. Walsh PM, Epstein JB. **The oral effects of smokeless tobacco**. J Can Dent Assoc. 2000; 66:22-25.
7. World Health Organization. **Global Action Against Cancer**. WHO library cataloguing in publication data. 2005; Available at: [www.who.org](http://www.who.org).
8. Bagan JV, Scully C. **Recent advances in Oral Oncology 2007: Epidemiology, aetiopathogenesis, diagnosis and prognostication**. Oral Oncol 2008; 44(2):103-8.
9. Benz Z, Pilch. **Text Book of Head and Neck Surgical**



- Pathology.** Lippincott, Williams and Wilkins. 2000; 41-4.
10. Garzino-Demo P, Dell'Acqua A, Dalmaso P, Fasolis M, La Terra Maggiore GM, Ramieri G, Berrone S, Rampino M, Schena M: **Clinicopathological parameters and outcome of 245 patients operated for oral squamous cell carcinoma.** J Craniomaxillofac Surg 2006 , 34(6):344-50.
  11. Young MR, Neville BW, Chi AC, Lathers DM, Boyd Gillespie M, Day TA. **Oral premalignant lesions induce immune reactivity to both premalignant oral lesions and head and neck squamous cell carcinoma.** Cancer immunology, immunotherapy : CII. 2007;56(7):1077-86.
  12. Young MR, Neville BW, Chi AC, Lathers DM, Gillespie MB, Day TA. **Autocrine motility-stimulatory pathways of oral premalignant lesion cells.** Clinical & experimental metastasis. 2007;24(2):131-9.
  13. Rosai J. **Rosai and Ackerman's Surgical Pathology.** 9th ed. St. Louis: Mosby. 2004; 1:p.66.
  14. Goodpasture C, Bloom SE. **Visualization of nucleolar organizer regions im mammalian chromosomes using silver staining.** Chromosoma. 1975;53(1):37-50.
  15. Ploton D, Menager M, Jeannesson P, Himber G, Pigeon F, Adnet JJ. **Improvement in the staining and in the visualization of the argyrophilic proteins of the nucleolar organizer region at the optical level.** The Histochemical journal. 1986;18(1):5-14.
  16. Bukhari MH, Niazi S, Khan SA, Hashmi I, Perveen S, Qureshi SS, et al. **Modified method of AgNOR staining for tissue and interpretation in histopathology.** International journal of experimental pathology. 2007;88(1):47-53.
  17. Eslami B, Rahimi H, Rahimi F, Khiavi MM, Ebadifar A. **Diagnostic value of silver nitrate staining for nucleolar organizer regions in selected head and neck tumors.** Journal of cancer research and therapeutics. 2006; 2(3):129-31.
  18. Elangovan T, Mani NJ, Malathi N. **Argyrophilic nucleolar organizer regions in inflammatory, premalignant, and malignant oral lesions: A quantitative and qualitative assessment.** Indian J Dent Res. 2008; 19(2):141-8.
  19. Akhter M, Hossain S, Rahman QB, Molla MR. **A study on histological grading of oral squamous cell carcinoma and its co-relationship with regional metastasis.** Journal of oral and maxillofacial pathology. 2011;15(2):168-76.
  20. Khan SA, Chaudhry NA, Khalid AW, Akhtar GN, Ibne-Rasa SN. **Patterns of argyrophilic nucleolar organizer regions in pleural and peritoneal effusions.** J Coll Physicians Surg Pak. 2006; 16:412-5.
  21. Andisheh-Tadbir A, Mehrabani D, Heydari ST. **Epidemiology of squamous cell carcinoma of the oral cavity in Iran.** J Craniofac Surg. 2008; 19(6):1699-702.
  22. Siriwardena BSMS, Tilakaratne A, Amaratunga EAPD. **Demographic, aetiological and survival differences of oral squamous cell carcinoma in the young and the old in Sri Lanka.** Oral Oncology. 2006; 42(8):831-6.
  23. Madani AH, Dikshit M, Bhaduri D. **Short Communication: Risk for oral cancer associated to smoking, smokeless and oral dip products.** Indian Journal of Public Health. 2012; 56(1): 57-60.
  24. Karin AR, Janet RD, Chu C, Karen JS, Stephen MS. **Marijuana use and risk of oral squamous cell carcinoma.** Cancer Research. 2004; 64:4049-54.
  25. Alarcón-Romero LC, Illades-Aguilar B, Flores-Alfaro E, Terán-Porcayo MA, Antonio-Véjar V, Reyes-Maldonado E. **AgNOR polymorphism association with squamous intraepithelial lesions and invasive carcinoma with HPV infection.** Salud pública Méx. 2009; 51(2):134-40.
  26. Ashraf MJ, Azarpira N, Safarzaghan Z, Tadbir AA, Khademi B. **Comparison of Ki67 and modified AgNOR in dysplastic epithelial lesion, primary squamous cell carcinoma and metastatic squamous cell carcinoma of head and neck.** Basic and Applied Pathology 2010; 3: 121–125.
  27. Kulkarni S, Mody RN, Jindal S, Sohi RS, Kaur B. **Silver binding nucleolar organiser regions in oral submucous fibrosis, lichen planus, leukoplakia and squamous cell carcinoma.** Journal of Cancer Research and Experimental Oncology Vol. 1(2) pp. 015-019.
  28. Epivatianos A. **Argyrophilic nucleolar organizer region associated proteins in human oral normal mucosa, verrucous carcinoma, and squamous cell carcinoma.** Ann Dent. 1995; 54(1):25-9.