



OVARIAN TUMORS; CDX2 IS NOT THE SOLE INDICATOR OF INTESTINAL ORIGIN CANCER IN PATIENTS PRESENTED WITH OVARIAN TUMORS

Jawad Ali Memon¹, Zubair Ali²

1. MS, FCPS
Assistant Professor
Department of Diagnostic
Radiology,
Peoples University of Medical and
Health Sciences for Women
(PUMHSW),
Shaheed Benazir Abad.
2. MRCP Specialty Certificate in
Medical Oncology, FCPS,
Consultant
Department of Medical Oncologist,
Aseer General Hospital Abha, Saudi
Arabia.

Correspondence Address:

Dr. Jawad Ali Memon
House no 130,
Farsi Bagh Sanghar Road
Nawabshah, Sindh.
jawad_nimra@yahoo.com

Article received on:

02/10/2017

Accepted for publication:

20/03/2018

Received after proof reading:

00/00/2018

ABSTRACT... Background: It is mandatory to distinguish between primary ovarian tumors and metastases, as the treatment and prognoses are wide apart. Immunohistochemistry is most frequently method being used to distinct these. Multiple studies showed that CDX2 is hallmark of the gut epithelium and is highly sensitive and specific immunohistochemical marker for neoplasms of gastrointestinal origin. **Objectives:** In this case series study we have clinically and radiologically evaluated the cases of ovarian tumors referred to our institute, which are reported metastatic from colon based on expression of CDX2 marker. **Study Design:** Cross sectional observational study. **Setting:** Peoples University of Medical and Health Sciences for Women (PUMHSW). Shaheed Benazir Abad. **Period:** Aug 2017 to September 2017. **Patients and Methods:** 12 patients which were undergone oophrectomy and biopsy reported as metastatic ovarian carcinoma from colon origin, based on histopathology features and CDX+ immunohistochemistry marker, were included in our study. All the patients evaluated through detailed clinical history and examination, upper and lower GI endoscopy, CT scan whole abdomen with contrast and tumor markers including CA 125, CEA, CA 19.9 and AFP). **Results:** No history of GIT specific symptoms like vomiting, constipation, diarrhea, bleeding per rectum were noted in any patient. Upper and lower GIT endoscopies failed to identify any suspicious lesion. No bowel related mass or wall thickening noted in CT scan abdomen with contrast. The serum level of CA 125 and CEA were only mildly raised in most patients. No evidence of primary colon lesion was noted in these patients inspite of extensive workup. Eventually the patients were labeled and treated as primary carcinoma of ovary. **Conclusions:** CDX2 cannot be used as sole indicator of colon origin and panel of the markers should always be employed, and clinical as well as radiological features should also be considered during interpretation of IHC results.

Key words: CA 125, CDX2, Metastatic Colon Carcinoma, Ovarain Tumor.

Article Citation: Memon JA, Ali Z. Ovarian tumors; CDX2 is not the sole indicator of intestinal origin cancer in patients presented with ovarian tumors. Professional Med J 2018; 25(9):1334-1337. DOI:10.29309/TPMJ/18.4395

INTRODUCTION

Ovarian carcinoma is the most common cause of cancer death from gynecologic tumors in the United States.¹ Of all ovarian malignancies, 15% reported to be metastatic in origin. The gastrointestinal tract was the most common primary site (39%).² It is mandatory to distinguish between primary ovarian tumors and metastases, as the treatment and prognoses are wide apart. Among ovarian tumors, the primary epithelial cancers offer the greatest problem in differentiation of primary from metastatic tumors. It is histopathologically very difficult to characterize primary ovarian and secondary ovarian carcinomas when specific gross and microscopic features are deficient.^{3,4,5} Immunohistochemistry is most frequently method being used to distinct these.^{6,7} Multiple

studies showed that CDX2 is hallmark of the gut epithelium and is highly sensitive and specific immunohistochemical marker for neoplasms of gastrointestinal origin.⁸⁻¹³ Multiple studies also demonstrate expression of CDX2 in multiple genito urinary and gynecological cancer, especially the mucinous ovarian carcinomas.^{14,15,16} In the present study we have clinically and radiologically evaluated the cases of ovarian tumors, which are reported metastatic from GIT based on expression of CDX2 marker.

MATERIALS and METHODS

After approval of ethical committee of the institute and taking patients informed consent, we have retrospectively included and analyzed 12 patients which were referred in our hospital

after hysterectomy and bilateral oophorectomy. The biopsy report showed adenocarcinoma ovary marked as metastatic from GIT based on CDX2 expression. The histopathological and immunohistochemical features are summarized in Table-I. The presenting symptoms, GIT endoscopic findings, and radiologically scan findings were noted and analyzed.

Bilateral ovarian adenocarcinoma	8	66%
Unilateral ovarian adenocarcinoma	4	33%
Omental metastases	10	83%
Mucin producing	11	91%
Well differentiated	10	83%
Poorly differentiated	2	16%
CK-7	2	16%
CK-20	12	100%
CDX2	12	100%

Table-I. The histopathological and immunohistochemical features of the patients

RESULTS

The patients age ranges between 22 to 42 years with mean age is 32.5 years (Figure-1). Most of the patients presents with abdominal distension (50%), menstrual irregularity or both (Figure-2). All patients denied of constipation, diarrhea or per rectal bleeding. Upper and lower GIT endoscopies are unremarkable of all patients. The CEA and CA-125 are mildly raised in all cases (mean CEA 44.5ng/ml and CA-125 70 u/ml).

AGE DISTRIBUTION (YEARS)

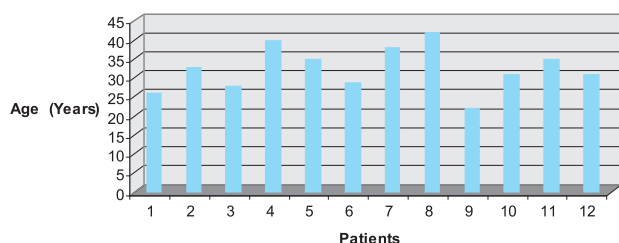


Figure-1. The Age distribution of the patients

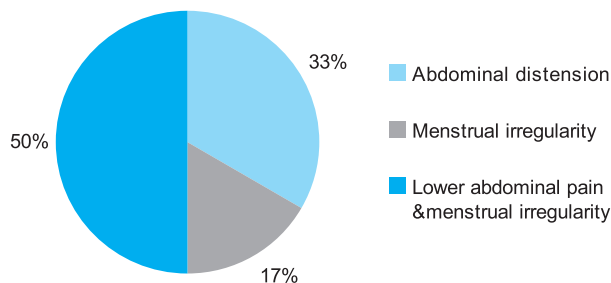


Figure-2. The clinical features of the Patients

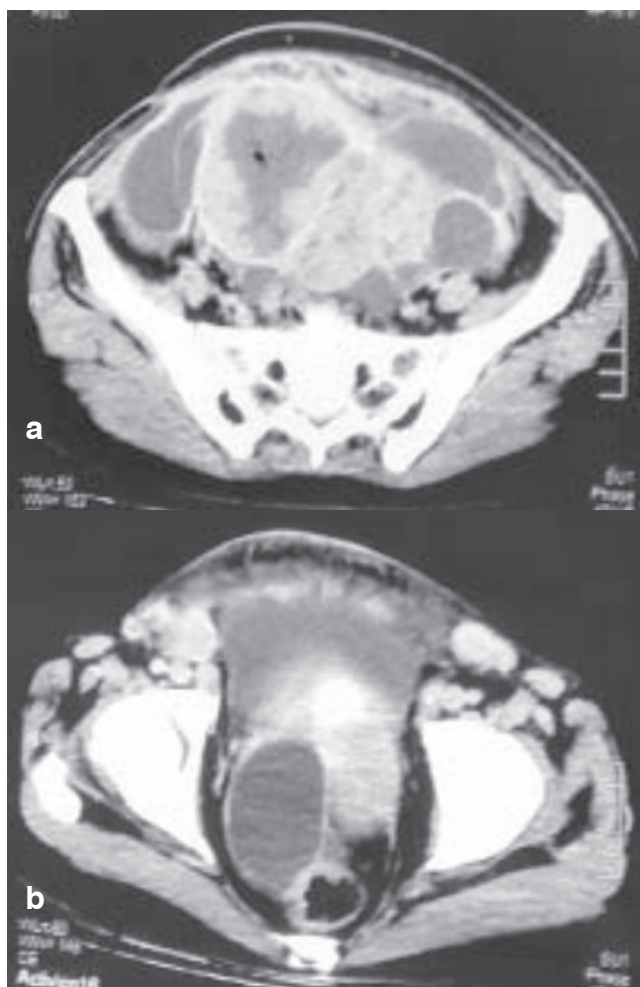

Figure-3. C.T scan shows (a) enhancing multiseptated cystic mass noted in pelvis (b) abutting and compression the rectosigmoid colon and urinary bladder

Pre-operative CT Scan Findings

Most of the patients show typical findings of carcinoma ovary. These include enhancing capsulated multiseptated predominantly cystic mass in pelvis extending into lower abdomen, displacing and compressing the urinary bladder. The mass is displacing the bowel loops superiolaterally and abutting the rectosigmoid colon. It is associated with ascites and omental caking/thickening. No definite colonic mass or thickening noted (Figure-3). Post operative scan also show no definite bowel related mass.

After extensive clinical and radiological evaluation no definite colonic related pathology noted and these patients are labeled as primary carcinoma of ovary and treated accordingly.

DISCUSSION

Though the role of histopathology is confirmative in diagnoses of carcinoma of ovary but to differentiate between primary and secondary ovarian cancers especially from colorectal carcinomas is very difficult and, both look similar histologically. The histological points favoring metastatic ovarian carcinoma rather than primary carcinomas are the bilaterality, a nodular pattern of ovarian surface involvement, garland or cribriform pattern and focal segmental necrosis of glands. These characteristic features are not always found in every case, in this situation use of immunohistochemistry is of great help and Ck7, Ck20, Cdx2 and many other markers are reported to be useful in distinguishing primary ovarian carcinoma from metastases of colorectal carcinoma origin.^{17,18} The compound expression of Ck7/Ck20 is the most widely used marker. Ovarian carcinomas are usually Ck7+/Ck20- whereas colorectal carcinomas are usually Ck7-/Ck20+, further more the CDX2 is considered to be specific for intestine origin cancers.⁸⁻¹³ Nevertheless, these markers are not 100% sensitive and specific. Multiple case studies show Ck20 expression in primary carcinoma ovary and Ck7 expression in primary colonic carcinomas.¹⁷⁻¹⁹ Expression of CDX2 has been reported in multiple tumors besides colorectal carcinoma.^{14,15,16} This warrant consolidates approach taking into account of clinical, radiological and histological findings are mandatory.

The current study is the first clinical and radiological analyses of the patients presented with ovarian tumors and labelled as metastases from GIT based on expression of CDX2. The results demonstrate all tumors which are positive for CDX2 are not of intestinal origin. The mean age of our patients is 32.5 years and ranges between 22 to 42 years. The primary ovarian tumors are more common in younger age as compared to metastatic.²⁰ Most of our patients complained of abdominal distention and menstrual problems, these are the most common symptoms of the primary ovarian carcinoma.^{21,22} Not single patient presented with specific GIT related symptom and also the upper and lower GIT endoscopies found unremarkable. The CT scan findings also

suggestive of primary ovarian carcinomas and no definite colon related mass or bowel thickening noted.

CONCLUSION

CDX2 cannot be used as sole indicator of colon origin and panel of the markers should always be employed, and clinical as well as radiological features should also be considered during interpretation of IHC results.

Copyright© 20 Mar, 2018.


REFERENCES

1. Trupti S. Patel, Chinton Shah, Majal C. Shah, Manoj J. Shah. **Axillary node metastasis from primary ovarian carcinoma.** J Cytol. 2014 Oct-Dec; 31(4): 202-204.
2. de Waal YR, Thomas CM, Oei AL, Sweep FC, Massuger LF. **Secondary ovarian malignancies: Frequency, origin, and characteristics.** Int J Gynecol Cancer. 2009 Oct; 19(7):1160-5.
3. Young RH. **From krukberg to today: The ever present problems posed by metastatic tumors in the ovary: part I. Historical perspective, general principles, mucinous tumors including the krukberg tumor.** Adv Anat Pathol 2006; 13(5):205-227.
4. Seidman JD, Kurman RJ, Ronnett BM. **Primary and metastatic mucinous adenocarcinomas in the ovaries: incidence in routine practice with a new approach to improve intraoperative diagnosis.** Am J Surg Pathol 2003; 27(7):985-993.
5. Lee KR, Young RH. **The distinction between primary and metastatic mucinous carcinomas of the ovary: Gross and histologic findings in 50 cases.** Am J Surg Pathol 2003 Mar; 27(3):281-92.
6. Mc Cluggage WG. **Recent advances in immunohistochemistry in gynecological pathology.** Histopathology 2002; 40:309-326.
7. Mc Cluggage WG. **Recent advances in immunohistochemistry in the diagnosis of ovarian neoplasms.** J Clin Pathol 2000 May; 53(5):327-334.
8. Vang R, Gown AM, Barry TS, et al. **Cytokeratins 7 and 20 in primary and secondary mucinous tumors of the ovary: Analysis of coordinate immunohistochemical expression profiles and staining distribution in 179 cases.** Am J Surg Pathol 2006 Sep; 30(9):1130-9.
9. Almeida R, Silva E, Santos-Silva F, et al. **Expression of intestine-specific transcription factors, CDX1 and CDX2, in intestinal metaplasia and gastric**

carcinomas. *J Pathol* 2003 Jan; 199(1):36–40.

10. Bai YQ, Yamamoto H, Akiyama Y, et al. **Ectopic expression of homeodomain protein CDX2 in intestinal metaplasia and carcinomas of the stomach.** *Cancer Lett* 2002; 176:47–55.
11. Cathro HP, Mills SE. **Immunophenotypic differences between intestinal-type and low-grade papillary sinonasal adenocarcinomas: An immunohistochemical study of 22 cases utilizing CDX2 and MUC2.** *Am J Surg Pathol* 2004; 28: 1026–1032.
12. ChuPG, SchwarzRE, LauSK, et al. **Immunohistochemical staining in the diagnosis of pancreatobiliary and ampulla of Vater adenocarcinoma: Application of CDX2, CK17, MUC1, and MUC2.** *Am J Surg Pathol* 2005; 29(3):359–367.
13. Hansel DE, Maitra A, Lin JW, et al. **Expression of the caudal-type homeodomain transcription factors CDX 1/2 and outcome in carcinomas of the ampulla of Vater.** *J Clin Oncol* 2005; 23(3):1811–1818.
14. Park KJ, Bramlage M, Pirog EC, et al. **CDX2 immunohistochemical staining patterns in mucinous neoplasms of the female genital tract [Abstract].** *Mod Pathol* 2005; 18:199A.
15. Moskaluk CA, Zhang H, Powell SM, et al. **Cdx2 protein expression in normal and malignant human tissues: An immunohistochemical survey using tissue microarrays.** *Mod Pathol* 2003; 16(9):13–919.
16. Raspollini MR, Amunni G, Villanucci A, et al. **Utility of CDX-2 in distinguishing between primary and secondary (intestinal) mucinous ovarian carcinoma: An immunohistochemical comparison of 43 cases.** *Appl Immunohistochem Mol Morphol* 2004; 12: 127–131.
17. McCluggage WG, Wilkinson N. **Metastatic neoplasms involving the ovary: a review with an emphasis on morphological and immunohistochemical features.** *Histopathology* 2005; 47:231-247.
18. Logani S, Oliva E, Arnell PM, Amin MB, Young RH. **Use of novel immunohistochemical markers expressed in colonic adenocarcinoma to distinguish primary ovarian tumors from metastatic colorectal carcinoma.** *Mod Pathol*, 2005; 18:19-25.
19. Ji H, Isacson C, Seidman JD, Kurman RJ, Ronnett BM. **Cytokeratins 7 and 20, Dpc 4, and MUC5AC in the distinction of metastatic mucinous carcinoma in the ovary from primary ovarian mucinous tumors: Dpc 4 assists in identifying metastatic pancreatic carcinomas** *Int J Gynecol Pathol*, 2002; 21(4): 391-400.
20. Lack EE, Young RH, Scully RE. **Pathology of ovarian neoplasms in childhood and adolescence.** *Pathol Annu.* 1992; 27:281–356.
21. Goff BA, Mandel LS, Drescher CW, Urban N, Gough S, Schurman KM, et al. **Development of an ovarian cancer symptom index: Possibilities for earlier detection.** *Cancer.* 2007 Jan 15. 109(2):221-7.
22. Ryerson AB, Ehemann C, Burton J, McCall N, Blackman D, Subramanian S, et al. *Obstet Gynecol.* 2007 May. 109(5):1053-61.

AUTHORSHIP AND CONTRIBUTION DECLARATION

Sr. #	Author-s Full Name	Contribution to the paper	Author=s Signature
1	Jawad Ali Memon	Data collection, article writing (75%)	
2	Zubair Ali	Concept and Proof reading (25%)	