



1. MBBS, M. Phil (Histopathology)
Assistant Professor Pathology,
Multan Medical & Dental College,
Multan.
2. MBBS
Resident Doctor In Histopathology
Shokat Khanam Hospital, Lahore.
3. MD
Pathologist
Morristown,
Overlook and Newton Medical
Centers
Atlantic Consolidated Laboratory
100 The American Road,
Morris Plains, NJ 07950

Correspondence Address:

Afra Samad
Address: House No.68. Street No. 2.
Mehrban Colony.
Near MDA Chowk. Multan.
afrasamad@yahoo.com

Article received on:

18/07/2017

Accepted for publication:

05/11/2017

Received after proof reading:

31/01/2018

HETEROTOPIC SALIVARY GLAND; A CASE REPORT IN ILEUM LEADING TO INTESTINAL OBSTRUCTION & INTUSSUSCEPTION.

Afra Samad¹, Madiha Syed², Arbaz Samad³

ABSTRACT... Background: Salivary glands heterotopia is defined as presence of salivary gland tissue outside its normal location.¹ Salivary gland heterotopia in ileum leading to obstruction & intussusception is extremely rare. Only two such cases have been reported previously. **Case Report:** We report a case of 2 years old male who presented with history of vomiting, constipation and bleeding per rectum for one week. Clinical impression was intestinal obstruction and intussusception. An emergency exploratory laparotomy was performed and intraluminal ileal polyp was resected. Histopathological examination of the excised polyp demonstrated salivary gland tissue. **Conclusion:** Though extremely rare heterotopic salivary gland should be considered in differential diagnosis of intestinal obstruction and intussusception.

Key words: Heterotopia, Ileum, Intussusceptions.

Article Citation: Samad A, Syed M, Samad A. Heterotopic salivary gland; A case report in ileum leading to intestinal obstruction & intussusception. Professional Med J 2018;25(2):332-334. DOI:10.29309/TPMJ/18.4170

INTRODUCTION CASE REPORT

A two year old male child presented with one week history of vomiting, constipation and bleeding per rectum. On clinical examination, abdomen was tender and tense with absence of audible bowel sounds. Clinical suspicion was intestinal obstruction and intussusception. The patient underwent exploratory laparotomy and an intraluminal ileal polyp was found and resected. Specimen was submitted for histopathological examination. On gross examination polyp measured 1.5x1.0x1.0 cm. Cut surface was gray white in colour. Microscopic examination of polyp revealed polypoid fragment of small intestinal mucosa with ulceration and submucosal serous type salivary gland acini arranged in lobules with interspersed ducts. No evidence of malignancy was noted. A rare diagnosis of heterotopic salivary gland forming intraluminal ileal polyp was rendered.

DISCUSSION

Salivary gland heterotopia also called accessory salivary gland or choristome is defined by the presence of salivary gland tissue outside of its

normal location.¹

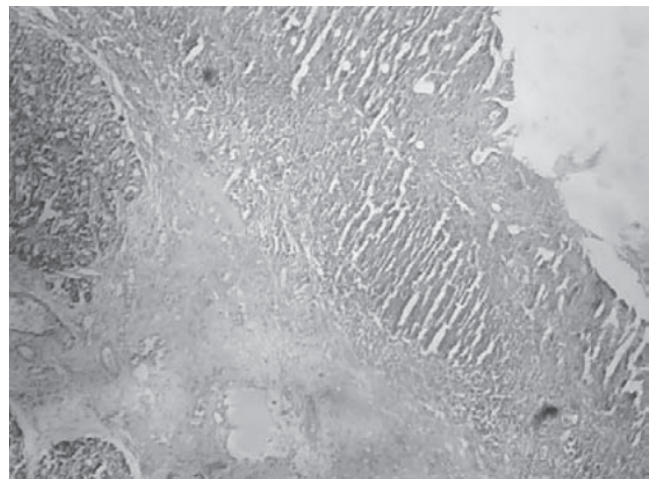


Figure-1. Salivary gland tissue involving mucosa and sub-mucosa of ileum with ulceration of overlying epithelium. (Magnification100X)

Salivary gland heterotopia is classified into two categories; intranodal and extranodal.² Intranodal variety is the most common. In infants salivary gland tissue is present in almost all lymph intraparotid and periparotid lymph nodes.³ Medulla of the lymph nodes is the most common site where salivary gland tissue is usually identified. Mostly it consists of intercalated and intralobular

ducts. However, in some cases serous acini and immature appearing small ducts can be present.⁴

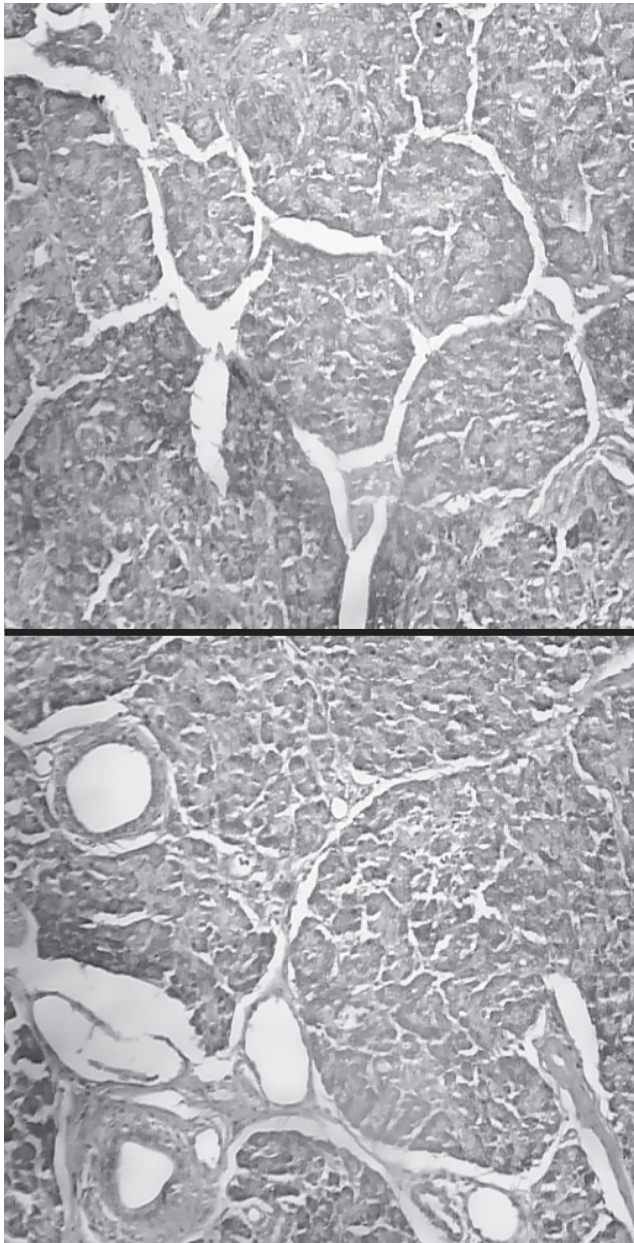


Figure-2 &3. Serous type salivary gland acini arranged in lobular architecture with interspersed ducts. (Magnification 400X)

On the basis of anatomic location in the head and neck; extranodal salivary gland heterotopia has been classified into high and low forms. High form includes mandible, ear, palatine tonsil, mylohyoid muscle, pituitary gland and cerebello-pontine angle. Low heterotopic salivary glands are associated with branchial pouches,

cysts and sinuses in the lower neck and thyroid gland.^{5,6,7} These are most commonly found along medial border of sternocleidomastoid.⁷ Other reported sites are stomach, rectum and vulva. But presence of salivary gland in ileum is extremely rare condition. The exact cause of heterotopia of salivary glands is not known but some theories suggest that heterotopia is either due to abnormal persistence of vestigial structures and misplacement of salivary gland rest along embryological pathways of migration during development or may be result from the differentiation of primitive embryologic remnants.⁷ Heterotopic salivary gland may also develop pathological changes such as ductal hyperplasia, oncocytic metaplasia, cyst formation and neoplasm. Among neoplasms Warthin's tumor is the most common.

CONCLUSION

This case highlights a very rare presentation of heterotopic salivary glands in ileum. Though extremely rare heterotopic salivary glands should be considered in differential diagnosis of intestinal obstruction and intussusception.

Copyright© 05 Nov, 2017.

REFERENCES

1. Wiu RL. **Salivary gland diseases: Surgical & medical management** 2011: 50-51.
2. Martinez- Madrigal F, Bosq J, Casiraghi O. **Major salivary glands.** In Mills SE (ed) **Histology for pathologists**, ed 3. Philadelphia, Lippincott Williams &Wilkins 2007:445-69.
3. Barnes L. **Surgical Pathology of Head & Neck New York:** Informa Health Care 2008: 477-78.
4. Ghom AG, Ghom SA. **Textbook of oral medicine.** JP Medical Limited 2014:605.
5. Bouquot JC, Gnepp DR, Dardick I. *Oral Surg Oral Med Oral Pathol Oral Radiol* 2009; 90:205-17. [Pubmed]
6. Shinohara M, Harada T, Na kawura S, Oka M, Tashiro H: **Heterotopic salivary gland tissue in lymph nodes of the cervical region.** *Int J oral Maxillofacial Surg* 1992; 21:166-71.
7. Carney JA. **Salivary gland heterotopia, cysts & the parathyroid gland: Branchial pouch derivatives & remnants.** *Am J Surg Pathol* 2000; 24:837-45.

Surgery

4th Edition | Volume-I

TELL ME THE ANSWER



Muhammad Shuja Tahir

AUTHORSHIP AND CONTRIBUTION DECLARATION

| Sr. # | Author-s Full Name | Contribution to the paper | Author=s Signature |
|-------|--------------------|---------------------------|---------------------|
| 1 | Afra Samad | 1st Author | <i>Afra Samad.</i> |
| 2 | Madiha Syed | 2nd Author | <i>Madiha Syed.</i> |
| 3 | Arbaz Samad | 3rd Author | <i>Arbaz.</i> |