



PATENT DUCTUS ARTERIOSUS DEVICE OCCLUSION; IMMEDIATE RESULTS AND COMPLICATIONS.

1. (MBBS, FCPS Paediatrics, FCPS Paeds Cardiology)
Assistant Professor
Department of Paediatric Cardiology,
Ch. Pervaiz Elahi Institute of Cardiology Multan.
2. (FCPS Paediatrics, FCPS Paeds Cardiology),
Assistant Professor and Head
Department of Paeds Cardiology,
Ch. Pervaiz Elahi Institute of Cardiology Multan.
3. MBBS, FCPS Paediatrics, FCPS Paeds Cardiology)
Assistant Professor
Department of Paeds Cardiology,
Ch. Pervaiz Elahi Institute of Cardiology Multan.
4. (M. Phil Psychology),
Chief Cath Lab Technician,
Ch. Pervaiz Elahi Institute of Cardiology Multan.

Correspondence Address:
Dr. Touseef Asma Chaudhry
(MBBS, FCPS Paediatrics, FCPS Paeds Cardiology)
Assistant Professor
Department of Paediatric Cardiology,
Ch. Pervaiz Elahi Institute of Cardiology Multan.
asmach@msn.com

Article received on:
22/02/2017

Accepted for publication:
15/11/2017

Received after proof reading:
31/01/2018

INTRODUCTION

Patent ductus arteriosus (PDA) is the most common of all congenital lesions. It occurs when the ductus arteriosus that connects the descending aorta with pulmonary arteries (in fetal life) did not close within ten days of child birth.¹ Transcatheter closure of PDA was first time defined in 1967.² Occlusion of PDA by using coils and Amplatzer duct occluder (ADO) began in 1992.³ Various type of occlusion devices has been developed since date, out of which coils and ADO are still most commonly used devices for occlusion of small and moderate to large sized PDA. SHSMA occluder has also been used in our institution for occlusion of moderate to large sized

Touseef Asma Chaudhry¹, Muhammad Younas², Ahsan Beg³, Muhammad Ameen⁴

ABSTRACT... Objectives: To determine immediate outcomes and complication rate of transcatheter closure of patent ductus arteriosus. **Study Design:** Retrospective analysis. **Setting:** CPE Institute of cardiology. **Period:** 2009 to May 2016. **Materials and Methods:** Two hundred and seventy four (274) results of transcatheter occlusion of PDA performed by pediatric cardiologists. All patients who underwent PDA occlusion regardless of their weight either by ADO device or SHSMA occlude were included for analysis. SPSS V23 was used for data processing. Frequency was calculated for qualitative variables and mean for quantitative ones. **Results:** The mean age of study participants was 9.57+8.82 years. There was female predominance with 65.7% females and 34.3% males. Regarding severity of PDA, 90 (32.8%) patients were presented with large PDA, 70 (25.5%) with moderately large PDA, 107 (39.1%) with moderate PDA and only 6 (2.2%) were presented with small sized PDA. Classical conical shaped PDA was most common manifestation, diagnosed in 66.8% patients and long ampulla shaped in 70 (25.5%) patients. Regarding complications, device embolization occurred in one patient. Residual PDA in catheterization lab was present in 4 (1.5%) patients. Radial pulse loss occurred in 6 (2.2%) patients for which heparin infusion was started until the pulse became palpable. Blood transfusion was required in 3 (1.1%) patients due to excessive blood loss during the procedure. Mild left pulmonary artery obstruction due to protrusion of pulmonary end of device occurred in 2 (0.7%) patients. Device protrusion into aorta was noted in only 16 (5.8%), in all of these patients there was no aortic flow obstruction. Overall success rate was 99.63%. There was no procedure related mortality. **Conclusion:** Percutaneous patent ductus arteriosus closure is safe with minimum number of complications. Pulse loss, protrusion o aortic end of device into aorta and residual PDA in cath lab (resolved within 24 hours) are common procedural complications.

Key words: Patent Ductus Arteriosus, PDA Device, Transcatheter Closure.

Article Citation: Chaudhry TA, Younas M, Beg A, Ameen M. Patent ductus arteriosus device occlusion; immediate results and complications. Professional Med J 2018; 25(2):232-236. DOI:10.29309/TPMJ/18.3897

PDA and has shown excellent results.⁴

All these devices have success rate more than 97% with minimum number of complications.⁵⁻⁷ But some complications have been reported by previous studies during transcatheter insertion of device and in immediate follow up period. Therefore we conducted this study to see immediate outcomes and complications of transcatheter closure of PDA in our setup.

MATERIALS AND METHODS

This study was a retrospective analysis of two hundred and seventy four (274) results of transcatheter occlusion of PDA performed

by pediatric cardiologists in CPE Institute of cardiology. The data of patients from 2009 to May 2016 was retrieved. All patients who underwent PDA occlusion regardless of their weight either by ADO device or SHSMA occlude were included for analysis. ADO device was inserted in 130 patients and SHSMA occluder was inserted in 144 patients. Data of pre-procedural variables were obtained from pre-procedural echocardiography reports of patients.

All device implantations were done through femoral artery under heavy sedation by local anesthesia and heparin was used for anti-coagulation. PDA occlusion device was inserted through a 5-7 Fr sheath. The device size was selected having 2 mm larger pulmonary end than the narrowest portion of PDA. Aortic and pulmonary artery pressures were noted before implantation of the device. PDA size was reconfirmed under fluoroscopy before selection of device for insertion. PDA occlusion devices sizes are shown in Table-I. After insertion of PDA occluder, residual PDA was evaluated in cath lab. All pulses were checked to evaluate any pulse loss. In case of pulse loss, heparin infusion was started until the pulse became palpable. On 1st post-operative day echocardiography was done to evaluate any residual PDA, and protrusion of PDA device into aorta or into the pulmonary artery. Complication rate was noted for every patient. 3 days antibiotic therapy was given to every patient for infection prevention.

SPSS V23 was used for data processing. Frequency was calculated for qualitative variables and mean for quantitative ones.

RESULTS

Pre-procedural variables of patients are presented in Table-I. The mean age of study participants was 9.57+8.82 years. There was female predominance with 65.7% females and 34.3% males. There were 87.2% patients who presented with left ventricular volume overload. Mean PDA size was 4.43+1.70 mm. Regarding severity of PDA, 90 (32.8%) patients were presented with large PDA, 70 (25.5%) with moderately large PDA, 107 (39.1%) with moderate PDA and only 6 (2.2%)

were presented with small sized PDA. 63 (23.0%) patients were presented with recurrent chest infections and 36 (13.1%) with tachypnea (Table-II). Regarding shape of PDA, classical conical shaped PDA was most common manifestation, diagnosed in 67% patients and long ampulla shaped PDA was diagnosed in 70 (25%) patients (Figure-1).

Size	Frequency	Percentage
6/4	28	10.2
6/8	5	18.2
8/6	112	40.9
8/10	4	1.45
10/8	70	25.5
10/12	3	1.0
12/10	27	9.8
14/12	16	5.8
16/14	6	2.2
18/16	3	1.0

Table-I. Size of PDA devices used in this study.

Variables	Values
Number	274
Age	9.57+8.82
Weight	24.78+16.54
Gender (%)	
Male	94 (34.3)
Female	180 (65.7)
Echocardiographic Characteristics	
PDA Size (mm)	4.43+1.70
Gradient Across PDA (mmHg)	93.30+16.63
LVVO (%)	239 (87.2)
LVEDD (mm)	44.21+9.29
Severity of PDA (%)	
Small	6 (2.2)
Moderate	107 (39.1)
Moderately Large	70 (25.5)
Large	90 (32.8)
Hematologic Variables	
Hemoglobin (g/dl)	10.87+1.91
TLC	10.36+7.68
Platelet Count	336.30+112.2
Recurrent Chest Infections (%)	63 (23.0)
Tachypnea (%)	36 (13.1)

Table-II. Pre-Procedural variables

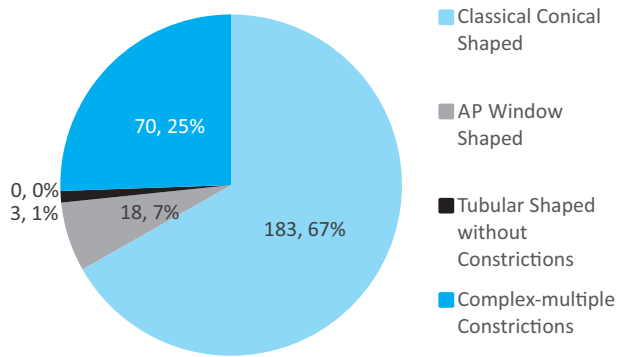


Figure-1. Type of PDA according to Krichenko classification.

Mean fluoroscopy time was 13.25+4.91 minutes and mean procedural time was 44.34+7.29 minutes. Regarding complications of PDA, device embolization occurred in one patient. Residual PDA in catheterization lab was present in 4 (1.5%) patients, all were closed within 24 hours after the procedure. Radial pulse loss occurred in 6 (2.2%) patients for which heparin infusion was started until the pulse became palpable. In all patients, pulse reappeared within 24 hours. Blood transfusion was required in 3 (1.1%) patients due to excessive blood loss during the procedure. Mild left pulmonary artery obstruction due to protrusion of pulmonary end of device occurred in 2 (0.7%) patients, but this obstruction was insignificant. Device protrusion into aorta was noted in only 16 (5.8%), in all of these patients there was no aortic flow obstruction. There was no incidence of accidental device separation and procedural mortality. Overall success rate was 99.63%. There was no procedure related mortality (Table-IV).

Variables	Value
Pre-occlusion Aortic Root Pressure (mmHg)	117.00+20.09
Pre-occlusion Pulmonary Artery Pressure (mmHg)	43.91+15.24
Fluoroscopy Time (min)	13.25+4.91
Procedural Time (min)	44.34+7.29

Table-III. Angiographic characteristics and procedural complications.

LVVO=left ventricular volume overload, LVEDD=left ventricular end diastolic dimension, TLC=total leukocyte count.

Variables	Frequency	Percentage
Device Embolization	1	0.4
Accidental Device separation	0	0.0
Residual PDA in Cath Lab	4	1.5
Pulse loss	6	2.2
Mild LPA obstruction due to device protrusion	2	0.7
Protrusion of device into aorta	16	5.8
Blood Transfusion	3	1.1
Mortality	0	0.0

Table-IV. Frequency of procedural complications.

DISCUSSION

After 1st successful closure of PDA by Parstmann in 1967, a number of devices and coils have been introduced for PDA closure.² Now transcatheter PDA closure has become a standard method of PDA closure. Numerous efforts have been made to improve devices for PDA closure; these include ADO device, Rashkind device, SHSMA occlude and Gianturco coil.^{5,8-10} Every device has good results with some number of complications. The major drawbacks of these devices are complex and large delivery systems, residual shunts after placement of device and procedural length.⁷ ADO device is most commonly used device for transcatheter PDA closure worldwide. Zulqarnain et al. showed excellent results with the use of SHSMA occluder.⁴ In our center ADO and SHSMA occlude are routinely used for PDA closure for moderate to large sized PDAs. In this study, we retrospectively analyzed the results of 274 patients who underwent transcatheter PDA closure either with ADO device or SHSMA occluder.

Faella et al. reported 4.7% incidence of major procedural complications after transcatheter PDA closure.¹¹ In their study main procedural complications were; device embolization, hemolysis, ST depression and sudden death after placement of device. In our study, there was only one incidence of device embolization and only three patients required blood transfusion. In previous trials, the success rate of PDA closure using ADO device has been reported 97 to 99%. Amoozgar et al reported 97.8% success rate with ADO device closure.⁶ Sultan et al. implanted

PDA successfully in 98.2% patients.¹² In USA the reported success rate after ADO device closure is 99%.⁷ Zulqurnain et al reported 99.2% success rate with SHSMA occluder device.⁴ In our study, the success rate was 99.63%. There was only one case of failure due to device embolization.

In our study the most common procedural complication was protrusion of aortic end of device into aorta which occurred in 5.8% patients without obstruction of blood flow. Other complication was pulse loss which occurred in 2.2% patients. Other were mild LPA obstruction due to protrusion of pulmonary end of device into left pulmonary artery, blood transfusion and residual PDA in catheterization laboratory. And there was no procedure related mortality. Rate of procedural complications in our study were comparable with the previously reported results. Amoozgar et al reported 2.7% incidence of device embolization during the procedure.⁶ Younas et al. and Beg et al. reported no incidence of device embolization with PDA device closure.^{13,14} Bilkis et al. reported one death due to embolization of device.¹⁵

CONCLUSION

Percutaneous patent ductus arteriosus closure is safe with minimum number of complications. Pulse loss, protrusion of aortic end of device into aorta and residual PDA in cath lab (resolved within 24 hours) are common procedural complications.




Copyright© 15 Nov, 2017.

REFERENCES

- Patel HT, Cao QL, Rhodes J, Hijazi ZM. **Long-term outcome of transcatheter coil closure of small to large patent ductus arteriosus.** Catheter Cardiovasc Interv. 1999;47(4):457-61.
- Porstmann W, Wierny L, Warnke H. **Closure of persistent ductus arteriosus without thoracotomy.** Ger Med Mon. 1967;12(6):259-61.
- Lloyd TR, Fedderly R, Mendelsohn AM, Sandhu SK, Beekman RH. **Transcatheter occlusion of patent ductus arteriosus with Gianturco coils.** Circulation. 1993;88(4):1412-20.
- Zulqarnain A, Younas M, Waqar T, Beg A, Asma T, Baig MAR. **Comparison of effectiveness and cost of patent ductus arteriosus device occlusion versus surgical ligation of patent ductus arteriosus.** Pak J Med Sci. 2016;32(4):974.
- Sun W-F, Dong Z-F, Gong K, Zhang G-P, Cui T, Xia Y-D, et al. **Transcatheter closure with use of the SHSMA occluder in 180 patients with congenital heart defects: preliminary results.** Texas Heart Institute J. 2010;37(5):531.
- Amoozgar H, Salehi S, Farhadi P, Edraki MR, Borzoei M, Ajami G, et al. **Follow-Up Results of Device Occlusion of Patent Ductus Arteriosus.** Iran J Pediatr. 2016;26(3):e3621.
- Pass RH, Hijazi Z, Hsu DT, Lewis V, Hellenbrand WE. **Multicenter USA Amplatzer patent ductus arteriosus occlusion device trial: initial and one-year results.** J Am Coll Cardiol. 2004;44(3):513-9.
- Porstmann W, Wierny L, Warnke H, Gerstberger G, Romaniuk P. **Catheter closure of patent ductus arteriosus. 62 cases treated without thoracotomy.** Radiol Clin North Am. 1971;9(2):203.
- Al-Hamash SM, Wahab HA, Khalid ZH, Nasser IV. **Transcatheter closure of patent ductus arteriosus using ado device: retrospective study of 149 patients.** Heart Views. 2012;13(1):1.
- Rashkind WJ, Mullins C, Hellenbrand W, Tait M. **Nonsurgical closure of patent ductus arteriosus: clinical application of the Rashkind PDA Occluder System.** Circulation. 1987;75(3):583-92.
- Faella HJ, Hijazi ZM. **Closure of the patent ductus arteriosus with the Amplatzer PDA device: immediate results of the international clinical trial.** Catheter Cardiovasc Interv. 2000;51(1):50-4.
- Sultan M, Ullah M, Sadiq N, Akhtar K, Akbar H. **Transcatheter Device Closure of Patent Ductus Arteriosus.** J Coll Physicians Surg Pak. 2014;24(10):710-3.
- Younas M, Beg A. **Patent ductus arteriosus device occlusion in young children less than 12 kg- immediate results and complications.** Pak Heart J. 2015;47(4):193-97.
- Beg AM, Younas M, Chaudary AT. **Early Results of Transcatheter Closure of Patent Ductus Arteriosus: Retrospective Study of 61 Patients.** A King Edward Med Uni. 2013;19(1).
- Bilkis AA, Alwi M, Hasri S, Geetha K, Rehman MA, Hasanah I. **The Amplatzer duct occluder: experience in 209 patients.** J Am Coll Cardiol. 2001;37(1):258-61.

“
Deal with your problems before they deal with your happiness.
 – Unknown –”

AUTHORSHIP AND CONTRIBUTION DECLARATION

Sr. #	Author-s Full Name	Contribution to the paper	Author=s Signature
1	Touseef Asma Chaudhry	Conceived, Designed and wrote the manuscript.	
2	Muhammad Younas	Did data collection, helped in writing the manuscript.	
3	Ahsan Beg	Helped in statistical analysis and designing the research Methodology, Review the manuscript.	
4	Muhammad Ameen	Helped in Statistical analysis and interpretation of results.	