



DRUG INDUCED LIVER INJURY; ROLE OF ASCORBIC ACID IN A LABORATORY ANIMAL

1. MBBS, M. Phil.
Assistant Professor,
Department of Pharmacology,
Isra University, Hyderabad,
Sindh, Pakistan.
2. MBBS, M. Phil.
Lecturer,
Department of Anatomy,
Liaquat University of Medical and
Health Sciences Jamshoro,
Sindh, Pakistan.
3. MBBS, M. Phil.
Senior Lecturer,
Department of Anatomy,
Liaquat University of Medical and
Health Sciences Jamshoro,
Sindh, Pakistan.

Correspondence Address:

Dr. Mozna Talpur
Assistant Professor,
Department of Pharmacology,
Isra University, Hyderabad,
Sindh, Pakistan.
giggly786@gmail.com

Article received on:

09/07/2017

Accepted for publication:

20/10/2017

Received after proof reading:

03/11/2017

INTRODUCTION

Liver is the largest gland and a seat of biochemical reactions. It is located in the right hypochondrium under rib cage. The parenchyma cells of liver are known as the hepatocytes.¹ Hepatocytes are bestowed with enzymes systems to degrade the drugs, chemicals, and xenobiotics, etc. Sometime, hepatocyte themselves become the victims of these chemical and suffer a serious injurious insult. Drug induced liver damage accounts for 10- 50% of cases, although the exact figures are not available, particularly in the developing countries like Pakistan where there is no control on the drug sale. Acute sever liver injury may results in severe loss of function of liver which is defined clinically as the acute fulminant hepatitis.^{2,3} The extent of liver injury by chemicals depends upon the dose, duration and genetic factors. Drugs may injury liver even at optimal and sub optimal doses due to idiosyncratic reactions, this has been a dilemma of clinical practice. Intermediate metabolites may damage the liver which may be dose dependent or independent.^{3,4}

Mozna Talpur¹, Asadullah Yousfani Palli², Shagufta Shaheen Qureshi³

ABSTRACT... Objectives: Analyzing the efficacy of ascorbic acid (AA) against azathioprine (AZA) induced liver injury in rabbit model. **Study design:** Experimental study. **Place and Duration:** Isra University in collaboration with the animal house of Sindh Agriculture University; Tando Jam from July 2010 to November 2011. **Materials and Methods:** A sample of 80 rabbits was divided into; Group A – control rabbits, and Experimental group B - (AZA 15 mg/kg), group C- (AZA 15 mg/kg + AA 100 mg/kg) and group D- (AZA 15 mg/kg + AA 200 mg/kg). Blood samples were taken and sera were used for liver function test. Liver tissue sections 5 μ thick were stained for light microscopy examination. Data was analyzed on statistical software (SPSS 21.0, IBM Incorporation, USA) ($P \leq 0.05$). **Results:** Azathioprine induces severe liver injury (group B vs. group A) that was ameliorated by the ascorbic acid in group C and D ($p=0.0001$). Microscopy showed hepatocyte necrosis, cholestasis, sinusoidal dilatation, peri-sinusoidal fibrosis, veno-occlusive disease, peliosis hepatis and loss of tissue array in azathioprine treated rabbits. **Conclusion:** Azathioprine causes severe liver injury that was ameliorated by the ascorbic acid in present experimental study.

Key words: Azathioprine, Ascorbic Acid, Liver Injury, Liver Histology.

Article Citation: Talpur M, Palli AY, Qureshi SS. Drug induced liver injury; Role of ascorbic acid in a laboratory animal. Professional Med J 2017;24(11):1697-1701.
DOI:10.17957/TPMJ/17.4299

Drug induced liver failure accounts for 11.7% deaths approximately, this is not known for the developing countries. Drug induced liver injury may demand for the liver transplantation which is impossible in the developing countries where death is an inevitable event because the clinicians are handicapped as they have no liver transplantation facilities.⁵ A careful watch for the drug-induced liver damage is the only way to practice in the developing countries.^{5,6} Drug induced injury produces reactive oxygen species (ROS) and these are scavenged and neutralized by antioxidant like the ascorbic acid. Ascorbic acid is a water soluble vitamin which is highly appreciated of its anti oxidant activity.^{7,8} Ascorbic acid scavenges the ROS through its reducing properties. Ascorbic acid damages the superoxide ($O_2^{\cdot-}$) radicals which is the precursor of other free radicals. Ascorbic acid breaks this chain of free radical formation.^{9,10} AZA induced live injury may present as clinical emergency, hence simple drugs should be evaluated for prophylactic prevention and therapy. The present

research study analyzed the hepatoprotective effects of ascorbic acid against the azathioprine induced liver injury in a laboratory animal model.

MATERIALS AND METHODS

The present experimental study was conducted at the Isra University in collaboration with the animal house of Sindh Agriculture University; Tando Jam. The experimental protocol was planned in advance and ethical approval was taken from the institute. The study covered a period from July 2010 to November 2011. A sample of 80 rabbits was selected by criteria of inclusion and exclusion. Animal weight 1- 1.5 kg and male rabbits moving and feeding actively were included. Female rabbits were excluded to exclude the gender bias. Rabbits were kept in stainless steel cages. Environment of animal house was ensured with optimal temperature (23- 25 °C), humidity (55-60%) and 12/12 hour light-dark cycles. Fresh alfalfa was purchased daily for feeding. Clean water was available 24 hours. Tablet azathioprine 50 mg (GSK Pakistan) and Ascorbic acid (500 mg Abbot Pakistan) were purchased. 80 rabbits were randomly divided into; Group A – control rabbits, Group B- AZA was given 15 mg/kg orally, Group C- was given AZA (15 mg/kg) + Ascorbic acid (100 mg/kg) and Group D- was given AZA (15 mg/kg) + Ascorbic acid (200 mg/kg). Drug therapy was given for 4 weeks. Blood samples were taken after 24 hours of experimental period. Blood was taken from tail vein under supervision of a veterinary surgeon. Blood was collected in vacutainers and processed for centrifugation at 300 rpm for 15 minutes. Sera were preserved for biochemical analysis of liver function tests. Biochemical analysis was performed on Hitachi Roche analyzer. Animals were sacrificed after

anesthesia (Ketamine and Xylazil) by method as cited.¹¹ Liver was located, identified and sectioned by freeing the ligaments. Liver was washed in normal saline (0.9% NaCl) and preserved in 10% formaldehyde. Tissue sections were embedded in paraffin blocks. Tissue sections 5 μ thick were stained with Hematoxylin-Eosin (H & E). Slides were examined under light microscopy. Numerical data was analysed on statistical software (SPSS 21.0, IBM Incorporation, USA) by one-way ANOVA and post Hoc Bonferroni's test. Statistical significance was defined at 95% confidence interval ($P \leq 0.05$).

RESULT

Azathioprine induces severe liver injury (group B vs. group A) that was ameliorated by the ascorbic acid (group C and D). Liver function tests were seriously deranged in azathioprine group B and improvement was noted with ascorbic acid therapy (group C and D) as shown in Table-I ($p < 0.05$). Microscopy showed hepatocyte necrosis, cholestasis, sinusoidal dilatation, peri-sinusoidal fibrosis, veno-occlusive disease, peliosis hepatis and loss of tissue array in azathioprine treated rabbits (Fig 2) compared to ascorbic acid treated group C and D (Fig 3 and 4).

DISCUSSION

Of many drugs, the azathioprine (AZA) is one of most notorious hepatotoxic drug which is used in clinical practice since many decades for various clinical disorders. AZA is a widely used purine agent. It is used in renal transplantation and autoimmune disease such as the systemic lupus erythematosus (SLE), inflammatory bowel disease (IBD), psoriasis and the refractory rheumatoid arthritis.⁷

	Group A	Group B	Group C	Group D	P-value
Bilirubin (mg/dl)	0.93 \pm 0.3	8.7 \pm 0.9	4.7 \pm 0.9	4.56 \pm 0.6	0.0031
Prothrombin time (sec)	8.19 \pm 1.5	20.9 \pm 5.1	13.8 \pm 5.0	11.8 \pm 2.7	0.0001
Alanine transaminase (U/L)	33.1 \pm 0.7	165 \pm 15.5	80.5 \pm 17.0	59.5 \pm 11.2	0.0001
Aspartate transaminase (U/L)	29.2 \pm 4.5	149.5 \pm 13.3	89.5 \pm 8.5	67.5 \pm 9.5	0.0001
Alkaline phosphatase (U/L)	95.5 \pm 10.0	155.0 \pm 14.5	105.5 \pm 17.5	91.8 \pm 20.5	0.003
Lactate dehydrogenase (U/L)	93.5 \pm 15.3	193.5 \pm 20.1	143.5 \pm 21.1	131.5 \pm 13.3	0.0001
γ -Glutamyl transferase (U/L)	49.5 \pm 0.7	107.5 \pm 12.8	97.5 \pm 19.8	77.8 \pm 10.5	0.0001

Table-I. Liver function test in controls and experimental groups (n=80)

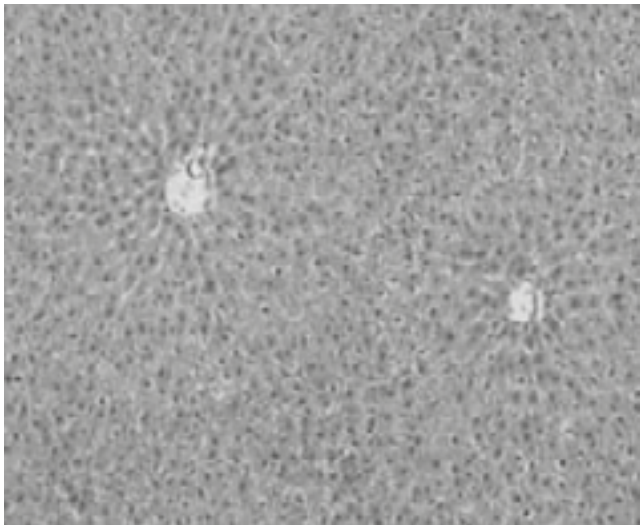


Figure-1. Control Group A- Microscopy shows two intact hepatic lobule (hepatocytes cords) showing central vein (C)

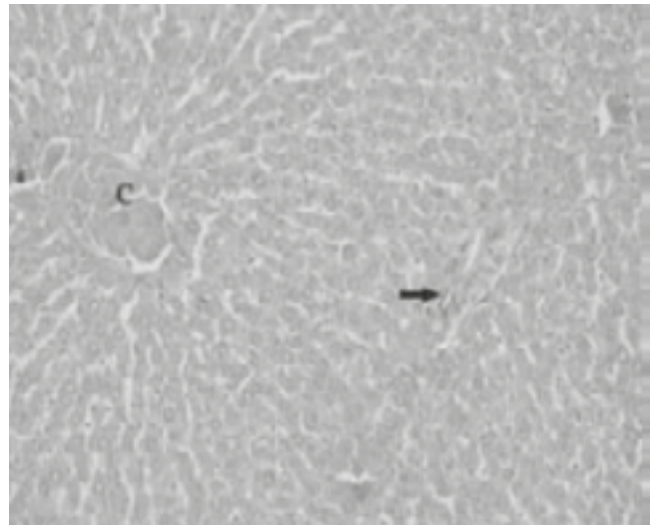


Figure-3. Group C- Microscopy shows intact hepatic histological details. Central venule (c) is normal. (Compare with Fig 1 and 2).

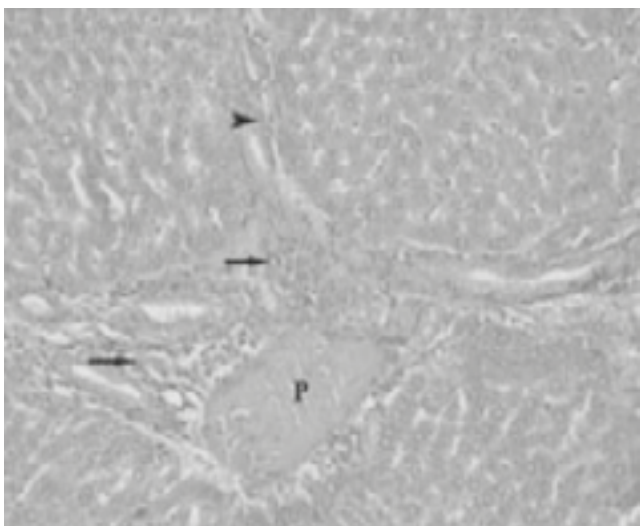


Figure-2. Azathioprine group- Severe distortion of liver lobule. Venules are dilated. Inflammatory infiltrate is shown by arrows. Portal (P) fibrosis is seen

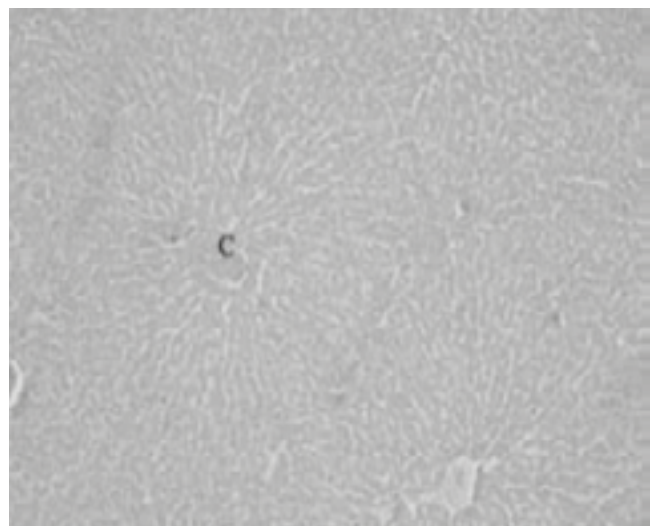


Figure-4. Liver injury is decreased (Central venule (c) is normal. (Compare with Fig 1 and 2)

It is also prescribed for the neoplasms, myasthenia gravis, multiple sclerosis. It is an antimetabolites used for various malignancies. Despite its notoriety of being hepatotoxic drug, its use outweighs for the malignancies and autoimmune disorders.^{8,12} Most important thing, is the hepatotoxicity of AZA is unpredictable, whose mechanisms are not well known but this may be due to altered metabolizing enzyme activity.¹³ A previous study¹⁴ reported an incidence of 3.5% AZA- induced hepatitis in the inflammatory bowel disease patients. In present rabbit model study,

the microscopy showed hepatocyte necrosis, cholestasis, sinusoidal dilatation, peri-sinusoidal fibrosis, veno-occlusive disease, peliosis hepatis and loss of tissue array in azathioprine treated rabbits (Fig 2) compared to ascorbic acid treated group C and D (Fig 3 and 4). The findings are supported by previous studies^{7,15,16} which had reported similar microscopic findings by the AZA therapy. Previous studies¹⁵⁻¹⁷ had reported severe cholestasis with or without hepatocellular necrosis with azathioprine drugs. The findings of above studies support the present study as

we have observed similar cholestasis in rabbits received AZA therapy. Derangement of liver function tests is an important finding which supports the histological injury in AZA group. Our findings are also in agreement with previous studies.¹⁸⁻²⁰ AZA hepatotoxicity is dose dependent most often, although idiosyncratic factors have also been noted. In present animal research, the AZA hepatotoxicity was dose dependent and idiosyncratic reactions were not analyzed (Fig 2). Portal and peri-portal fibrosis and severe inflammatory exudate was noted. These findings are in agreement with previous study.²¹ A previous study concluded that the AZA induced hepatotoxicity is mediated through impaired purine and DNA biosynthesis²⁰ and reactive oxygen species.²¹ The present study could not studied this parameter. However, the ascorbic acid offered excellent anti- hepatotoxic effect against the AZA induced toxicity. Liver function tests and liver histology were ameliorated by the ascorbic acid. This is supported by previous studies.^{20,21} The present study has a few limitations such as the free radicals, antioxidant enzymes and other underlying mechanisms were not analyzed because of study design, funding and financial issues. However, the ascorbic acid is an easily available and cost effective drug which must be considered for those patients being treated with azathioprine. The finding is of clinical importance. The clinicians and oncologist may consider the use of ascorbic acid in those where azathioprine is used.

CONCLUSION

Azathioprine causes severe liver injury that was ameliorated by the ascorbic acid in present experimental study. In conclusion, the patients taking azathioprine may also be prescribed ascorbic acid as prophylactic therapy to prevent liver injury.

Copyright© 20 Oct, 2017.

REFERENCES

1. W Young B, Lowe JS, Steven A, Heath JW. **Wheater's functional histology-A text and colour atlas.** 5th ed. Churchill Livingstone, Elsevier Philadelphia. 2006:346-58.
2. Yoon E, Babar A, Choudhary M, Kutner M, Pysopoulos N. **Acetaminophen-Induced Hepatotoxicity: a Comprehensive Update.** J Clin Translat Hepatol 2016; 4: 131-142.
3. Andrade RJ, Lucena MI, Ferná´ndez MC. **Drug-induced liver injury: an analysis of 461 incidences submitted to the Spanish registry over a 10-year period.** Gastroenterology 2005; 129:512-21.
4. Zimmerman HJ. **Drug-induced liver disease.** Clin Liver Dis 2000; 4:73-96.
5. Bjo´rnsson E, Olsson R. **Suspected drug-induced liver fatalities reported to the WHO database.** Dig Liver Dis 2006; 38:33-8.
6. Savvidou S, Goulis J, Giavazis I. **Herb-induced hepatitis by Teucrium polium L.: report of two cases and review of the literature.** Eur J Gastroenterol Hepatol 2007; 19:507-11.
7. Al Mruf A, Wan L, O'Brien PJ. **Evaluation of azathioprine induced cytotoxicity in an in vitro rat hepatocyte system.** BioMed Res Int`l 2014; 2014:1-7.
8. Moustafa AM, Badria FA. **Impact of L-arginine on azathioprine induced chronic hepatotoxicity in mice: Biochemical and ultrastructural study.** Egypt J Histol 2010; 33 (3) 407-18.
9. Sahlin K, Shabalina IG, Mattsson CM, Bakkman L, Fernstrom M, Rozhdstvenskaya Z, et al. **Ultraendurance exercise increases the production of reactive oxygen species in isolated mitochondria from human skeletal muscle.** J Appl Physiol 2010, 108:780-7.
10. Chaput JP, Klingenberg L, Rosenkilde M, Gilbert JA, Tremblay A, Sjodin A. **Physical activity plays an important role in body weight regulation.** J Obes 2011, 2011:11.
11. Ristow M, Zarse K, Oberbach A, Kloting N, Birringer M, Kiehnopf M, Stumvoll M, Kahn CR, Bluher M: **Antioxidants prevent health-promoting effects of physical exercise in humans.** Proc Natl Acad Sci USA 2009, 106:8665-70.
12. Trabelsi ABS, Hamami E, Ksaa M, Souguir A, Mabrouk MB, Brahem A, et al. **Azathioprine induced liver cirrhosis: an unusual side effect.** Open J Gastroenterol 2013; 3:295-7.
13. Ehmsen L, Marko C, Breidert M. **Portal vein hypertension with azathioprine therapy in patients with Crohn's disease - Is it a frequent phenomenon? [Portale hypertension unter azathioprin bei morbus Crohn - Ein hufiges phnomen?].** Deutsche Med. Wochenschr. 2008; 133(18):950-3.

14. De Boer NKH, Tuynman H, Bloemena E, Westerga J, Van Der Peet DL, Mulder CJJ, et al. **Histopathology of liver biopsies from a thiopurine-naïve inflammatory bowel disease cohort: Prevalence of nodular regenerative hyperplasia.** Scand. J. Gastroenterol. 2008; 43(5):604-8.

15. Schumann M, Preiss JC, Loddenkemper C, Günther U, Somasundaram R, Siegmund B, et al. **Nodular regenerative hyperplasia: A side effect of azathioprine in a patient with Crohn's disease [Noduläre regenerative Hyperplasie als Nebenwirkung von Azathioprin bei morbus Crohn].** Deutsche Med. Wochenschr. 2008; 133(38):1897-1900.

16. Zheng JJ, Chu XQ, Shi XH, Zhou CL and Seng BW. **Efficacy and safety of azathioprine maintenance therapy in a group of Crohn's disease patients in China.** J Dig Dis 2008; 9 (2):84-8.

17. Kesiova M, Alexandrova A, Yordanova N, Kirkova M and Todorov S. **Effects of diphenhydramine and famotidine on lipid peroxidation and activities of antioxidant enzymes in different rat tissues.** Pharmacol. Rep. Mar-Apr 2006; 58(2):221-8.



18. Shukla J, Chatterjee S, Thakur VS, Premachandran S, Checker R and Poduval TB. **L-arginine reverses radiation-induced immune dysfunction: The need for optimum treatment window.** Radiat.Res.2009; 171 (2):180-7.

19. Ardeshiri R, Ghassemi F, Kargar H. **Histological study of azathioprine effect on liver in insulin resistant rats.** Advances in Environmental Biology 2012; 6(10): 2784-90.

20. César M, María D, Fernández M. **Azathioprine Acts upon Rat Hepatocyte Mitochondria and Stress-Activated Protein Kinases Leading to Necrosis: Protective Role of NAcetyl-L-cysteine.** J Pharmacol Experimen Therapeutics Fast Forward 2004; 104: 269-86.

21. Farrell G.C. **Toxicity of low dose azathioprine and 6-mercaptopurine in rat hepatocytes. Roles of xanthine oxidase and mitochondrial injury.** J Hepatol 2004; 40(3): 454-63.

AUTHORSHIP AND CONTRIBUTION DECLARATION

Sr. #	Author-s Full Name	Contribution to the paper	Author=s Signature
1	Mozna Talpur	Literature review, Materials handing, Collection of Biopsy materials,. Staining Microscopy, Compilation of resultls, Statistical analysis, Manuscript write up, Proof reading, Correspondence.	
2	Asadullah Yousfani Palli	Concept, Materials handing, Performing lab investigations, Manuscript write up, Proof Reading.	
3	Shagufta Shaheen Qureshi	Concept, Materials handing Collection of Biopsy materials, Staining microscopy, compilation of resultls, Statistical analysis, Manuscript write up.	