



SALIVARY GLANDS;

CLINICAL & HISTOPATHOLOGICAL SPECTRUM OF ADENOID CYSTIC CARCINOMA & MUCOEPIDERMOID CARCINOMAS REPORTED AT TERTIARY CARE HOSPITALS IN LAHORE

1. (BDS, M.Phil. Oral Pathology) Research Student, Department of Oral Pathology, University of Health Sciences, Lahore.
2. (MBBS, M.Phil., PhD (Histopathology)) Assistant Professor, Department of Morbid Anatomy & Histopathology/Oral Pathology, University of Health Sciences, Lahore.
3. (MBBS, FCPS (Surgery)) Associate Professor, Department of Surgery, Akhtar Saeed Medical & Dental College, Lahore.
4. (MBBS, M.Phil. (Histopathology)) Assistant Professor, Department of Pathology, King Edward Medical University, Lahore.
5. (MBBS, M.Phil. (Histopathology)) Professor of Pathology, Akhtar Saeed Medical & Dental College, Lahore.
6. (M.Sc., M.Phil. Histotechnology) Senior Lab Manager, Department of Histopathology, University of Health Sciences, Lahore.
7. (MBBS, FRC Path, PhD) Head of Morbid Anatomy & Histopathology/ Oral Pathology Department, University of Health Sciences, Lahore.

Correspondence Address:

Dr. Sunila Hussain
M.Phil Oral Pathology Research Student,
University of Health sciences,
Lahore, Pakistan.
sunilaeyyaz@gmail.com

Article received on:

10/03/2017

Accepted for publication:

15/09/2017

Received after proof reading:

03/11/2017

Sunila Hussain¹, Nadia Naseem², Muhammad Rashid Siraj³, Fakeha Rehman⁴, Ihtesham-u-Din Qureshi⁵, Ghulam Rasool⁶, Abdul Hanan Nagi⁷,

ABSTRACT... Objectives: Adenoid cystic carcinoma (AdCC) and mucoepidermoid carcinoma (MEC) are the commonest salivary gland malignancies in Pakistan constituting almost 75% of all malignant salivary gland tumours. The objective of this study was to explore the clinical & morphological spectrum of these tumours in local population and to grade them w.r.t. modern grading criteria. **Study Design:** Descriptive study. **Setting:** Department of Morbid Anatomy and Histopathology/ Oral Pathology, University of Health Sciences Lahore, Pakistan. **Period:** Jan. 2014 to Sep. 2015. **Method:** Paraffin embedded blocks and detailed clinical data of 20 cases each of adenoid cystic carcinoma and mucoepidermoid carcinoma reported at local tertiary care hospitals. The histologic diagnosis was made on Hematoxylin and Eosin staining. The tumours were graded into grades I, II & III according to the most recent grading criteria. AdCC was studied with respect to its morphological patterns (tubular, cribriform and solid) while MEC was studied with special concern to the cell types seen in it (mucous, intermediate, squamous and clear cells). **Results:** The most frequently observed age group for the patients of AdCC was the 5th (45%) decade with mean age of 41.50 ± 12.224 years and a female predilection of 1.5:1. Minor salivary glands were the commonest site involved (80%) of which palate was most frequently affected (37.5%) followed by maxilla (25%). Grade I (75%) was most frequently noted grade in AdCC. Cribriform pattern (60%) was the most frequently encountered predominant histological pattern followed by equal distribution of tubular and solid patterns (20% each). MEC affected most patients in 3rd (30%) decade with mean age of 32.35 ± 13.674 years and male predilection (60%). Parotid gland (70%) was the commonest site involved followed by maxilla (10%). Histologically, grade III (40%) was most frequently noted followed by grade I (35%) and grade II (25%). Squamous cells (65%) were the predominant cell type in most cases followed by mucous cells in (35%) cases. **Conclusion:** Adenoid cystic carcinoma and mucoepidermoid carcinoma both affect a younger age group in our population with a female (1.5:1) and male (1:1.5) predilection respectively. The most favoured site for AdCC and MEC is palate and parotid gland respectively. Grade I AdCC and cribriform pattern are the commonest grade and pattern encountered in this study. On the other hand, high grade (Grade III) MEC is the most regularly encountered grade in MEC. So, proper grading and staging along with meticulous surgical approach is needed to improve the life expectancy in these patients.

Key words: Adenoid Cystic Carcinoma, Histology, Mucoepidermoid Carcinoma.

Article Citation: Hussain S, Naseem N, Siraj MR, Rehman F, Qureshi I, Rasool G, Nagi AH. Salivary glands; Clinical & histopathological spectrum of adenoid cystic carcinoma & mucoepidermoid carcinomas reported at tertiary care hospitals in Lahore. Professional Med J 2017;24(11):1661-1668.
DOI:10.17957/TPMJ/17.3923

INTRODUCTION

Adenoid cystic carcinoma and mucoepidermoid carcinoma are the commonest salivary gland neoplasms constituting the bulk of malignant salivary gland neoplasms. Regarding the prevalence of these tumours, some studies have reported AdCC to be commonest while others have named MEC to be the commonest salivary gland malignancy.^{1,2}

Adenoid cystic carcinoma is a slow growing but aggressive tumour of the salivary glands with a prolonged clinical course and late distant metastasis.³ Sixty percent AdCC arise from the minor salivary glands with palate as its most frequent site.⁴ Adenoid cystic carcinoma shows a peak incidence in middle and older age group with no gender predilection.⁵ This tumour exhibits a varied clinical course with one group showing

persistent fulminating course, early metastasis and death in 3 years and the other group has been described as “patient and the tumour existing in symbiosis” resulting in wide infiltration of structures by the tumour.⁴

Mucoepidermoid carcinoma is seen in both children and adults and has been named as commonest malignancy of salivary glands in children.⁶ It occurs in major and minor salivary glands with a frequency of 53% and 47% respectively.⁴ Parotid gland and palate are most common sites for the major and minor salivary glands respectively.⁴ Worldwide reported incidence of MEC is 0.44 per 100,000.⁴ The age range for MEC is third to fifth decade with mean age of 45 years and a female predilection with male to female ratio of 2:3.⁴ Clinically, it appears mostly as an asymptomatic swelling. However, the clinical features vary according to the grade of the tumour as most low and intermediate grade MECs are slow growing and painless masses, while high grade MECs are fast growing, painful, fixed to the underlying skin or tissue, show facial nerve paralysis, ulceration and trismus.⁷

SUBJECTS AND METHODS

This study was conducted at the Department of Morbid Anatomy and Histopathology/Oral Pathology, University of Health Sciences, Lahore. A total of 40 blocks of adenoid cystic carcinoma and mucoepidermoid carcinoma of salivary glands (20 each) reported at Histopathology Departments of University of Health Sciences, King Edward Medical College/Mayo hospital, Sheikh Zaid hospital and Fatima Jinnah Medical College /Ganga Ram Hospital, Lahore from January, 2014 to September, 2015 were included in the study. Detailed clinical data was retrieved from the respective departmental records.

The blocks were remolded into tissue cassettes. Tissue sections of 4µm were cut using rotary microtome and were stained with haematoxylin and eosin staining according to the guidelines provided by Harris in 1900. Finally, they were subjected to microscopic examination. Diagnosis of adenoid cystic carcinoma & mucoepidermoid carcinoma was confirmed and their histological

grades were determined by two Histopathologists/ Oral pathologists.

Adenoid cystic carcinoma and mucoepidermoid carcinomas were graded according to the grading system provided by Spiro⁸ and Auclair⁹ respectively (Table-I & II respectively)

Adenoid Cystic Carcinoma Grading	
Grade	Grading parameter
I	Mostly tubular or cribriform (no stipulations on minor solid components)
II	50% solid
III	Mostly solid

Table-I. Histological grading of adenoid cystic carcinoma (spiro¹⁵)

Mucoepidermoid Carcinoma Grading	
Histopathological feature	Point value
Cystic component < 20%	2
Neural invasion	2
Necrosis	3
4 or more mitosis/10 hpf	3
Anaplasia	4
Tumour grade	Point score
Low	0-4
Intermediate	5-6
High	7-14

Table-II. Histological grading of mucoepidermoid carcinoma (auclair¹⁶)

The clinical and histopathological data was analysed statistically using SPSS 20.0. Chi-square and Fischer Exact tests were applied and p-value <0.05 was considered to be statistically significant.

RESULTS

Clinical Parameters

The mean age of these 40 patients was 37.35±13.658 years with an age range of 09-70 years. Equal number of male and female patients were reported (n=20, 50% each). Minor salivary glands (n=20, 50%) were the commonest site involved by these two tumours closely followed by parotid gland (n=17, 42.5%). Gland involved and type of tumour were significantly associated ($p < 0.0001$) (Figure-1).

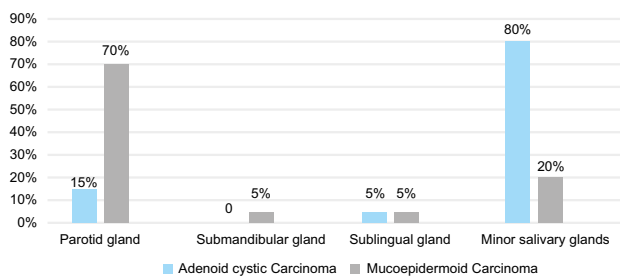


Figure-1. Gland Distribution in Adenoid Cystic Carcinoma & Mucoepidermoid Carcinoma of Salivary Glands ($p < 0.0001$).

The mean age of patients with adenoid cystic carcinoma was 41.50 ± 12.224 years with an age range of 22-70 years and most patients ($n=9$, 45%) reporting in 5th decade of life. Female predisposition was noted with female to male ratio of 1.5:1. Minor salivary glands ($n=16$, 80%) were the commonest site with palate and maxilla being equally affected ($n=5$, 25% each). Most of the cases occurred on right side ($n=8$, 40%). Lymph node involvement was seen in none of the

cases of AdCC.

The mean age of patients with MEC was 32.35 ± 13.674 years with a wider age range of 09-60 years. Most cases were seen in 3rd decade ($n=6$, 30%) of life with slight male predominance (1:1.5). Parotid gland ($n=14$, 70%) was most frequently involved followed by minor salivary glands ($n=4$, 20%). Most of the cases occurred on right side ($n=9$, 45%). Lymph node involvement was seen in 9 (45%) cases of MEC.

Tables-III & IV summarize the clinical parameters of AdCC and MEC.

Histopathology of Adenoid Cystic Carcinoma

The tumour cells in adenoid cystic carcinoma were basaloid with small hyperchromatic nuclei and scant eosinophilic cytoplasm. These cells were arranged in tubular, cribriform and solid patterns, varying in proportions in one neoplasm (Table-V).

Mean age ± S.D. (years)	Adenoid cystic carcinoma		Mucoepidermoid carcinoma		Total		p-value
	41.50±12.224		32.35±13.674		37.35±13.658		
Minimum age (years)	22		09		09		
Maximum age (years)	70		60		70		
Decade	F	%	F	%	F	%	0.442
1 st decade (0-9 years)	0	0	01	05	01	2.5	
2 nd decade (10-19 years)	0	0	02	10	02	05	
3 rd decade (20-29 years)	04	20	06	30	09	22.5	
4 th decade (30-39 years)	02	10	03	15	05	12.5	
5 th decade (40-49 years)	9	45	05	25	15	37.5	
6 th decade (50-59 years)	03	15	02	10	05	12.5	
7 th decade (60-69 years)	01	05	01	05	02	05	
8 th decade (70-79 years)	01	05	0	0	01	2.5	
Gender							0.525
Female	12	60	08	40	20	50	
Male	8	40	12	60	20	50	
F:M	1.5:1		1:1.5		1:1		

Table-III. Age & gender distribution in adenoid cystic carcinoma and mucoepidermoid carcinoma of salivary glands.

Clinical parameters	Adenoid cystic carcinoma		Mucoepidermoid carcinoma		Total		p-value
	F	%	F	%	F	%	
Site							
Palate	06	30	01	05	07	17.5	
Maxilla	04	20	02	10	06	15	
Buccal mucosa	02	10	01	05	03	7.5	
Buccal vestibule	01	05	0	0	01	2.5	
Maxillary sinus	01	05	0	0	01	2.5	
Retromolar area	01	05	0	0	01	2.5	
Tongue	01	05	0	0	01	2.5	

Table-IV. Minor salivary gland involvement by adenoid cystic carcinoma & mucoepidermoid carcinoma of salivary glands.

Grade	I		II		III		Total		p-value
	F	%	F	%	F	%	F	%	
Histological Parameters									
Predominantly tubular/cribriform pattern & scant solid	16	80	0	0	0	0	16	80	<0.001
50% solid and 50% tubular/cribriform pattern	0	0	01	05	0	0	01	05	
>50% solid pattern	0	0	0	0	03	15	03	15	
Predominant pattern									
Tubular pattern	04	20	01	05	0	0	04	20	<0.001
Cribriform pattern	12	60	0	0	0	0	12	60	
Solid pattern	0	0	01	05	04	20	04	20	
Invasion									
Perineural invasion present	06	30	0	0	01	05	07	35	0.746
Vascular invasion present	11	55	01	05	02	10	14	70	0.796

Table-V. Histological grade and cell types in adenoid cystic carcinoma

In the tubular pattern, the tumor cells were basaloid forming multiple small ducts or tubules within a hyalinized stroma. Usually, the tubular lumina were lined by layer of ductal cells and myoepithelial cells (Figure-2A).

The cribriform pattern was characterized by islands, sheets or nests of basaloid cells with small cyst-like structures imparting "sieve-like" or "swiss cheese" appearance to the tumour (Figure). These pseudo-cystic spaces were filled with basophilic material in some cases, eosinophilic material in others and with both eosinophilic and basophilic in still other cases. In some cases, hyalinized stroma was seen to be surrounding the cells. Mitotic activity was very low to absent in this pattern (Figure-2B).

The solid variant was composed of large islands of tumor cells and as sheets in other cases with little tendency toward duct formation (Figure-2C). Cellular pleomorphism and mitotic activity was seen in this variant. The connective tissue stroma surrounding the tumour islands was usually fibrous containing blood vessels and inflammatory cells.

The most common pattern of adenoid cystic carcinoma found in current study was cribriform pattern followed by tubular and solid occurring in same frequencies. Sixteen cases (80%) were of grade I followed by 03 (15%) cases of grade III and 01(5%) case of grade II. Perineural invasion was seen in 35% of cases (Figure-2D) and vascular invasion in 70% of cases.

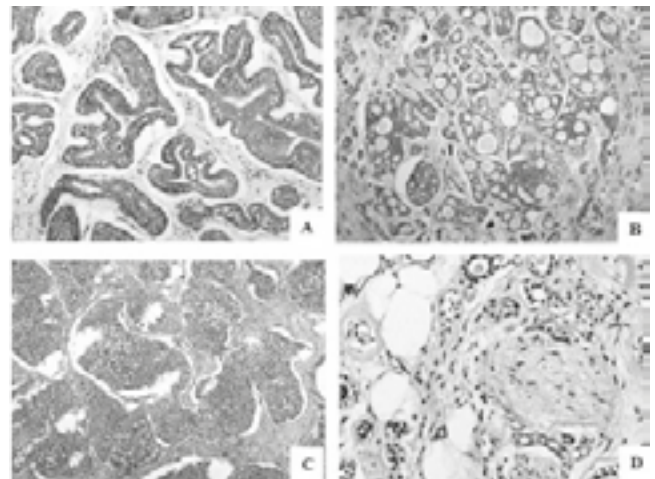


Figure-2. Photomicrographs A-D showing tubular pattern of adenoid cystic carcinoma. A (H&E; 100X), (B) showing cribriform pattern (H&E; 40x), (C) solid (H&E; 40x) and (D) perineural invasion in adenoid cystic carcinoma (H&E; 200x).

A significant correlation was noted between gland involved and histological pattern of adenoid cystic carcinoma ($p=0.023$).

Histopathology of Mucoepidermoid Carcinoma

Mucoepidermoid carcinoma is malignant salivary gland tumour and its diagnosis rests on identification of three cell types' i.e. mucous cells, intermediate cells and squamous cells within a variety of morphological patterns. The tumour was well circumscribed in 2(10) cases while it was infiltrative in 18(90) cases.

The grading parameters used to grade MEC are summarized in Table-II. Figure-3 shows cystic component, perineural invasion, anaplasia,

atypical mitosis and necrosis.

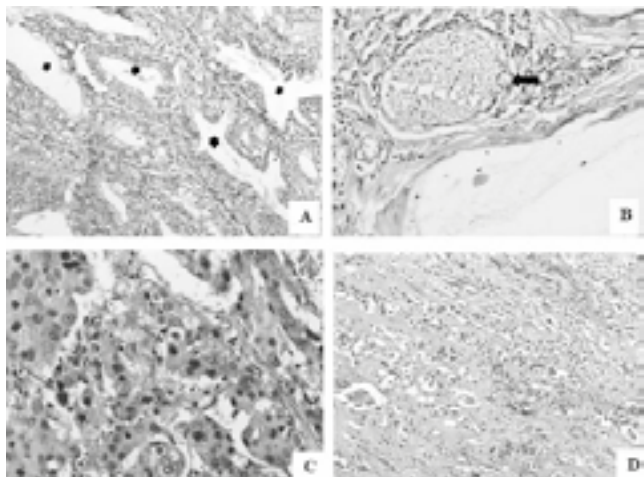


Figure-3. Photomicrographs A-D showing (A) cystic component (isterics) (H&E; 100x), (B) Perineural invasion (H&E; 200x), (C) anaplasia and atypical mitosis (arrows) (H&E; 400x) and (D) necrosis (H&E; 200x).

Low grade in MEC tumours were characterized by large/small cystic spaces lined by mucous cells and filled with mucinous material (Figure-4A). In intermediate grade (Figure-4B) and high grade mucoepidermoid carcinoma (Figure-4C) solid nests and sheets of mucous, squamous and intermediate cells replaced the cystic component.

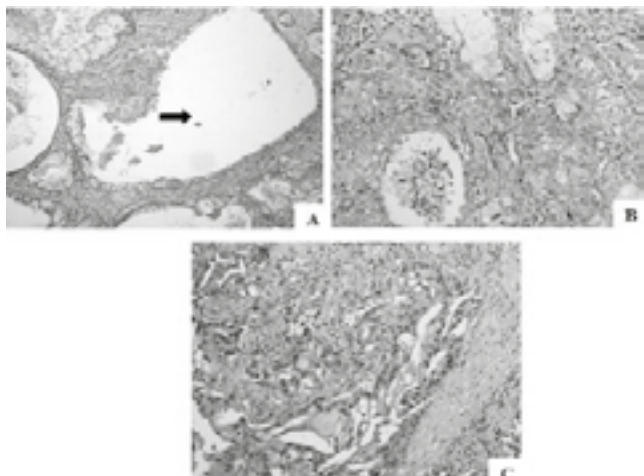


Figure-4. Photomicrographs A-C showing (A) grade I MEC (H& E; 40x), (B) grade II MEC (H&E; 100x) & (C) grade III (H&E; 100x).

High grade MEC (8; 40%) was the predominant grade in the current study closely followed by grade I (7; 35%) and II (5; 25%). Intra-cystic component (<20%), 4 or more mitosis/10 high

power field and anaplasia were significantly associated with grade of MEC having p-value= 0.005, 0.007 and <0.001 respectively.

As discussed previously, mucous cell predominate grade I and as the grade becomes higher they tend to decrease in number and intermediate and squamous cells predominate in grade II and III tumours respectively. All the three cell types were identified in the all the cases. However, in the current study, squamous cells were the predominant cell type in 13 (65%) cases and mucous cells in 07 (35%) cases (Table-VI and Figure-5A).

Of 13(65%) cases in which squamous cells were the dominant cell type, 3(23%) cases each were of grade I and II and 7(64%) cases were of grade III. Squamous cells were seen as polygonal cell with central vesicular nucleus. They were found in the lining of cystic spaces or as small nests or as solid sheets in the tumour. Whether dominant cell type or not, they showed features of anaplasia in 14(70%) cases. The mucous cells, predominant in 7(35%) cases, were large cells with foamy cytoplasm and small flattened nucleus lining the cystic spaces. In few cases mucous cells formed small nests in the tumour. Intermediate cells were present in all cases but they were never more than squamous or mucous cells. They were seen as small basaloid cells with hyperchromatic nucleus usually scattered between squamous and mucous cells. Clear cells (Figure-5B) were also seen in few cases but were obviously not the dominant type. Lymphocytic infiltration was seen in the background stroma in almost all the cases.

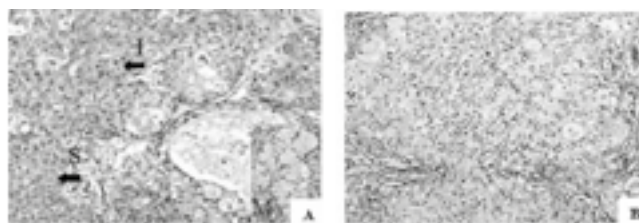


Figure-5. Photomicrographs A & B showing (A) mucous (M), Squamous (S) & intermediate (I) cells in MEC (H&E; 100x) and (B) showing clear cells (H&E; 100x).

Grade	I		II		III		Total	p-value
Predominant cell type								
Mucous	04	20	02	10	01	05	07	35
Intermediate	0	0	0	0	0	0	0	0
Squamous	03	15	03	15	07	35	13	65

Table-VI. Cell types in mucoepidermoid carcinoma

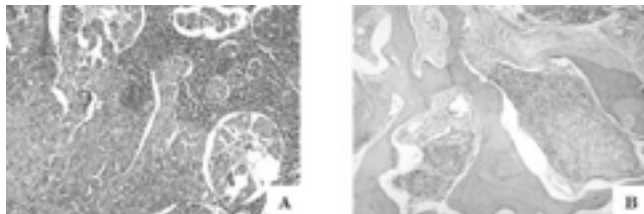


Figure-6. Photomicrographs A & B showing (A) nodal (H&E; 100x) and (B) bony metastasis in MEC (H&E; 100x).

Regarding metastasis, 9(45%) cases of MEC showed nodal metastasis. Also, cartilage invasion and metastasis of bone by tumour cells was noted in 1(5%) each. Cartilaginous invasion was seen in grade I MEC of maxilla while bone metastasis was seen in grade III MEC of palate.

DISCUSSION

Literature has reported a higher age prevalence and variable gender predisposition for AdCC & MEC than the current study. A study conducted in Turkey has reported mean age for AdCC and MEC to be 50.9 years and 51.6 years respectively which is quite higher than the current study.¹ Other studies conducted in Canada¹⁰ and USA¹¹ study have reported 58±15 years and 48.2 years as mean age for ACC patients which is again quite high than the current study. Zaman¹² in Pakistan and de Oliveira¹³ in Brazil have reported 36.33 years and 38.5 years respectively as the mean age of MEC which is closer to the current study.

Regarding gender distribution in AdCC, some studies have reported male predisposition in contrast to the current study¹ while others have reported AdCC to be more prevalent in female population.¹⁰ On the other hand, Zaman¹² have reported equal gender distribution for AdCC. Studies conducted in China¹⁴ & USA¹⁵ have reported female predominance in MEC in contrast to the current study. On the other hand, other studies reporting a male predominance similar

to the current study¹¹ are also found in literature. Zaman¹², however reported a very high male predilection of 1:4 for patients of MEC.

Similar to the current study, minor salivary glands are reported to be the commonest site for AdCC by other studies with palate as most common site.^{1,12} In contrast, other studies have reported major salivary glands to be more common site for AdCC than minor salivary glands.^{10,13} For MEC, the current study is in harmony with other studies in that major salivary glands, most commonly parotid gland, are more commonly affected than minor salivary glands.^{6,12} Liu¹⁴ reported reversal of major to minor salivary gland ratio of MECs with 234(62.2%) cases in minor and 142(37.8%) in major glands which is in contrast to the current study.

These differences in age and gender of patients may be attributed to differences in sample size of studies or to different regions where these studies are conducted.¹⁶

Adenoid cystic carcinoma is an aggressive malignant salivary gland tumour with a propensity towards perineural invasion. Chumman¹⁷ analyzed 45 cases in their study, of which 23(51.1%) were grade I, 7(15.6%) were grade II and 15(33.3%) were grade III which is accordance with the current study. Cribriform pattern was the most frequently encountered pattern in the present which is again consistent with the studies conducted worldwide.²⁰ Perineural invasion ($p=0.746$) was seen in 7(35%) cases of AdCC in the current study which is in concurrence with the results of other studies¹⁰ while lower than reported by Bianchi¹⁸ 39(58.2%) cases.

The mucoepidermoid carcinoma of salivary glands has an aggressive clinical behavior and a prognostic outcome strongly dependent upon the histological grade of the tumour. This in turn

dictates the treatment protocol for the patients of MEC.^{6,11,14} The study conducted by Nance¹⁹ with high grade MEC seen in 23(46%) cases followed by 14(28%) cases of low grade and 13(26%) cases of intermediate grade, is in harmony with the results of the current study. In contrast, Mc Hugh¹¹ reported intermediate grade MEC as the most frequently encountered grade followed by high grade and low grade MEC while . Liu¹⁴ reported intermediate grade, followed by low grade and the high grade. Still other studies have reported low grade MEC to be more common than other grades.⁶

Lymph node metastasis were found to be significantly associated with the grade of tumour ($p=0.01$) being negative in all grade I tumours and positive in 4(44.5%) and 5(55.5%) cases of intermediate and high grade MEC respectively. These results are in accordance to the study conducted by Chen²⁰ for the fact that highest number of nodal metastasis were seen in high grade tumours (56.8%).

CONCLUSION

Adenoid cystic carcinoma and mucoepidermoid carcinoma both affect a younger age group in our population with a female (1.5:1) and male (1:1.5) predilection respectively. The most favoured site for AdCC and MEC is palate and parotid gland respectively. Grade I AdCC and cribriform pattern are the commonest grade and pattern encountered in this study. On the other hand, high grade (Grade III) MEC is the most regularly encountered grade in MEC. So, proper grading and staging along with meticulous surgical approach is needed to improve the life expectancy in these patients.

Acknowledgements

The authors acknowledge the encouragement extended by the Vice Chancellor of University of Health Sciences, Lahore Pakistan. Also, to Mr. Sameer Anjum, the laboratory staff of Oral Pathology Department of University of Health Sciences, Lahore, Pakistan for their technical and logistic support. We also acknowledge the support of the Heads of Histopathology Departments of King Edward Medical University,

Fatima Jinnah Medical College, Postgraduate Medical Institute and Sheikh Zaid Hospital, Lahore for their assistance in providing access to material required for this research project.







Copyright© 15 Sep, 2017.

REFERENCES

1. Kızıl Y, Aydil U, Ekinci O, Dilci A, Köybaşıoğlu A, Düzlü M, et al. **Salivary Gland Tumors in Turkey: Demographic Features and Histopathological Distribution of 510 Patients.** Indian J Otolaryngol Head Neck Surg., 2013; 65(Suppl 1):112–20.
2. Ettl T, Schwarz-Furlan S, Gosau M, Reichert TE. **Salivary gland carcinomas.** Oral Maxillofac Surg. 2012; 16:267–283.
3. Gondivkar SM, Gadbail AR, Chole R, Parikh RV. **Adenoid cystic carcinoma: A rare clinical entity and literature review.** Oral oncol. 2011; 47: 231-236.
4. Singla N, Rathod G, Singla D. **Adenoid cystic carcinoma of the parotid gland - A case report and review of literature.** IAIM. 2015; 2(4): 182-186.
5. Eveson JW, Reichart P, Sidransky D, editors. **World Health Organization Classification of Tumours. Pathology and Genetics of Head and Neck Tumours. In: Tumours of the Salivary Glands.** Lyon: IARC Press; 2005.
6. Ozawa H, Tomita K, Sakamoto K, Tagawa T, Fujii R, Kanzaki S, et al. **Mucoepidermoid Carcinoma of the Head and Neck: Clinical Analysis of 43 Patients.** Jpn J Clin Oncol. 2008; 38(6): 414-418.
7. Ranganath MK, Matmari V, Narayanaswamy UD, Balve RM. **Mucoepidermoid carcinoma presenting as a retromolar mucocele.** Ann Maxillofac Surg. 2011; 1(1): 66–69.
8. Spiro RH, Huvos AG, Strong EW. **Adenoid cystic carcinoma of salivary origin.** A clinicopathologic study of 242 cases. Am J Surg. 1974; 128(4):512-20.
9. Auclair PL, Goode RK, Ellis GL. **Mucoepidermoid carcinoma of intraoral salivary glands. Evaluation and application of grading criteria in 143 cases.** Cancer. 1992; 69(8):2021–2030.
10. Ko JJ, Siever JE, Hao D, Simpson R, Lau HY 2016. **Adenoid cystic carcinoma of head and neck: clinical predictors of outcome from a Canadian centre.** Curr Oncol. 2016; 23(1):26-33.
11. McHugh CH, Roberts DB, El-Nagga AK, Hanna EY, Garden AS, Kies MS, et al. **Prognostic factors in mucoepidermoid carcinoma of the salivary glands.**

- Cancer. 2011; 118(16):3928-36.
12. Zaman S, Majid S, Chughtai O, Hussain M, Nasir M. **Salivary gland tumours: A review of 91 cases.** J Ayub Med Coll Abbottabad., 2014; 26(3):361-3.
 13. de Oliveira FA, Duarte ECB, Taveira CT, Máximo AA, de Aquino EC, Alencar RC, et al. **Salivary Gland Tumor: A Review of 599 Cases in a Brazilian Population.** Head and Neck Pathol. 2009, 3:271-75.
 14. Liu S, Ow A, Ruan M, Yang W, Zhang C, Wang L, Zhang, C. **Prognostic factors in primary salivary gland mucoepidermoid carcinoma: an analysis of 376 cases in an Eastern Chinese population.** Int. J. Oral Maxillofac. Surg., 2014, 43(6): 667-73.
 15. Bai S, Clubwala R, Adler E, Sarta C, Schiff B, Smith RV et al. **Salivary Mucoepidermoid Carcinoma: A Multi-Institutional Review of 76 Patient.** Head Neck Pathol. 2013, 7(2): 105-112.
 16. Shishegar M, Ashraf MJ, Azarpira N, Khademi B, Hashemi B, Ashrafi, A. **Salivary Gland Tumours in Maxillofacial Region: A Retrospective Study of 130 cases in a Southern Iranian Population.** Pathology Res Int.2011, 2011:1-5.
 17. Chummun S, McLean NR, Kelly CG, Dawes PJK, Meikle D, Fellows S, et al. **Adenoid cystic carcinoma of the head and neck.** Br J Plast Surg., 2001, 54(6):476-480.
 18. Bianchi B, Copelli C, Cocchi R, Ferrari S, Pederneschi N, Sesenna E. **Adenoid cystic carcinoma of intraoral minor salivary glands.** Oral Oncol. 2008, 44(11): 1026-1031.
 19. Nance MA, Seethala RR, Wang Y, Chiosea SI, Myers EN, Johnson JT, et al. **Treatment and survival outcomes based on histologic grading in patients with head and neck mucoepidermoid carcinoma.** Cancer, 2008 113(8): 2082-89.
 20. Chen C, Duckworth CA, Zhao Q, Pritchard DM, Rhodes JM, Yu LG. **Increased circulation of galectin-3 in cancer induces secretion of metastasis-promoting cytokines from blood vascular endothelium.** Clin Cancer Res., 2013, 19(7): 1693-1704.

AUTHORSHIP AND CONTRIBUTION DECLARATION

Sr. #	Author-s Full Name	Contribution to the paper	Author=s Signature
1	Sunila Hussain	Conception, Synthesis, Planning of the research, Active participation in active methodology, Interpretation, Analysis and discussion.	
2	Nadia Naseem	Conception, Synthesis, Planning of the research, Interpretation, Analysis and discussion.	
3	Muhammad Rashid Siraj	Active participation in active methodology, Interpretation, Analysis and discussion.	
4	Fakeha Rehman	Active participation in active methodology, Interpretation, Analysis and discussion.	
5	Ihtesham-u-Din Qureshi	Active participation in active methodology	
6	Ghulam Rasool	Active participation in active methodology	
7	Abdul Hanan Nagi	Conception, Synthesis, Planning of the research, Interpretation, Analysis and discussion.	