



## VISUAL FIELD DEFECTS;

### THE COMPARISON BEFORE AND AFTER EXCISION OF SELLA SUPRA SELLAR TUMORS BY PERFORMING THE PRE AND POST-OP COMPUTERIZED PERIMETRY

Muhammad Khalid<sup>1</sup>, Mehwish Aslam<sup>2</sup>, Umer Farooq Raina<sup>3</sup>, Khaleeq UZ Zaman<sup>4</sup>

1. MBBS, MS Neurosurgery  
Department of Neurosurgery,  
PIMS, SZABMU, Islamabad,  
Pakistan.
2. MBBS, MS Neurosurgery  
Department of Neurosurgery,  
PIMS, SZABMU, Islamabad,  
Pakistan.
3. MBBS, Resident Neurosurgeon  
Department of Neurosurgery,  
PIMS, SZABMU, Islamabad,  
Pakistan.
4. MBBS, FRCS  
Department of Neurosurgery,  
PIMS, SZABMU, Islamabad,  
Pakistan.

#### Correspondence Address:

Dr. Muhammad Khalid  
Department of Neurosurgery,  
PIMS, SZABMU, Islamabad,  
Pakistan.  
drkhalid86@yahoo.com

#### Article received on:

30/05/2017

#### Accepted for publication:

25/09/2017

#### Received after proof reading:

06/10/2017

**ABSTRACT... Objectives:** To obtain and compare the exact visual status before and after excision of sella supra sellar tumors using the computerized perimetry as a standard measuring tools and then compare with the international studies. **Background:** Sella suprasellar tumors are though not so common but affect visual acuity of patients and their quality of life drops. These tumors include pituitary adenoma commonest in the adult population, meningioma, Craniopharyngioma, astrocytic glioma, Optic nerve Glioma, Germinoma, Dermoid, Pituitary metastases. We planned a descriptive case series study to compare the pre and post excision visual field defects using computerized perimetry. **Study Design:** Case series study. **Setting:** Department of Neurosurgery, Pakistan Institute of Medical Sciences, SZABMU, and Islamabad. **Period:** 2 years from January 2015 to December 2016. **Methods:** A total of 73 patients with sella suprasellar tumors were identified and enrolled. Patients between the age of 10 and 55 years were selected on the basis of having sella supra sellar tumor on CT/MRI brain with contrast. Patients whose age was less than 10 years and more than 55 years were excluded. Moreover, patients with post radiation necrosis diagnosed on MRI and MR spectroscopy brain, those operated for other eye pathology and patients with sella supra sellar SOL having comorbidities like diabetes mellitus, hypertension etc. were also excluded from the study. The study outcome was measured in terms of comparison of visual field defects after excision of sella suprasellar tumors using computerized perimetry. **Results:** The average age of patients was 42.1 + 6.8 years ranging from 10 to 55 years. Female gender was predominant; there were 40 (54.8%) female patients. The mean computerized perimetry was 0.65 + 0.34 LogMAR before surgery which improved to 0.19 + 0.12 LogMAR after surgery. Overall, of the 73 cases, 63 (86.4%) had improvement whereas 10 (13.6%) study cases had no improvement in the visual field on follow-up. **Conclusion:** It can be concluded that after craniotomy and excision of sella suprasellar tumors, perimetry showed improvement in the majority of the study cases.

**Key words:** Sella suprasellar tumors, excision, computerized perimetry, visual field.

**Article Citation:** Khalid M, Aslam M, Raina UF, Khaleeq uz Zaman. Visual field defects; The comparison before and after excision of sella supra sellar tumors by performing the pre and post-op computerized perimetry. Professional Med J 2017;24(10):1527-1533. DOI:10.17957/TPMJ/17.4285

## INTRODUCTION

The sella turcica is a saddle-shaped depression in the body of the sphenoid bone of the skull. The seat of the saddle is known as the hypophyseal fossa which holds the pituitary gland.<sup>1</sup> The pituitary gland or hypophysis is an endocrine gland about the size of pea and weighing 0.5 grams (0.018 oz) in humans. It is a protrusion of the bottom of the hypothalamus at the base of brain.<sup>2</sup>

The anterior pituitary or adenohypophysis is a lobe of the gland that regulates several physiological processes including stress, growth, reproduction

and lactation. The intermediate lobe synthesizes and secretes melanocyte. The posterior pituitary or neurohypophysis is a lobe of the gland that is functionally connected to the hypothalamus by the median eminence via a small tube called the pituitary stalk also called the infundibular stalk or the infundibulum.<sup>3,4</sup>

Sella suprasellar tumors include pituitary adenoma commonest in the adult population, meningioma, Craniopharyngioma, astrocytic glioma, Optic nerve Glioma, Germinoma, Dermoid, Pituitary metastases.<sup>5</sup>

Fifty to sixty percent present with visual symptoms due to compression of optic nerve structures. Non-specific headache can be seen; lateral extension can result in compression of the cavernous sinuses and may cause ophthalmoplegia, diplopia, and or ptosis.<sup>6,7</sup>

Talkad et al recently reported an isolated, painful, postganglionic, Horner syndrome as the initial sign of lateral extension of a large prolactinoma. Extension into the sphenoid sinuses can cause spontaneous cerebrospinal fluid rhinorrhea, optic atrophy is seen frequently.<sup>6</sup> Papilledema is exceptional, seen only in patients with pituitary apoplexy.<sup>8</sup>

There are different factors which affect visual outcome after surgery for sella supra sellar tumors. They are: preoperative visual status, duration of symptoms at presentation, nature of tumors (histopathology).<sup>9,10</sup>

In the treatment of sella supra sellar tumors, the patients' outcome is dependent on the patient presenting neurological status, duration of symptoms.<sup>11</sup> The presenting visual state is measured by doing perimetry before and after surgery and then compared.<sup>12,13,14</sup>

We aimed to determine the exact visual status in terms of visual field of patients before and after surgery in sella suprasellar tumors by using computerized perimetry.

The results of the visual outcome of this study were also compared with international studies, thus, generating local statistics for our department at local setting and at national level.

As these patients suffer from decreased visual status or at times blindness, it was assumed that this evidence would be very important and would also give a detailed insight to the neurosurgeons regarding the prevalence of sella suprasellar tumors in the local settings and would also help investigators regarding the usage of computerized perimetry for assessing the visual outcome of these patients after partial or complete excision.

## MATERIAL AND METHODS

A case series study was conducted in the Department of Neurosurgery, Pakistan Institute of Medical Sciences, SZABMU, Islamabad. A total of 73 patients with sella suprasellar tumors were identified and enrolled in the period of 2 years from January 2015 to December 2016. Patients between the age of 10 and 55 years were selected on the basis of having sella supra sellar tumor on CT/MRI brain with contrast. Patients whose age was less than 10 years and more than 55 years were excluded. Moreover, patients with post radiation necrosis diagnosed on MRI and MR spectroscopy brain, those operated for other eye pathology and patients with sella supra sellar SOL having co-morbidities like diabetes mellitus, hypertension etc. were also excluded from the study. The study outcome was measured in terms of comparison of visual field defects after excision of sella suprasellar tumors using computerized perimetry.

Data was collected through proforma. Patients fulfilling the inclusion criteria were included in the study. An informed consent was taken from all the patients. Permission was sought from the hospital ethics committee for conducting the study. The patients were assessed by adequate history, through examination and investigation all patients were admitted for indoor management.

The perimetry was applied to all the patients, the pre-operative neurological status was compared with the post-operative perimeter report. The patients were operated through frontoparietal craniotomy.

### Craniotomy

It was opening of the skull through burr holes and then joining them with the help of instruction.

In post-operative patients the perimetry was done after four weeks intervals and any improvement was recorded. At the time of discharge from hospital the patient home address and telephone no was recorded and neurological outcome was measured. All the data was recorded on the proforma and subjected to statistical analysis to measure the objectives.

The data was analyzed through SPSS version 16 and various descriptive statistics were used to calculate frequencies, percentages, means and standard deviation. The numerical data such as age and duration of hospitalization was expressed as mean + standard deviation while the categorical data such were measured as frequency and percentages.

Paired sample t-Test was applied to compare computerized perimetry before surgery and at 4 weeks and 8 weeks after surgery. A p-value less than 0.05 was considered significant.

## RESULTS

In the current study 73 cases of sellar suprasellar tumors were enrolled. The average age of patients was 42.1 + 6.8 years ranging from 10 to 55 years. There were 8 (10.9%) patients in the second decade of life, 6 (8.2%) in the 3<sup>rd</sup> decade of life. However, majority 26 (35.6%) were in the fourth decade of life, another 21 (28.7%) patients were found in the fifth decade of life and 12 (16.4%) patients were between 51 and 55 years of age. (Table-I)

Female gender was predominant in this study. There were 40 (54.8%) female patients and 33 (45.2%) males. (Table-II)

	No of patients	%age
<b>Age (years)</b>		
10 to 20	8	10.9%
21 to 30	6	8.2%
31 to 40	26	35.6%
41 to 50	21	28.7%
51 to 55	12	16.4%
Mean + SD	42.1 + 6.8	
Range (Min – Max)	10 - 55	

**Table-I. Age of study patients (n=73)**

	No of patients	%age
Male	33	45.2%
Female	40	54.8%

**Table-II. Gender of study patients (n=73)**

The computerized perimeter showed a significant improvement of visual field after surgery. The status of visual field was compared among those who improved and those did not. Of the patients

with bitemporal hemianopia, 34 (53.9%) had full or partial improvement whereas 4 (40.0%) had no improvement and this difference among improved and non-improved patients was statistically significant (p-value = 0.03). Of the cases with upper quadrant TFD, 13 (20.6%) had improvement in visual field and 2 (20.0%) had no improvement. Similarly, of the two quadrant TFD patients, 7 (11.1%) had improvement after surgery whereas 1 (10.0%) had no improvement. Of the patients with three quadrant TFD, 8 (12.6%) had improvement and 1 (10.0%) had no improvement after surgery. Moreover, in blind patients only 1 (1.5%) had improvement and 2 (20.0%) were found unchanged with no improvement (p-value = 0.006). (Table-III)

Visual field	Improvement (Partial/full) (n=63)	No improvement (n=10)	p-value
Bitemporal hemianopia	34 (53.9%)	4 (40.0%)	0.03
Upper quadrant TFD	13 (20.6%)	2 (20.0%)	1.0
Two quadrant TFD	7 (11.1%)	1 (10.0%)	1.0
Three quadrant TFD	8 (12.6%)	1 (10.0%)	0.86
Blind	1 (1.5%)	2 (20.0%)	0.006

**Table-III. Findings of computerized perimetry for field after surgery (n=73)**

The improvement in the visual acuity after surgery was measured by computerized perimeter which showed that 42 (57.5%) patients had immediate improvement and 31 (42.5%) had no improvement initially. However, on the 4 weeks follow-up 21 (28.7%) more study patients had improvement in the visual status and 10 (13.6%) had no improvement. On the 8<sup>th</sup> week follow-up none of the patients had any improvement. Overall, we found out that of the 73 cases, 63 (86.4%) improved whereas 10 (13.6%) study cases had no improvement in the visual acuity. (Table-IV)

	Improvement	No improvement
Immediate	42 (57.5%)	31 (42.5%)
4 weeks	21 (28.7%)	10 (13.6%)
8 weeks	0 (0.0%)	10 (13.6%)
Overall all	63 (86.4%)	10 (13.6%)

**Table-IV. Status of computerized perimetry for field on follow-ups after surgery (n=73)**

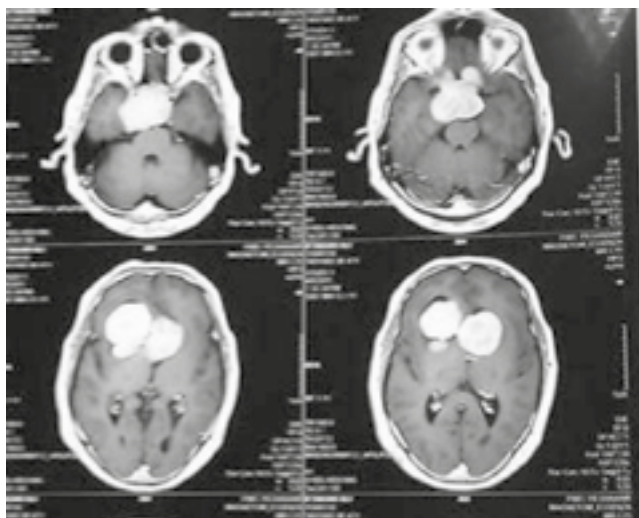


Figure-1. MRI Brain with contrast showed Pit Adenoma

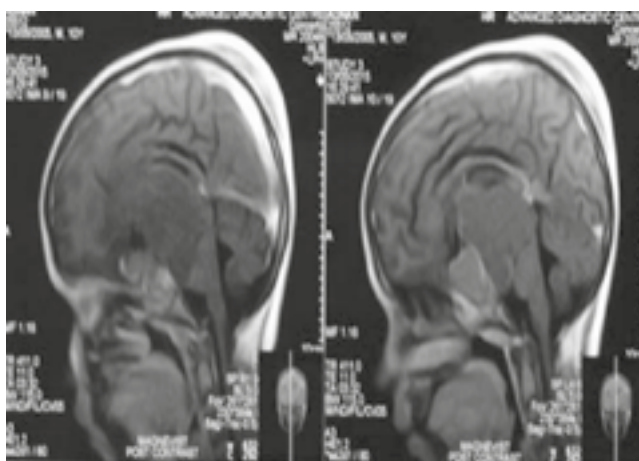


Figure-2. MRI brain with contrast views demonstrates the cystic nature of a tumor

## DISCUSSION

In this study 73 patients having sellar and suprasellar tumors were excised by craniotomy in the neurosurgical department of Pakistan Institute of Medical Sciences, SZABMU, Islamabad in a period of ten months. Patients between the age of 10 and 55 years were selected on the basis of having sella supra sellar tumor on CT/MRI brain with contrast. Patients whose age was less than 10 years and more than 55 years were excluded. Moreover, patients with post radiation necrosis diagnosed on MRI AND MR spectroscopy brain, those operated for other eye pathology and patients with sella supra sellar SOL having comorbidities like diabetes mellitus, hypertension etc. were also excluded from the study.

The mean age of patients was 42.1 years in this study and most of them (54.8%) were females. A study by Githinji KJ et al on clinical experience and outcome of pituitary surgery reported mean age of  $36.9 + 14.6$  years and they also found female preponderance (60.0%) in their study.<sup>15,16</sup> Another study by Seuk JW et al also found a similar age of presentation (42.4 years), however, they found in contrast gender presentation with males in dominance with (72.5%) proportion.<sup>17,18</sup>

Gnjidic Z and colleagues reported mean age of 40.1 years ranging from 19 to 65 years. They also found a similar gender distribution as in our study with (54.0%) female cases in their study.<sup>19,20</sup> Another similar study from Kenya by Githinji KJ et al witnessed female preponderance with (60.0%) proportion in their study.<sup>21</sup> These findings of gender distribution are comparable with our study results where we also found female in majority, however, there is no direct or indirect variation of gender's association with pituitary and sella suprasellar tumors as these can present equally in any segments of population.

In the current study, the computerized perimeter showed a significant improvement of visual field in patients with bitemporal hemianopia after surgery, however, those having complete blindness had little effect of intervention. Moreover, the perimetry of visual acuity showed that (57.5%) patients had immediate improvement and (28.7%) patients improved after 4 weeks as found on follow-up, however, the remaining (13.6%) showed no improvement in visual acuity after surgery. Overall, it was found out that of the 73 cases, (86.4%) improved whereas (13.6%) had no improvement in the status of visual acuity. Comparatively, a local study by Ayub S et al reported that post operatively (85.2%) of their patients had complete or partial improvement in visual acuity.<sup>16</sup> A previous study by Motta et al reported improvement in visual acuity and visual field in 75.0% cases.<sup>22,23</sup> Chuang et al reported that 73% of their patients had improvement in VA and VF.<sup>92</sup> Similarly, Zhang et al witnessed improvement in visual acuity of 88.4% cases and improvement in visual field of 92.7% cases.<sup>24,25</sup> A recent study by Seuk JW and colleagues reported that 88.2%

patients had improvement in the VF and 83.3% patients had improvement in the visual acuity.<sup>26,27</sup> These studies have quite comparable results with the current study findings where we noted that overall 86.4% cases had improvement in VA and VF as measured according to computerized perimetry. This shows high success of excision of sella and suprasellar tumors through craniotomy or other available surgical options.

There is a need to create awareness regarding these tumors and their symptoms so that patients present early and the diagnosis can be made timely and managed accordingly. As many factors like age and duration of tumor can negatively affect the outcome of surgery in tumors of sella supra sellar and adjoining regions, there is a need to prioritize these patients on presentation.

There are many factors can affect visual outcome. These factors include long standing compression of optic pathway, intraoperative complication, pre operative degree of field changes and interference of blood supply of visual pathway. This study evaluates the different changes in the visual field as a predictive value of VF outcome three months after treatment of parachiasmatic tumours compressing the anterior visual pathways. VF was used rather than the VA as VA reflects the function of a small area of the VF, whereas the quantitative VF defect better reflects the effect of compression onto the anterior visual pathways. In addition, the majority of patients have VF defects with retained acuity.<sup>28,29,30</sup>

There are numerous advantages of the current study, this was a very rare topic and very few trials have so far answered questions related to sella and suprasellar tumors. A reasonable sample of patients have been selected in the study period which is not so common. Visual function testing and perimetry have been applied on the patient's pre and post operatively to see improvement in visual acuity and visual field.

There were some limitations of the study as well, the aim was specifically targeting the pre and post operative visual acuity and field testing by perimetry and no long term outcome of other

neurological and neurosurgical parameters was recorded.

## CONCLUSION

Sellar and suprasellar tumors are common; they directly affect the quality of life in terms of visual disturbances and partial or complete blindness. After craniotomy and excision of tumors perimetry showed improvement in the majority of the studied cases. As suggested by earlier investigators, early detection and excision of these tumors bears better results in terms of improvement of visual acuity and visual field.


With rigorous methodology and large scale are recommended, both at national and international level to confirm the findings of current study and compare it with the more recent approaches.

Copyright© 25 Sep, 2017.

## REFERENCES

1. Mancall, Elliott L, Brock DG, eds. **Cranial Fossae Grays Clinical Anatomy. Elsevier Health Sciences.** 2011; p154 ISBN 9781437735802.
2. Shlomo M. **The pituitary. Academic Press.** 2010; p.40.
3. Chahal HS, Stals K, Unterlander M. **AIP mutation in pituitary adenomas in the 18<sup>th</sup> century and today.** New Engl J Med 2011; 364:43-50.
4. Villwock JA, Villwock M, Deshaies E, Goyal P. **Significant increases of pituitary tumors and resections from 1993 to 2011.** Int Forum Allergy Rhinol 2014; 4: 767-70.
5. Kosmorsky GS, Dupps WJ Jr, Drake RL. **Nonuniform pressure generation in the optic chiasm may explain bitemporal hemianopsia.** Ophthalmology 2008; 115:560-5.
6. Suri A, Narang Ks, Sharma BS, Mahapatra AK. **Visual outcome after surgery in patients with suprasellar tumors and preoperative blindness.** J Neurosurg 2008; 108:19-25.
7. Thomas ST. **Finite elements modeling of chiasmal compression.** J Undergraduate Engineering Res 2009; 12:1-30.
8. Gnalingham KK, Bhattacharjee S, Pennington R. **The time course of visual field recovery following transphenoidal surgery for pituitary adenomas: predictive factors for a good outcome.** J Neurol Neurosurg Psychiatry 2005; 76:415-9.

9. MacDonald I, Powell MP. **Visual manifestations of pituitary tumours**, in : **Management of Pituitary Tumours the Clinicians Practical Guide – Second Edition** Eds MP Powell, SL Lightman, ER Laws Jr. Humana Press 2003.
10. Osborn A, Blaser S, Salzman K. **Sella and Pituitary. In: Diagnostic Imaging: Brain.** Salt Lake City, UT: Amirsys, 2004.
11. William R. **Contemporary Orthodontics, 4th Edition.** C.V. Mosby, 2006. ISBN: 978-0-323-04046-4.
12. Shimono T, Hatabu H, Kasagi K, et al. **Rapid progression of pituitary hyperplasia in humans with primary hypothyroidism: Demonstration with MR imaging.** *Radiology.* 1999; 213(2):383-388.
13. Connor SE, Penney CC. **MRI in the differential diagnosis of a sellar mass.** *Clin Radiol.* 2003; 58(1):20-31.
14. FitzPatrick MF, Tartaglino LM, Hollander MD, et al. **Imaging of sellar and parasellar pathology.** *Radiol Clin North Am.* 1999; 37(1):101-121.
15. Friedman TC, Zuckerbraun E, Lee ML, et al. **Dynamic pituitary MRI has high sensitivity and specificity for the diagnosis of mild Cushing's syndrome and should be part of the initial workup.** *Horm Metab Res.* 2007; 39(6):451-456.
16. Simonetta AB. **Imaging of suprasellar and parasellar tumors.** *Neuroimaging Clin N Am.* 1999; 9(4):717-732.
17. Knosp E, Steiner E, Kitz K, Matula C. **Pituitary adenomas with invasion of the cavernous space: A magnetic resonance imaging classification compared with surgical findings.** *Neurosurgery.* 1993; 33:610-618.
18. Sartoretti-Schefer S, Wichmann W, Aguzzi A, Valavanis A. **MR differentiation of adamantinousand squamous-papillary craniopharyngiomas.** *AJNR Am J Neuroradiol.* 1997; 18:77-87.
19. Grossman RI, Yousem DM. **Neuroradiology: The Requisites.** 2nd ed. St. Louis, MO: Mosby; 2003.
20. Colao A, Loche S, Cappa M, Di Sarno A, Landi ML, Sarnacchiaro F, et al. **Prolactinomas in children and adolescents. Clinical presentation and long-term follow-up.** *J Clin Endocrinol Metab.* 1998; 83:2777-80.
21. Jagannathan J, Dumont AS, Jane JA, Jr, Laws ER., Jr **Pediatric sellar tumors: Diagnostic procedures and management.** *Neurosurg Focus.* 2005; 18:1-5.
22. Bunin GR, Surawicz TS, Witman PA, Preston-Martin S, Davis F, Bruner JM. **The descriptive epidemiology of craniopharyngioma.** *J Neurosurg.* 1998; 89:547-51.
23. Lafferty AR, Chrousos GP. **Pituitary tumors in children and adolescents.** *J Clin Endocrinol Metab.* 1999; 84:4317-23.
24. Combs SE, Schulz-Ertner D, Moschos D, Thilmann C, Huber PE, Debus J. **Fractionated stereotactic radiotherapy of optic pathway gliomas: Tolerance and long-term outcome.** *Int J Radiat Oncol Biol Phys.* 2005; 62:814-9.
25. Czyzyk E, Józwiak S, Roszkowski M, Schwartz RA. **Optic pathway gliomas in children with and without neurofibromatosis 1.** *J Child Neurol.* 2003; 18:471-8.
26. Allen JC. **Initial management of children with hypothalamic and thalamic tumors and the modifying role of neurofibromatosis-1.** *Pediatr Neurosurg.* 2000; 32:154-62.
27. Medlock MD, Madsen JR, Barnes PD, Anthony DS, Cohen LE, Scott RM. **Optic chiasm astrocytomas of childhood. 1. Long-term follow-up.** *Pediatr Neurosurg.* 1997; 27:121-8.
28. Dutton JJ. **Gliomas of the anterior visual pathway.** *Surv Ophthalmol.* 1994; 38:427-52.
29. Khafaga Y, Hassounah M, Kandil A, Kanaan I, Allam A, El Hussein G, et al. **Optic gliomas: A retrospective analysis of 50 cases.** *Int J Radiat Oncol Biol Phys.*
30. Darendeliler F, Karagiannis G, Wilton P, Ranke MB, Albertsson-Wikland K, Anthony Price D, et al. **Recurrence of brain tumours in patients treated with growth hormone: analysis of KIGS (Pfizer International Growth Database).** *Acta Paediatr.* 2006; 95(10):1284-90.
31. Karavitaki N, Warner JT, Marland A, Shine B, Ryan F, Arnold J, et al. **GH replacement does not increase the risk of recurrence in patients with craniopharyngioma.** *Clin Endocrinol (Oxf).* 2006; 64(5):556-60.



*“Even if you’re on the right track,  
you’ll get run over if you just sit there.”*

**Will Rogers**

#### **AUTHORSHIP AND CONTRIBUTION DECLARATION**

<b>Sr. #</b>	<b>Author-s Full Name</b>	<b>Contribution to the paper</b>	<b>Author=s Signature</b>
1	Muhammad Khalid	Writing up, Manuscript and surgeon	
2	Mehwish Aslam	Helping in writing up	
3	Umer Farooq Raina	Team member in writing up and data collection	
4	Khaleeq UZ Zaman	Prof reading, Operations Surgeon	