



1. M.B.B.S., F.C.P.S., Ph.D. (Scholar),
Professor/Director,
Directorate of Medical Sciences,
Government College University,
Faisalabad, Pakistan.
2. M.Phil., Ph.D. (Scholar), Lecturer,
College of Allied Health Professionals,
Directorate of Medical Sciences,
Government College University,
Faisalabad, Pakistan.
3. M.B.B.S., F.C.P.S., Senior Registrar,
Department of Obstetrics and
Gynecology,
Punjab Medical College, Allied Hospital,
Faisalabad, Pakistan.
4. M.Phil., Lecturer,
College of Allied Health Professionals,
Directorate of Medical Sciences,
Government College University,
Faisalabad, Pakistan.
5. B.Pharm, M.Phil., Ph.D.,
Assistant Professor,
Department of Eastern Medicine and
Surgery, Directorate of Medical Sciences,
Government College University,
Faisalabad, Pakistan.
6. B.S. Orthotics and Prosthetics, Lecturer,
Directorate of Medical Sciences,
Government College University,
Faisalabad, Pakistan.
7. Lecturer
8. Women Medical Officer

Correspondence Address:

Prof. Dr. Abid Rashid
Professor/Director,
Directorate of Medical Sciences,
Government College University,
Faisalabad, Pakistan.
drabidrashid37@gmail.com

Article received on:

28/01/2017

Accepted for publication:

05/03/2017

Received after proof reading:

06/04/2017

INTRODUCTION

Breast cancer is infrequent in males that accounts for nearly 1% of malignant breast neoplasm with an estimated incidence of 1 out of 100000 males.¹⁻³ There are more than 3.1million breast cancer survivors in the U.S.⁴ In 2016, around 2600 new cases were detected in the United States that resulted in 440 deaths. Invasive ductal carcinoma is the most predominant among the various histological types of breast cancer among males with varying incidence between 65 to 95%.⁵ The frequency of male breast cancer increases with age with peak incidence around 71 years. On the other hand, breast cancer in female have shown a bimodal distribution with peak incidence at around 52 and 72 years.⁶ Although the breast cancer is rare in younger males, it is rare, various studies reported the cases in earlier years of life.⁷

MALE BREAST CANCER; INVASIVE DUCTAL CELL CARCINOMA INFESTED WITH MYIASIS. A CASE REPORT

**Dr. Abid Rashid¹, Mohsin Khurshid², Dr. Umbreen Naz³, Muhammad Naeem⁴,
Muhammad Mudassar Ashraf⁵, Muhammad Saqib⁶, Muhammad Ans⁷, Ayesha Tufail⁸**

ABSTRACT... Breast carcinomas are an uncommon neoplastic condition in men, which accounts for only 1% of all breast cancers, and not more than 1% of all malignancies in men. A 55 years old man presented with a ulcerated mass in the left breast with a history of pain, discharge and fever. On examination, there was an ulcerating growth above the left nipple with numerous maggots. The fine needle aspiration cytology confirmed the ductal cell carcinoma which was further confirmed by ulcer edge biopsy.

Key words: Neoplasia; Ductal cell carcinoma; Breast cancer.

Article Citation: Rashid A, Khurshid M, naz U, Naeem M, Ashraf MM, Saqib M, Ans M, Tufail A. Male breast; invasive ductal cell carcinoma infested with myiasis; a case report. Professional Med J 2017;24(4):633-636. DOI: 10.17957/TPMJ/17.3854

This study examined a case of 55 years old male with invasive ductal cell carcinoma having symptoms of pain, nipple discharge with maggots coming from the wounds and steps regarding its surgical management.

CASE REPORT

A 55 years old male was referred to a private hospital of Faisalabad in August 2016 with the history of pain, fever and discharge from the wounds for last six months. The previous medical and family history did not appear to contribute to the present illness. The patient denied the use of drugs or anabolic steroids, and alcohol, however he was a smoker with a frequency of 10 cigarettes per day. The patient informed about a normal sexual life with six children.

The physical examination revealed the ulcerative growth in left breast with the presence of maggots in the lesion as shown in Figure-1. On examination the axillary lymphs were impalpable. The fine needle aspiration cytology revealed the malignant transformation in the cells. The modified radical mastectomy was done and post-operative recovery was excellent with no incidence of wound infection unexpectedly (Figure-2). Later on, the histological examination showed complete effacement of normal architecture replaced by anaplastic cells arranged in glands, cords and nests of sheets cells. The anaplastic cells comprised of large hyperchromatic nuclei with prominent nucleoli and many mitotic divisions. The cytoplasm was abundant and eosinophilic. The stroma was abundant, dense and fibrous with diffuse infiltration of neutrophils, lymphocytes and plasma cells.

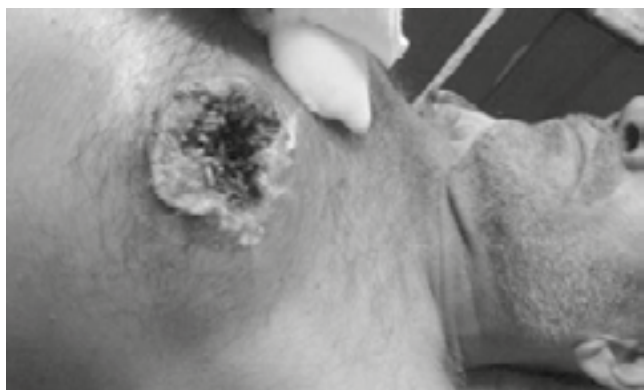

Figure-1. The chronic malignant wound developed from the extension of invasive cancer into the skin, producing an ulcerating necrotic lesion with extensive myiasis.

DISCUSSION

The presentation of invasive ductal carcinoma in males has unusual features and a late diagnosis. In males, around 42% of breast cancer cases are diagnosed during stage III or IV perhaps because males are less concerned towards medical care for breast masses as compared with females. Furthermore, the tumor is mostly close to the skin in men therefore the possibility of penetration into the dermis is increased.⁶

The therapeutic approaches for breast cancer in male are not based on the data obtained from clinical trials in men and the majority of

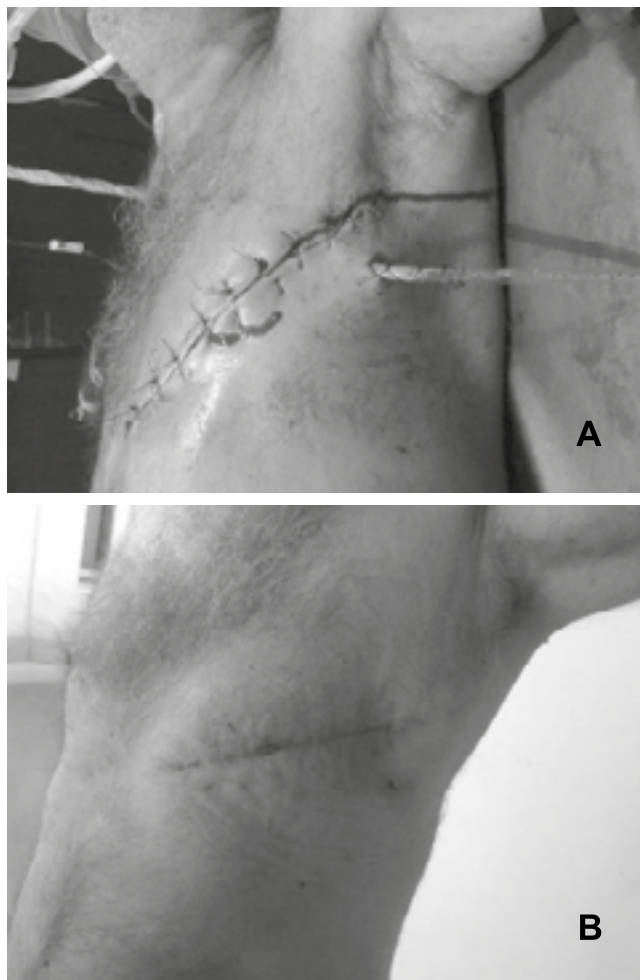


Figure-2. Modified radical mastectomy of the left breast in 55 years old male patient. (A) Just after surgery. (B) 15 days after surgery.

recommended treatment are concluded from the data of female patients.³ Aromatase inhibitor would be preferable to tamoxifen.⁸ The prognosis is poor in male patients of breast cancer particularly in the younger age, as the majority of cases of breast enlargements in young age are misdiagnosed as gynecomastia that may result in excessive delay in the medical or surgical management.⁹ The median age of diagnosis in males with breast cancer varies with a few reports in young male patients.¹⁰ The two different studies described the breast cancer cases in 30 and 32 year old male whereas another study described the case of ductal carcinoma and gynecomastia in a 16 year old male.³

The conditions frequently associated with breast cancer in males includes cirrhosis, obesity,

testicular trauma and the use of radiation therapy and exogenous estrogen.¹¹⁻¹² In the present study, the patient have 55 years of age with no family history of cancer and hormonal therapy that could explain the higher risk for the development of breast cancer. The gynecomastia has been associated with increased risk of breast cancer as reported in 6-38% of the positive cases in men³; however it was not apparent in the present study.

Male breast cancers less frequently harbor somatic genetic alterations typical of ER-positive/HER2-negative female breast cancers, such as PIK3CA and TP53 mutations and losses of 16q, suggesting that at least a subset of male breast cancers are driven by a distinct repertoire of somatic changes. Given the genomic differences, caution may be needed in the application of biologic and therapeutic findings from studies of female breast cancers to male breast cancers.¹³ It is essential to ponder the family history of breast malignancies that might be a useful indicator of increased risk of breast cancer. Furthermore, certain genetic disorders diseases such as Cowden's disease and Klinefelter's syndrome have been associated with male breast cancer in males.¹⁴ Currently, the studies do not supports the notion that all men having breast cancer needs breast magnetic resonance imaging (MRI), however the suspicious lesions in the contra lateral breast must be scanned through MRI. Further, the survivors among the male breast cancer cases have an increased risk of developing a second primary malignancy. The men are at a higher risk of contra lateral breast cancer as compared to women.³ The studies mentioned a 30 fold higher risk of contra lateral breast cancer in male with previous history of breast cancer as compared to the females with two to four fold risk.¹⁵ The role of Estrogen and progesterone receptors have been proposed in breast malignancies in men, and are found in 90% and 81% of males with breast cancer respectively.¹⁶

The earlier diagnosis of breast cancer in males is associated with the successful treatment comparable to the female breast cancer cases. The males have significantly less mammary

parenchyma than females, therefore the diagnosis can be made by a combination of investigations including clinical examination, mammography examination, cytology, and biopsies. The most definite diagnosis is usually made by histological picture of core needle biopsy.¹⁷

The therapeutic interventions of breast cancer in males should be mainly based on the size of tumor, presence of receptors for estrogen and progesterone, and the occurrence of other maladies. As the most cases of breast cancer in men have generally an older age therefore other co-morbidities are also present. The appropriate surgical treatment is modified radical mastectomy owing to the small percentage of mammary parenchyma in males, therefore the same was adopted in the present case.

CONCLUSION

The current case reported a rare type of cancer; the invasive ductal carcinoma, that have a peak prevalence around the sixth and seventh decade of life. The genetic factors and hormonal imbalances are the important risk factors for breast cancer in males. Even though the family history of breast cancer, genetic disorders and hormonal imbalances were absent, the invasive ductal cell carcinoma developed in the male patient of the present study at a relatively younger age than the peak incidence reported by various studies. The patient currently is receiving chemo-radiation in a public sector tertiary care hospital of Faisalabad.








Copyright© 05 Mar, 2017.

REFERENCES

1. Valentina S, Daniel B, Anna MM, et al. **Male breast cancer in BRCA1 and BRCA2 mutation carriers: pathology data from the Consortium of Investigators of Modifiers of BRCA1/2.** *Breast Ca Res* 2016; 18:15
2. Coroneos CJ, Hamm C. **Ductal carcinoma in situ in a 25-year-old man presenting with apparent unilateral gynecomastia.** *Curr Oncol* 2010; 17(4): 133-7.
3. Madeira M, Mattar A, Passos RJ, et al. **A case report of male breast cancer in a very young patient: what is changing?** *World J Surg Oncol* 2011; 9: 16. doi: 10.1186/1477-7819-9-16.

4. Susan GK. **Breast Cancer Fact Sheet**. 2015. ekuhn@komen.org.
5. American Cancer Society. **Cancer facts and figures 2016**. Atlanta, Ga: American Cancer Society, 2016.
6. Anderson WF, Althuis MD, Brinton LA, et al. **Is male breast cancer similar or different than female breast cancer?** Breast Cancer Res Treat 2004; 83(1): 77-86. doi: 10.1023/B:BREA.0000010701.08825.2d.
7. Hill TD, Khamis HJ, Tyczynski JE, et al. **Comparison of male and female breast cancer incidence trends, tumor characteristics, and survival**. Ann Epidemiol 2005; 15(10): 773-80. doi: 10.1016/j.annepidem.2005.01.001.
8. Bogler O. **Advancing care of male breast cancer through clinical trials**. American Society of Breast Surgeons Annual Meeting. Presented April 15, 2016.
9. Giordano SH. **A review of the diagnosis and management of male breast cancer**. Oncologist 2005; 10(7): 471-479. doi: 10.1634/theoncologist.10-7-471.
10. Cutuli B. **Strategies in treating male breast cancer**. Expert Opin Pharmacother 2007; 8(2): 193-202. doi: 10.1517/14656566.8.2.193.
11. Ganly I, Taylor EW. **Breast cancer in a trans-sexual man receiving hormone replacement therapy**. Br J Surg 2005; 82(3): 341.
12. Misra SP, Misra V, Dwivedi M. **Cancer of the breast in a male cirrhotic: is there an association between the two?** Am J Gastroenterol 1996; 91(2): 380-2.
13. Piscuoglio S, Ng CK, Murray MP, et al. **The genomic landscape of male breast cancers**. Clin Cancer Res 2016; 22(16): 4045-56.
14. Fentiman IS, Fourquet A, Hortobagyi GN. **Male breast cancer**. Lancet 2006; 367(9510): 595-604. doi: 10.1016/S0140-6736(06)68226-3.
15. Auvinen A, Curtis RE, Ron E. **Risk of subsequent cancer following breast cancer in men**. J Natl Cancer Inst 2002; 94(17): 1330-2.
16. Giordano SH, Cohen DS, Buzdar AU, et al. **Breast carcinoma in men: a population-based study**. Cancer 2004; 101(1): 51-7. doi: 10.1002/cncr.20312.
17. Jemal A, Siegel R, Ward E, et al. **Cancer statistics, 2009**. CA Cancer J Clin 2009; 59(4): 225-49. doi: 10.3322/caac.20006.

AUTHORSHIP AND CONTRIBUTION DECLARATION

Sr. #	Author-s Full Name	Contribution to the paper	Author=s Signature
1	Dr. Abid Rashid	Research work, Mainly performed the surgical procedure, Approved final copy to be sent for publication	
2	Mohsin Khurshid	Collected and organized the data	
3	Dr. Umbreen Naz	Assisted in surgery	
4	Muhammad Naeem	Write up of case report	
5	M. Mudassar Ashraf	Reviewed the write up, updated it and made it finalized	
6	Muhammad Saqib	Analyzed data and images of surgery	
7	Muhammad Ans	Data collection regarding its publication and read final copy	
8	Ayesha Tufail	Assisted in surgery	